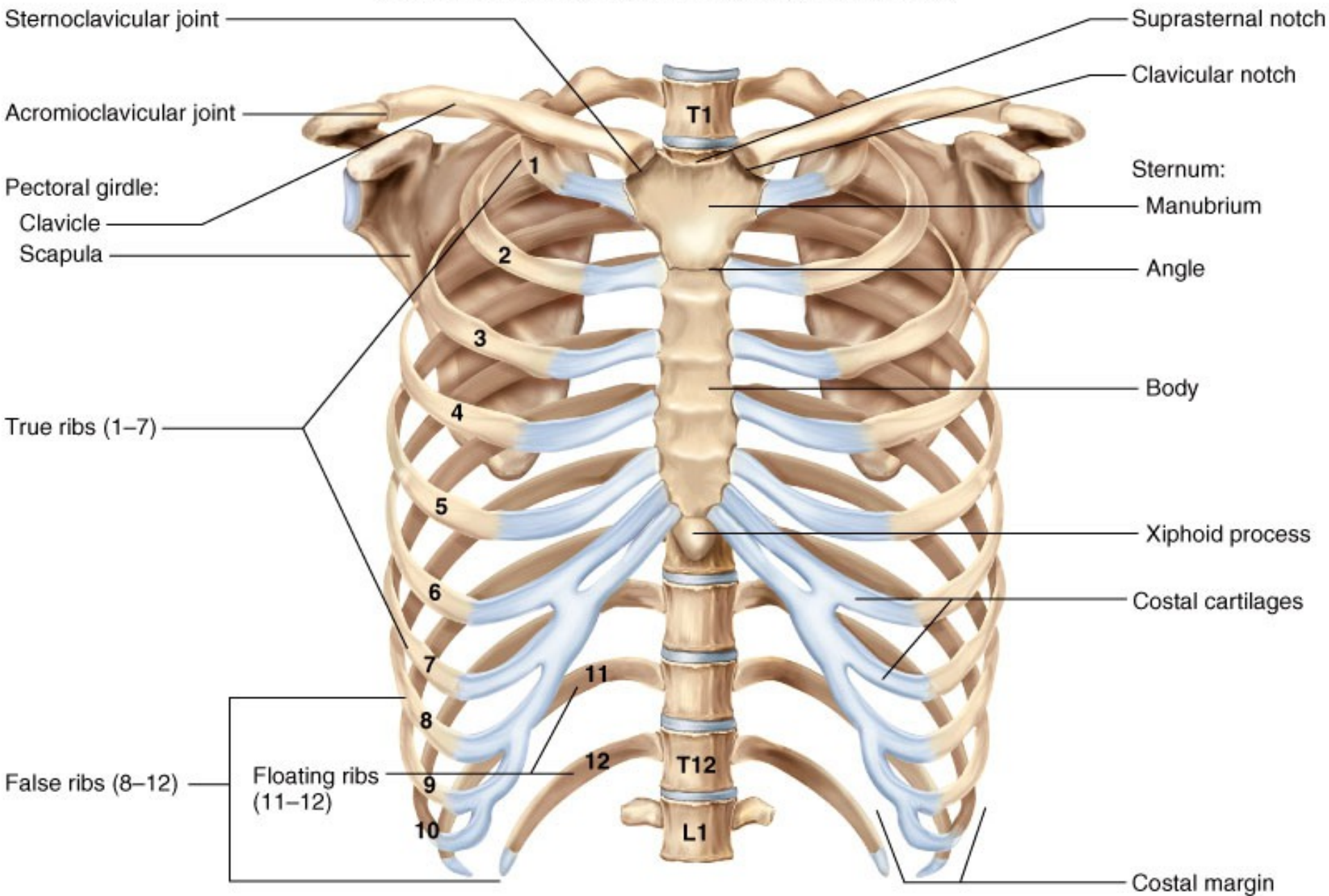
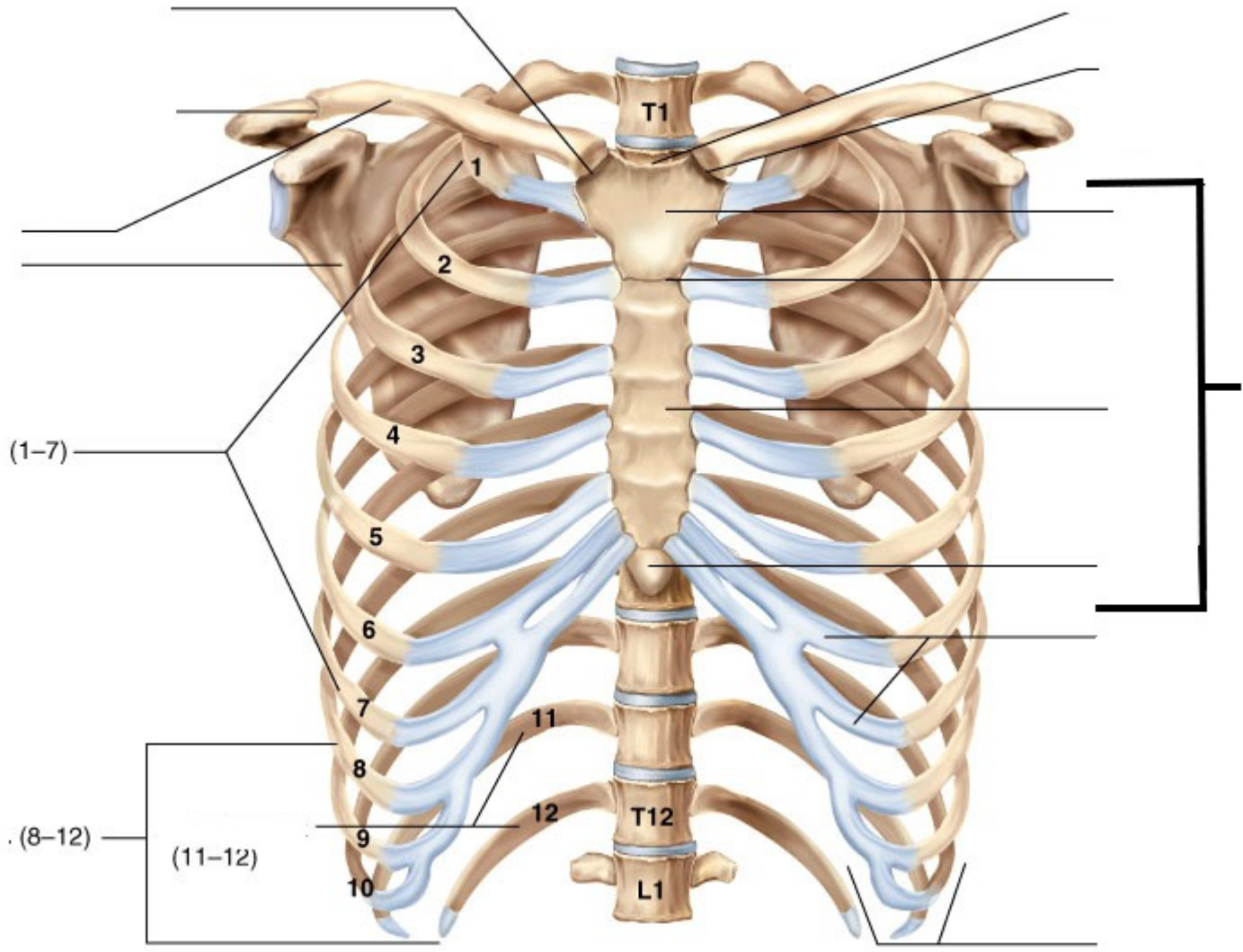


Thorax & Hyoid





Clavicle

Copyright © The McGraw-Hill Companies, Inc. Permission required for reproduction or display.



(a) Superior view



(b) Inferior view

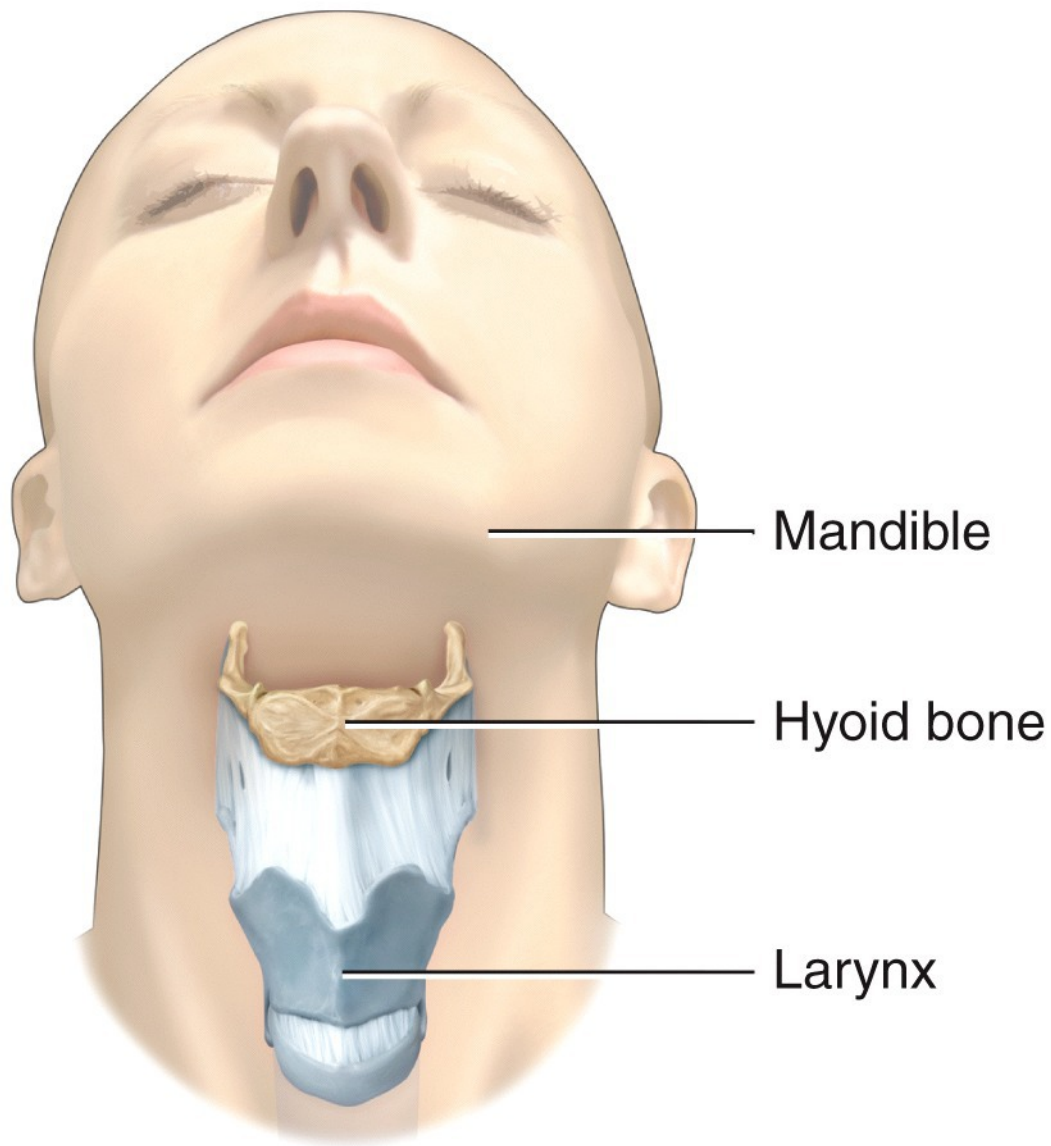
- S-shaped bone, flattened dorsoventrally
- Inferior - marked by muscle and ligament
- Sternal end rounded -- acromial end flattened



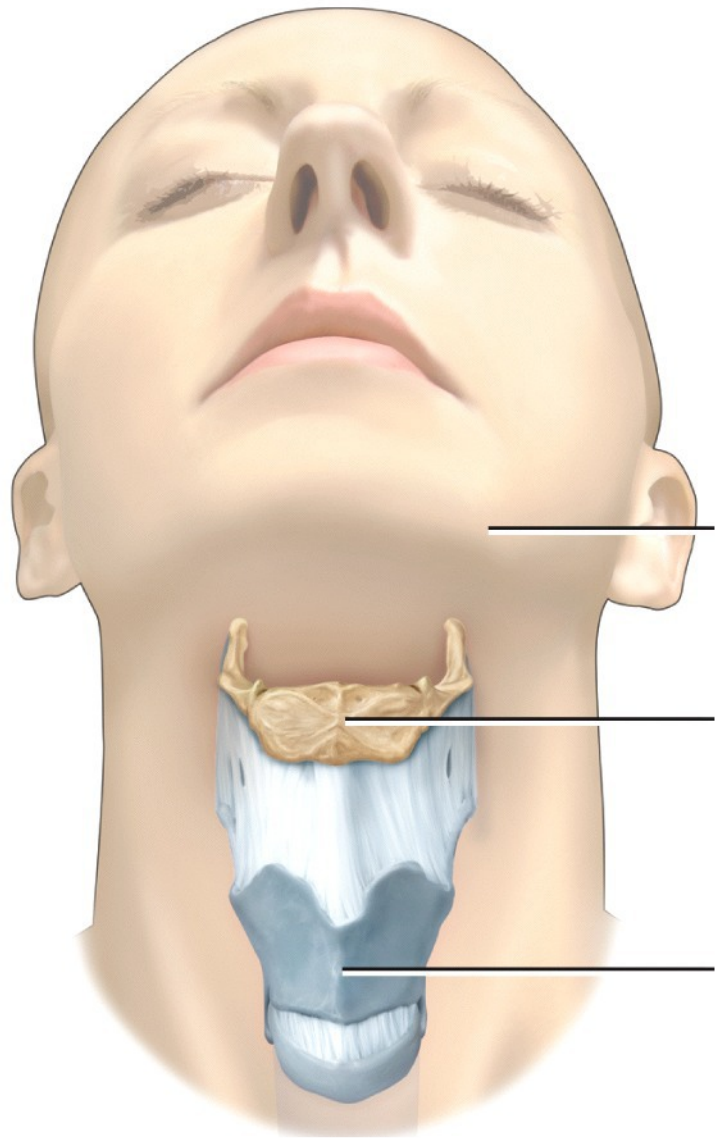
(a) Superior view

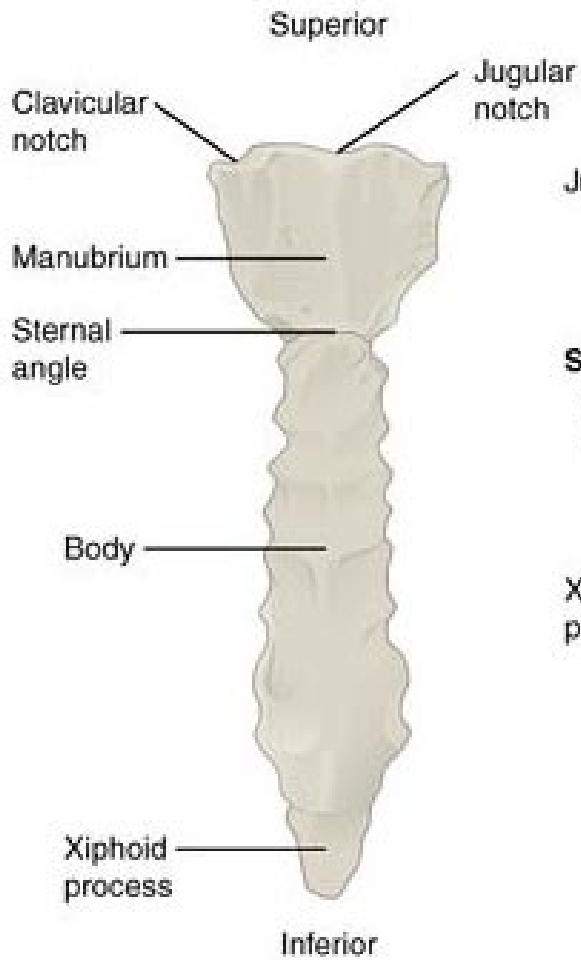


(b) Inferior view

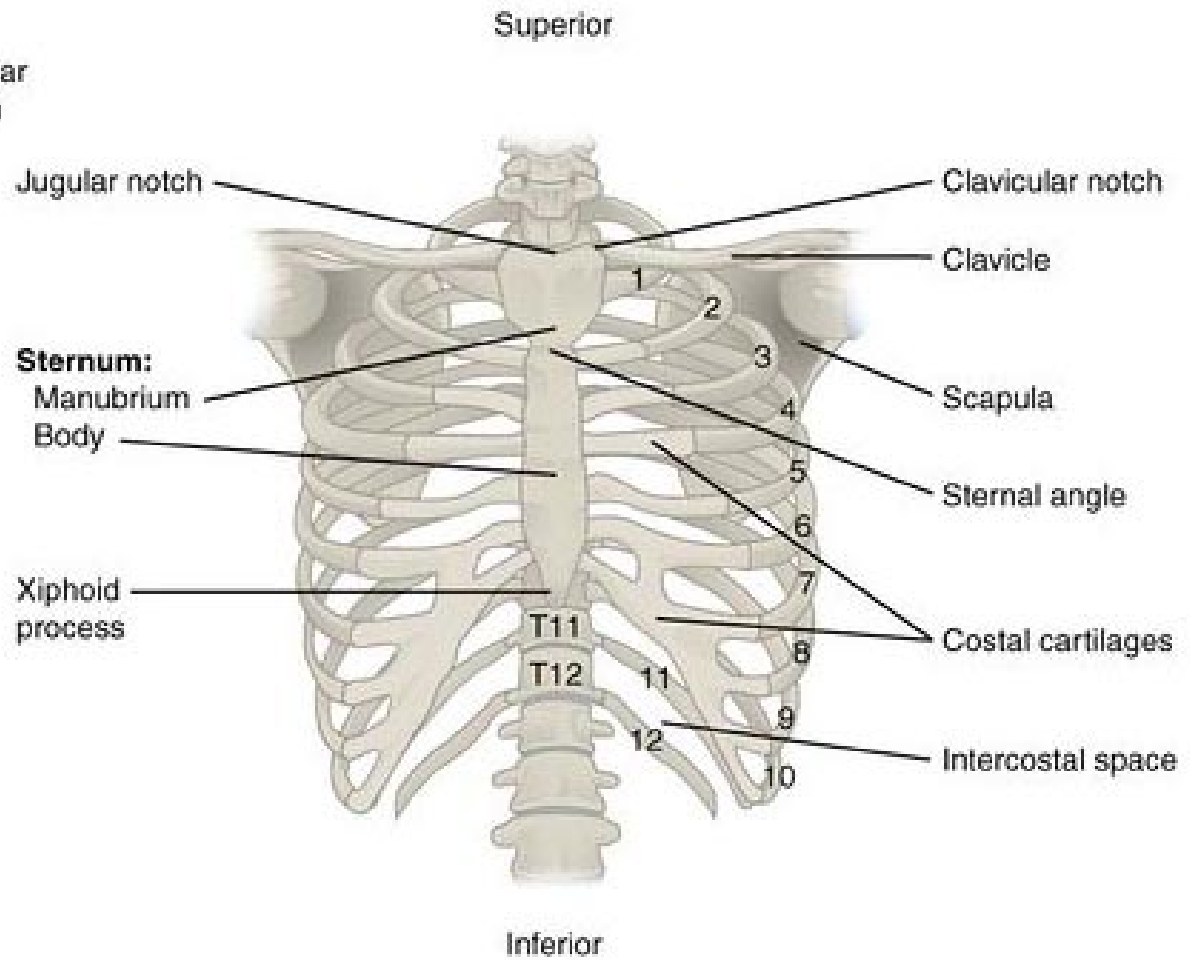


(a) Position of hyoid bone

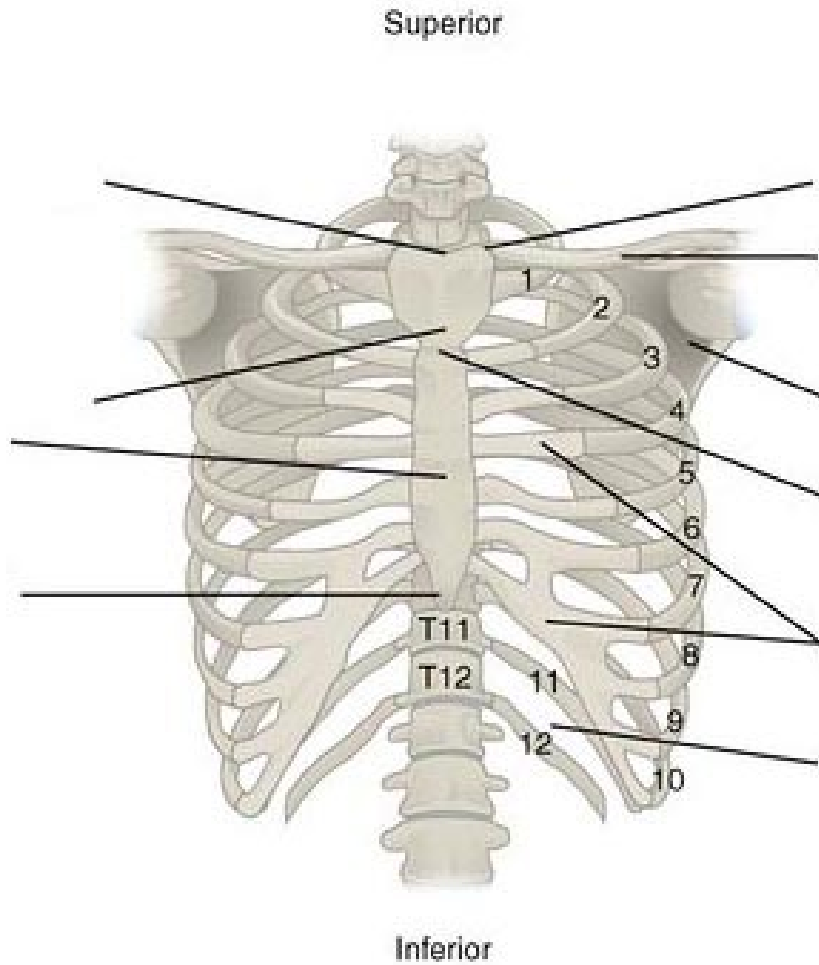
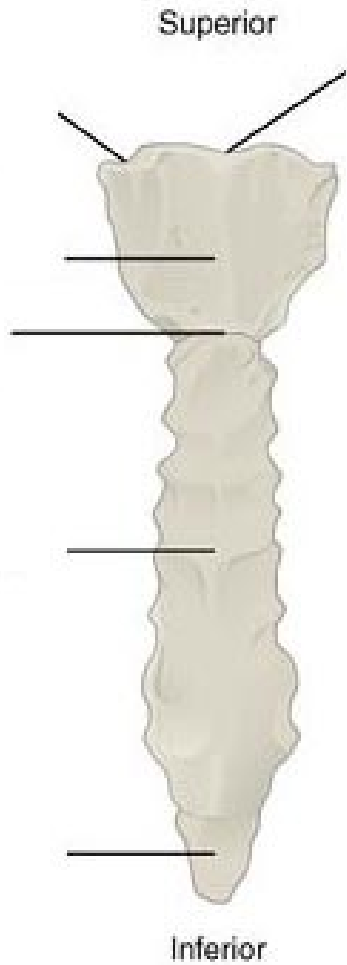




(a) Anterior view of sternum



(b) Anterior view of skeleton of thorax



(b) Anterior view of skeleton of thorax