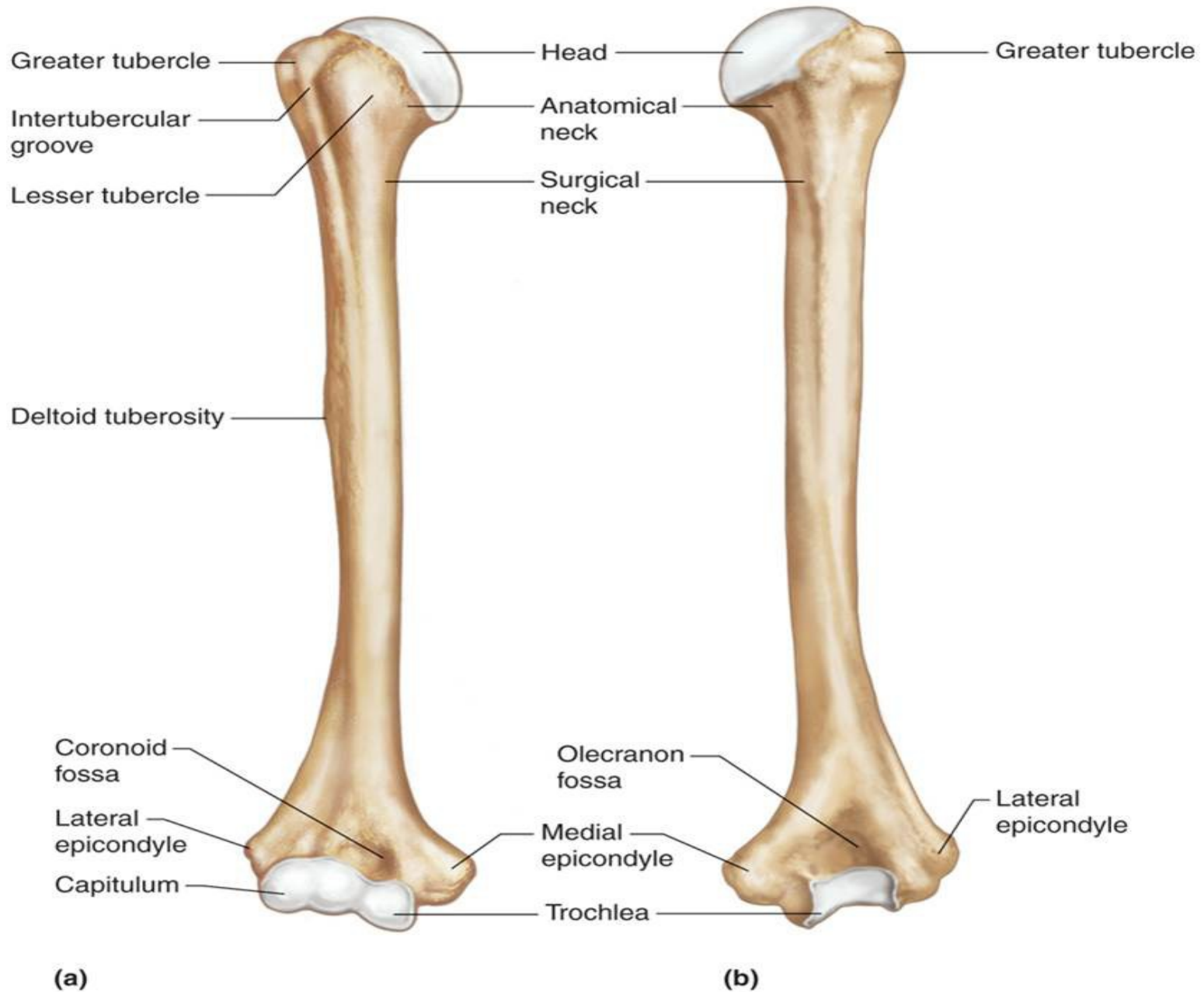
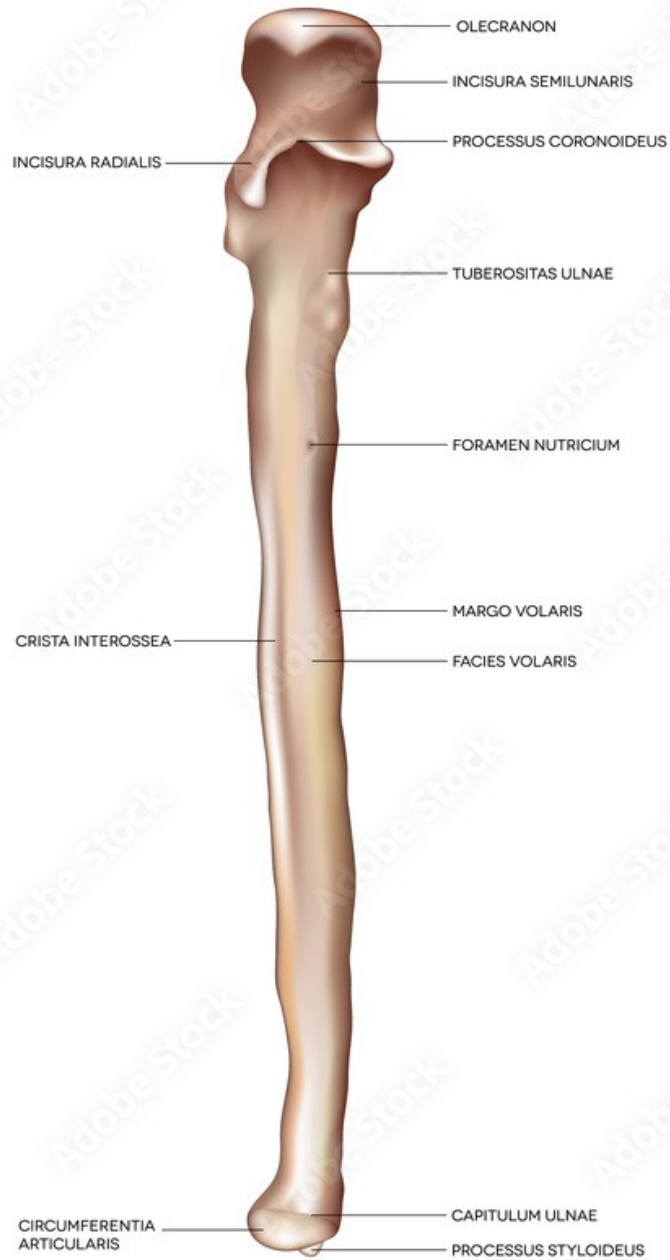

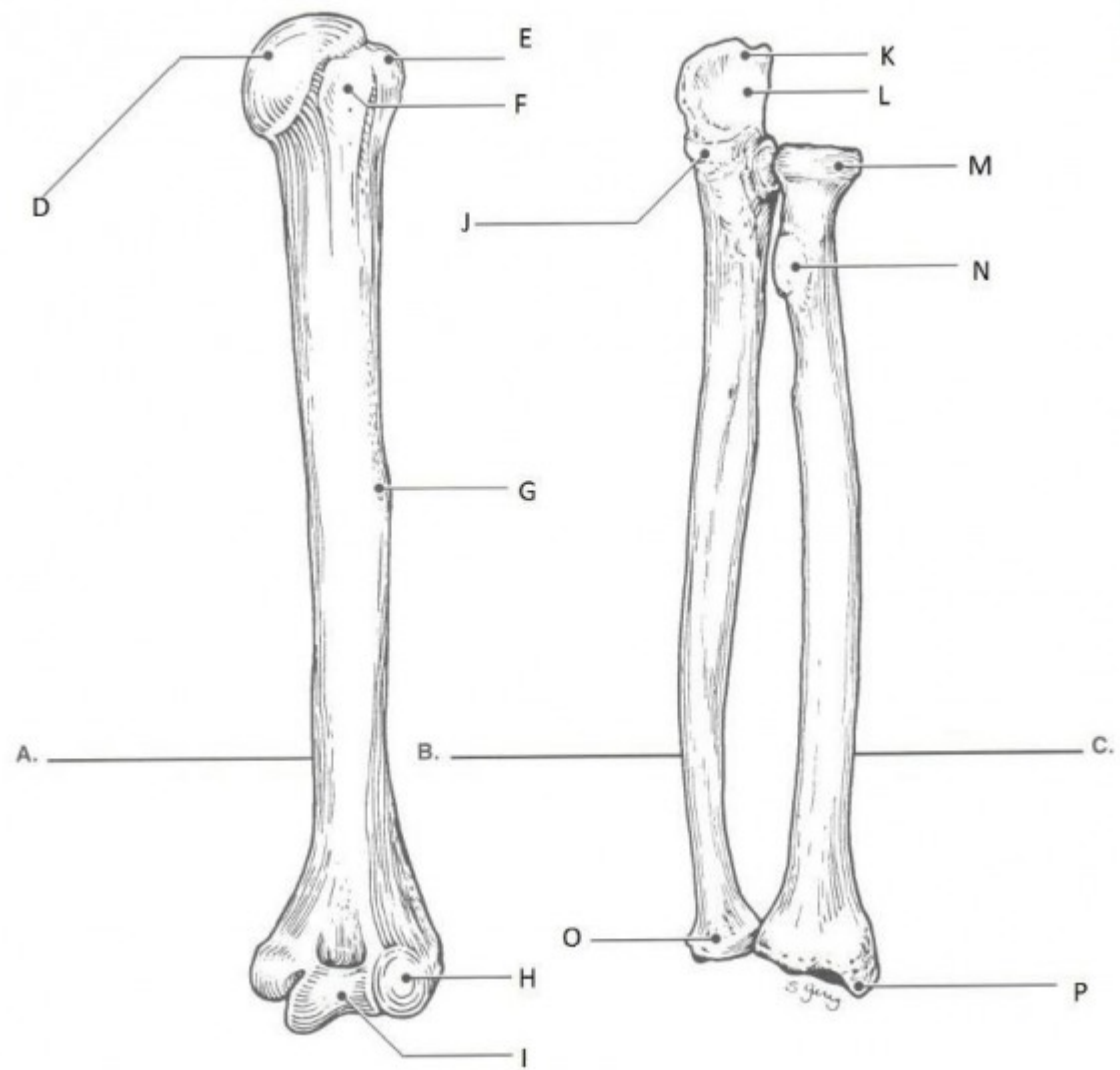
# Upper Extremity Bones and Markings

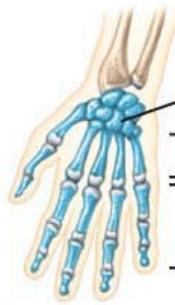
Copyright © The McGraw-Hill Companies, Inc. Permission required for reproduction or display.



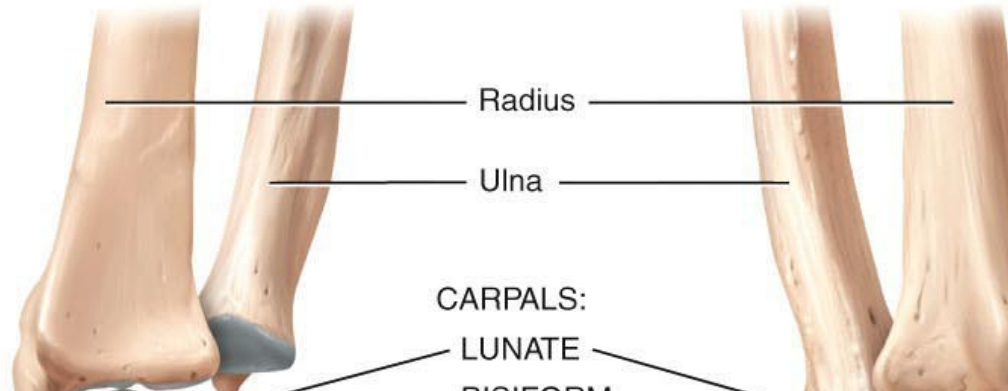
# RIGHT ULNA







Carpals  
 Metacarpals  
 Phalanges



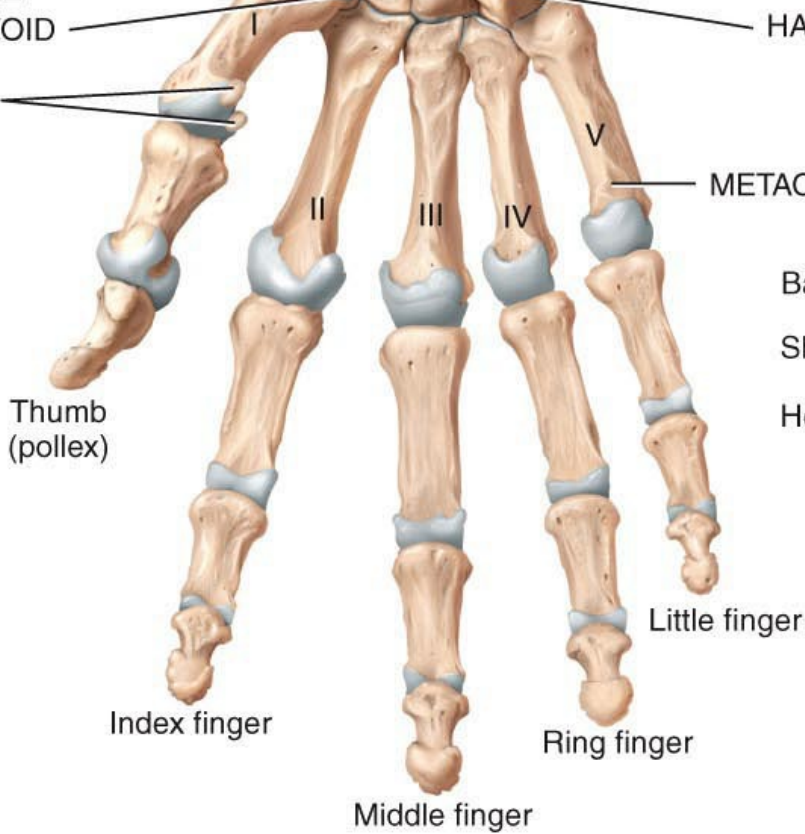
Radius  
 Ulna

CARPALS:  
 SCAPHOID  
 TRAPEZIUM  
 CAPITATE  
 TRAPEZOID

CARPALS:  
 LUNATE  
 PISIFORM  
 TRIQUETRUM  
 HAMATE

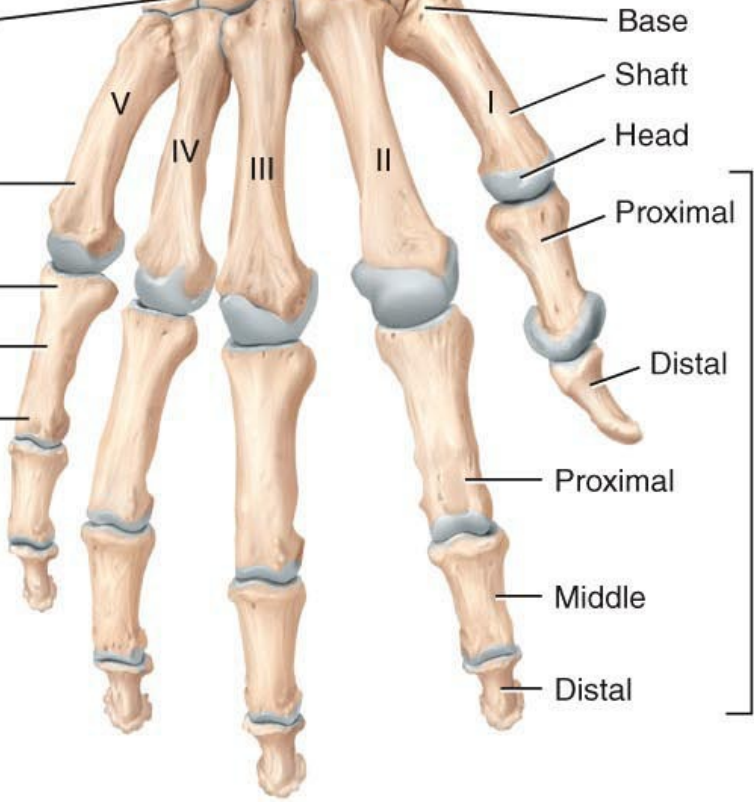
CARPALS:  
 SCAPHOID  
 CAPITATE  
 TRAPEZIUM  
 TRAPEZOID

Sesamoid bones



Thumb (pollex)  
 Index finger  
 Middle finger  
 Ring finger  
 Little finger

METACARPALS  
 Base  
 Shaft  
 Head

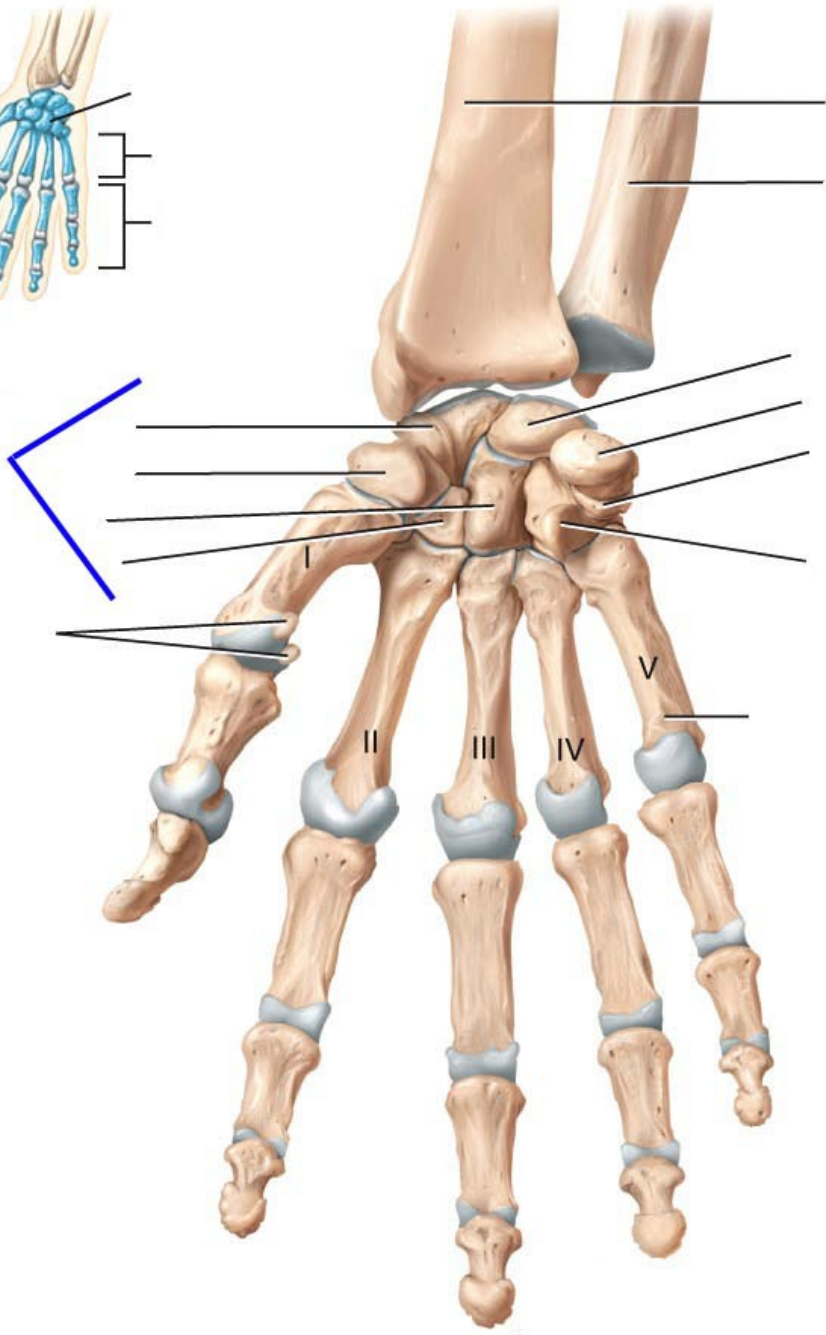
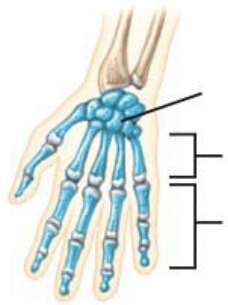


V  
 IV  
 III  
 II  
 I  
 Base  
 Shaft  
 Head  
 Proximal  
 Distal  
 Proximal  
 Middle  
 Distal

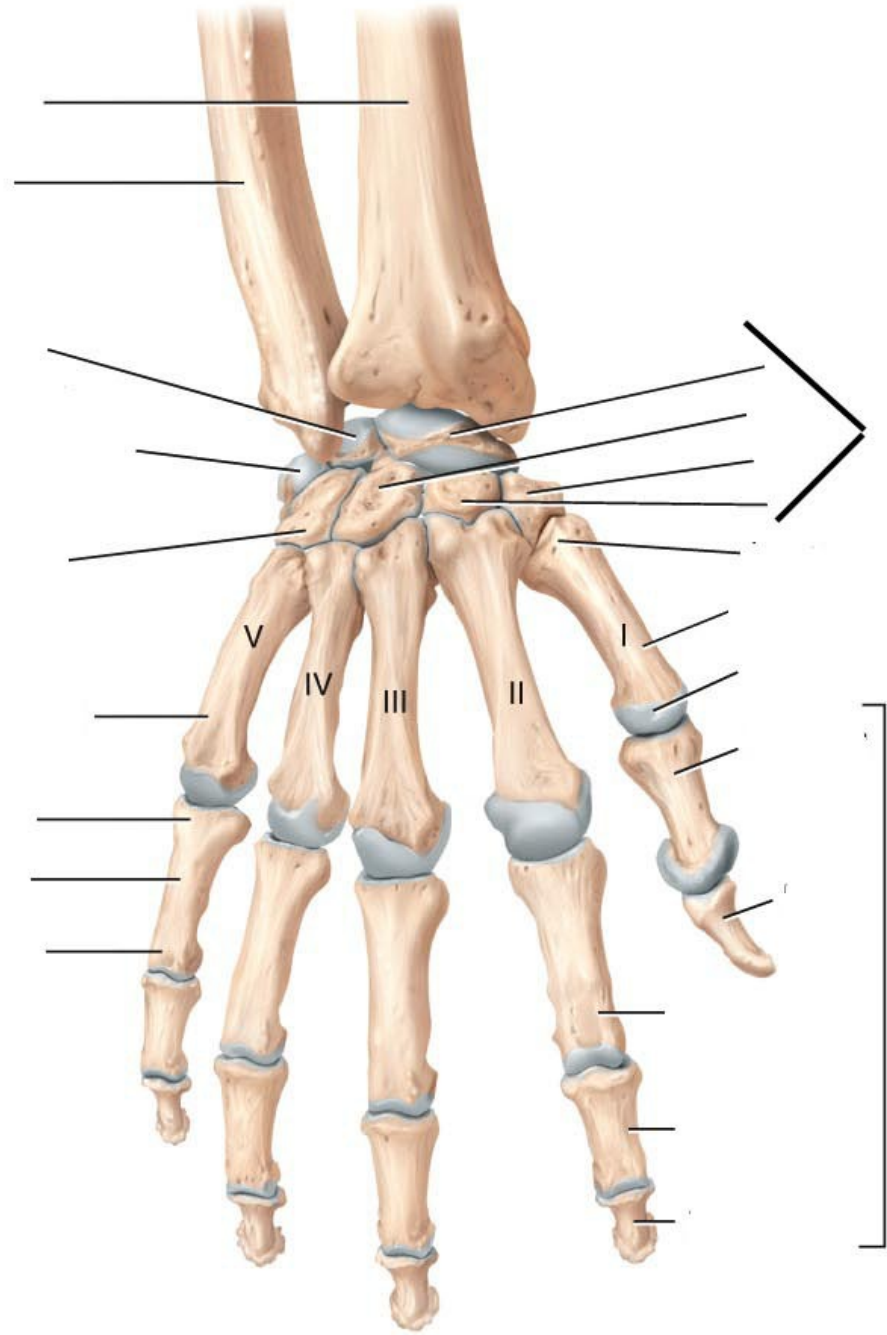
PHALANGES

(a) Anterior view

(b) Posterior view



(a) Anterior view



(b) Posterior view

# Right Scapula Bone

