Chapter 10.6

Smooth & Cardiac Muscles

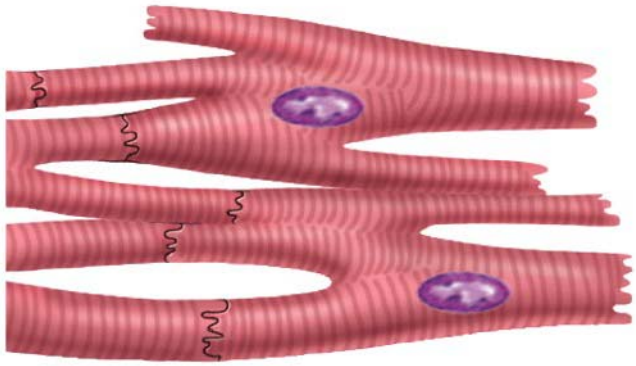

Smooth Muscle

- Some smooth muscles lack nerve supply
- Other smooth muscle cells receive autonomic fibers
  - Note: not somatic motor fibers as in skeletal muscle
- Capable of mitosis and hyperplasia
- Injured smooth muscle regenerates well

Smooth Muscle

- composed of myocytes that have a **fusiform shape**
- one nucleus, located near the middle of the cell
- **no visible striations**
  - reason for the name 'smooth muscle'
  - thick and thin filaments are present, but not aligned with each other
- z discs are absent and replaced by **dense bodies**
  - well ordered array of protein masses in cytoplasm
  - protein plaques on the inner face of the plasma membrane
- cytoplasm contains extensive cytoskeleton of intermediate filament
  - attach to the membrane plaques and dense bodies
  - provide mechanical linkages between the thin myofilaments and the plasma membrane
- sarcoplasmic reticulum is scanty and there are no T tubules
- Ca^{2+} needed for muscle contraction comes from the ECF by way of Ca^{2+} channels in the sarcolemma

Stimulation of Smooth Muscle

- smooth muscle is **involuntary**

- can may contract without nervous stimulation
  - can contract in response to chemical stimuli
    - hormones, carbon dioxide, low pH, and oxygen deficiency
    - in response to stretch
    - single unit smooth muscle in stomach and intestines has **pacemaker cells** that set off waves of contraction throughout the entire layer of muscle

- most smooth muscle is innervated by **autonomic nerve fibers**
  - can trigger and modify contractions
  - stimulate smooth muscle with either acetylcholine or norepinephrine
  - can have <u>contrasting effects</u>
    - relax the smooth muscle of arteries
    - contract smooth muscles of the bronchioles

2 Types of Smooth Muscle – 1 of 3

- **multiunit smooth muscle**
  - occurs in some of the largest arteries and pulmonary air passages, in piloerector muscles of hair follicle, and in the iris of the eye
  - ANS (automomic nervous system) innervation similar to skeletal muscle
    - terminal branches of a nerve fiber synapse with individual myocytes and form a motor unit
    - each motor unit contracts independently of the others

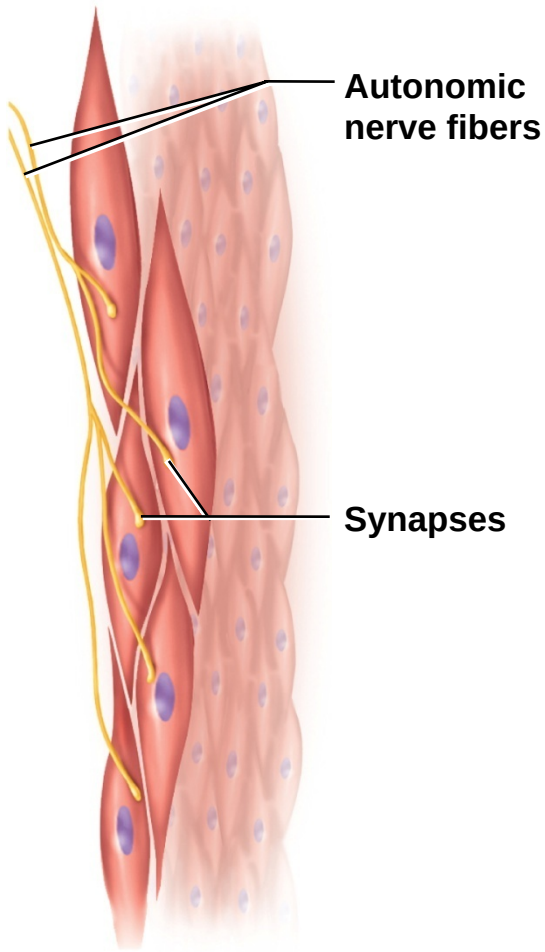

(a) Multiunit smooth muscle

2 Types of Smooth Muscle – 2 of 3

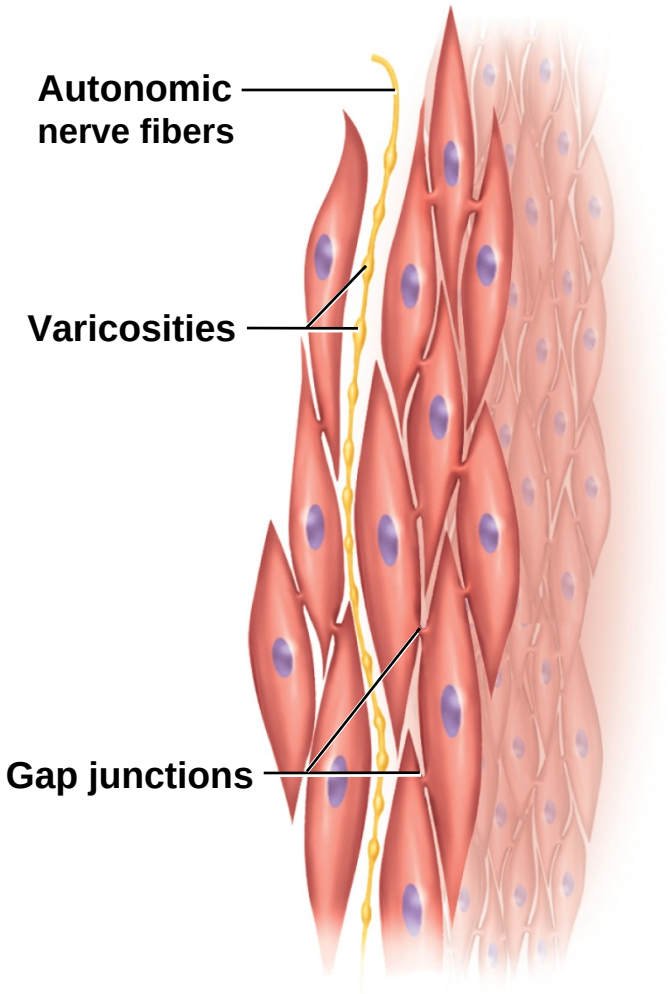

(b) Single-unit smooth muscle

- single-unit smooth muscle
  - more widespread
  - occurs in most blood vessels, in the digestive, respiratory, urinary, and reproductive tracts
  - also called visceral muscle
    - often in two layers
    - inner circular
    - outer longitudinal
  - myocytes of this cell type are electrically coupled to each other by gap junctions
  - they directly stimulate each other and a large number of <u>cells contract as a single unit</u>

2 Types of Smooth Muscle – 3 of 3

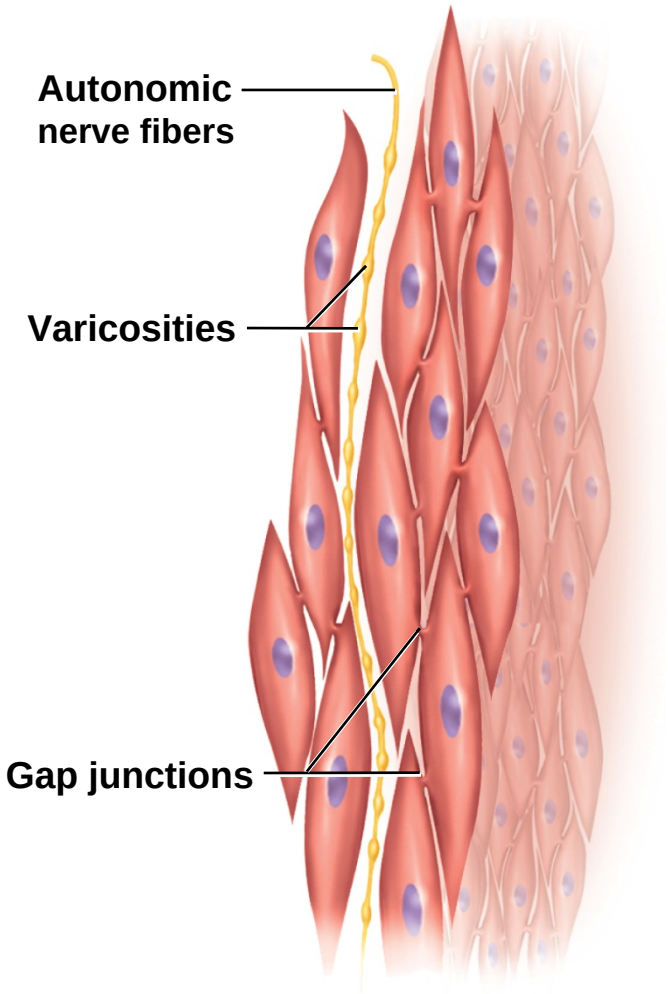

(b) Single-unit smooth muscle

- in single unit smooth, each autonomic nerve fibers has up to 20,000 beadlike swelling called varicosities
  - each contains synaptic vesicles and a few mitochondria
  - nerve fiber passes amid several myocytes and stimulates all of them at once when it releases its neurotransmitter
    - no motor end plates, but receptors scattered throughout the surface
    - diffuse junctions – no one-to-one relationship between nerve fiber and myocyte

Stimulation of Smooth Muscle

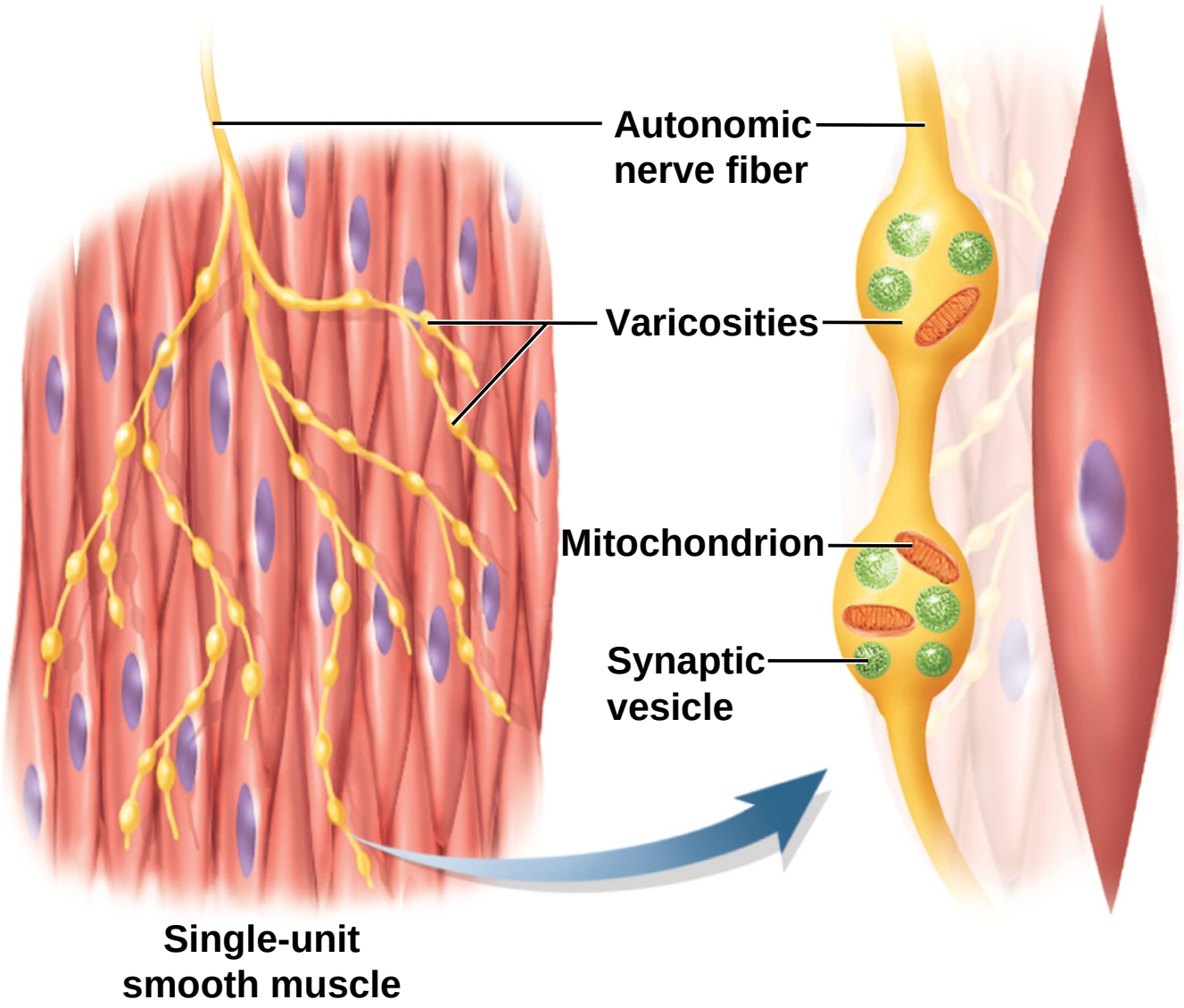

Layers of Visceral Muscle

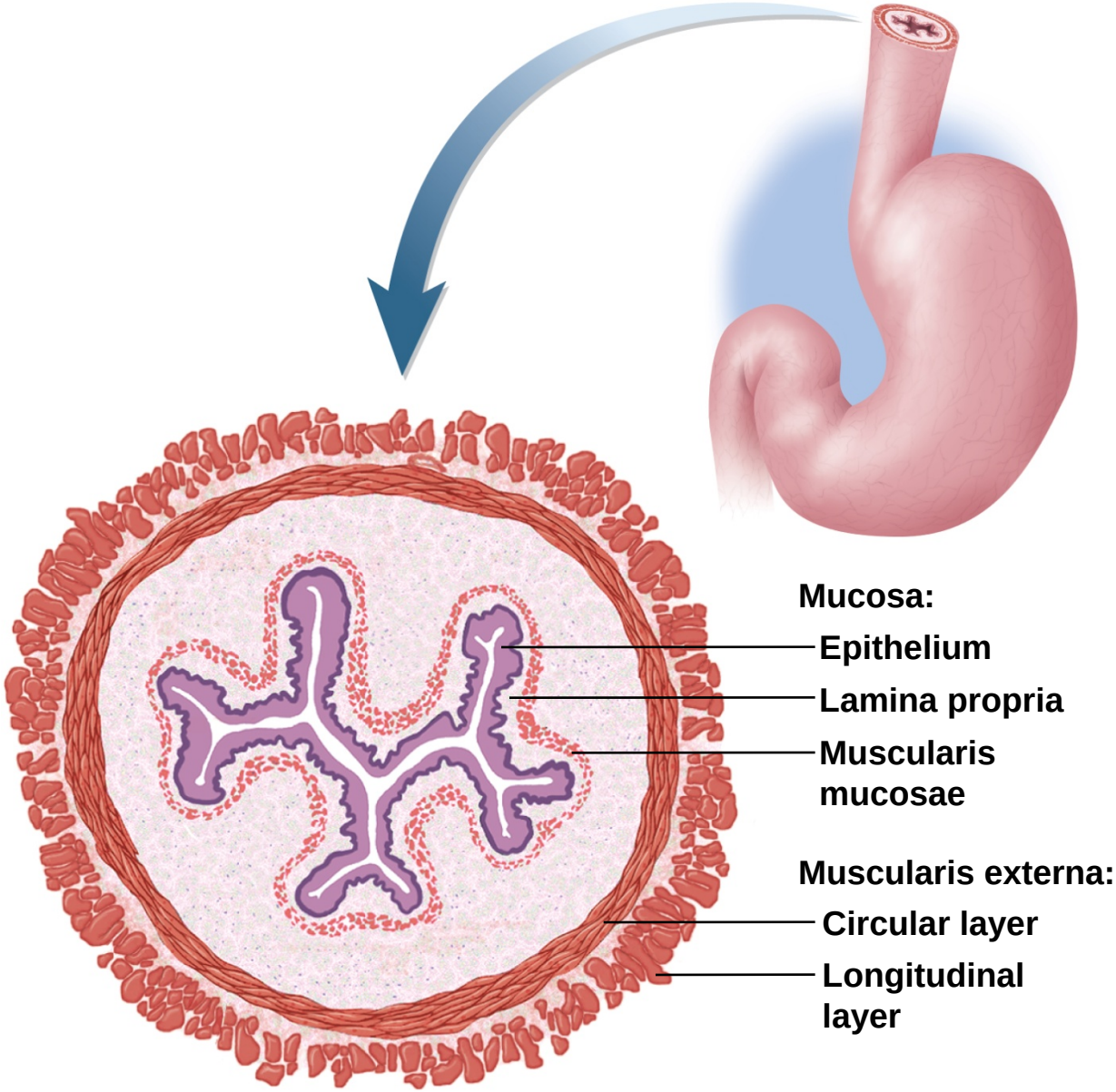

Smooth Muscle Contraction and Relaxation

- contraction is triggered by Ca^{+2}, energized by ATP, and achieved by sliding thin past thick filaments

- contraction begins in response to Ca^{+2} that enters the cell from ECF, a little internally from sarcoplasmic reticulum
  - Ca^{+2} channels open to allow Ca^{+2} to enter cell
  - voltage, ligand, and mechanically-gated (stretching)

- calcium binds to **calmodulin** on thick filaments
  - activates **myosin light-chain kinase –** adds phosphate to regulatory protein on myosin head
  - **myosin ATPase**
    - hydrolyzing ATP
    - enables myosin *similar power and recovery strokes like skeletal muscle*

  - thick filaments pull on thin ones - thin ones pull on dense bodies and membrane plaques
    - force is transferred to plasma membrane and entire cell shortens
    - puckers and twists like someone wringing out a wet towel

Contraction and Relaxation

- very slow in comparison to skeletal muscle
  - latent period in skeletal 2 msec, smooth muscle 50 - 100 msec
  - tension peaks at about 500 msec (0.5 sec)
  - declines over a period of 1 – 2 seconds
  - slows myosin ATPase enzyme and slow pumps that remove Ca^{+2}
  - Ca^{+2} binds to calmodulin instead of troponin // activates kinases and ATPases that hydrolyze ATP
  - <u>smooth muscle makes most of its ATP aerobically</u>

Contraction and Relaxation

- smooth muscle <u>resistant to fatigue</u>
  - **latch-bridge mechanism** - heads of myosin molecules do not detach from actin immediately
  - do not consume more ATP immediately
  - maintains tetanus tonic contraction (smooth muscle tone)
    - arteries – vasomotor tone
    - intestinal tone

Contraction of Smooth Muscle

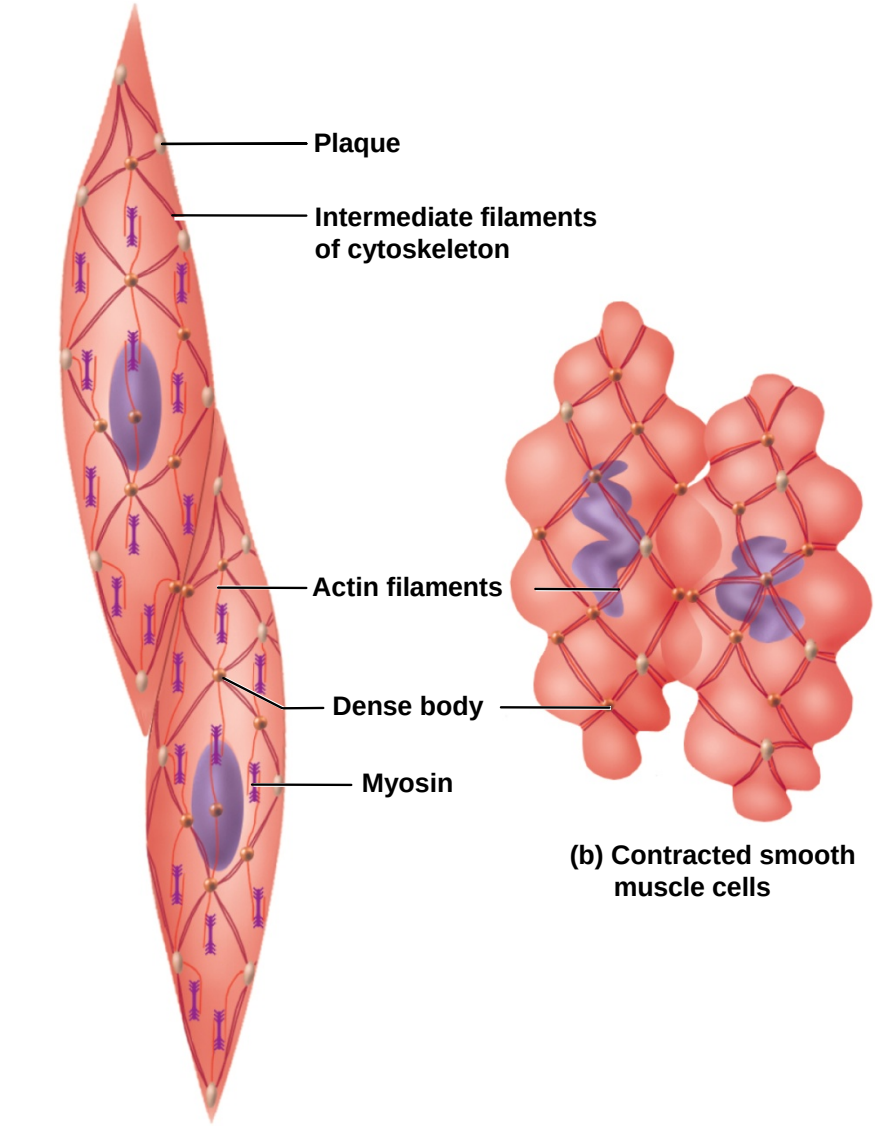

(a) Relaxed smooth muscle cells

(b) Contracted smooth muscle cells

Stretching Smooth Muscle

- **stretch** can open mechanically-gated calcium channels in the sarcolemma causing contraction
  - **peristalsis** – waves of contraction brought about by food distending the esophagus or feces distending the colon // propels contents along the organ
- **stress-relaxation response** (receptive relaxation)
  - helps hollow organs gradually fill (urinary bladder)
  - when stretched, tissue briefly contracts then relaxes – helps prevent emptying while filling

Contraction and Stretching

- smooth muscle contracts forcefully even when greatly stretched
  - allows hollow organs such as the stomach and bladder to fill and then expel their contents efficiently
  - smooth muscle can be anywhere from half to twice its resting length and still contract powerfully
  - skeletal muscle cannot contract forcefully if overstretched

Contraction and Stretching

- three reasons why
  - there are no z discs, so thick filaments cannot butt against them and stop contraction
  - since the thick and thin filaments are not arranged in orderly sarcomeres, stretching does not cause a situation where there is too little overlap for cross-bridges to form
  - the thick filaments of smooth muscle have myosin heads along their entire length, so cross-bridges can form anywhere
- **plasticity** – the ability to adjust its tension to the degree of stretch // a hollow organ such as the bladder can be greatly stretched yet not become flabby when it is empty

Cardiac Muscle

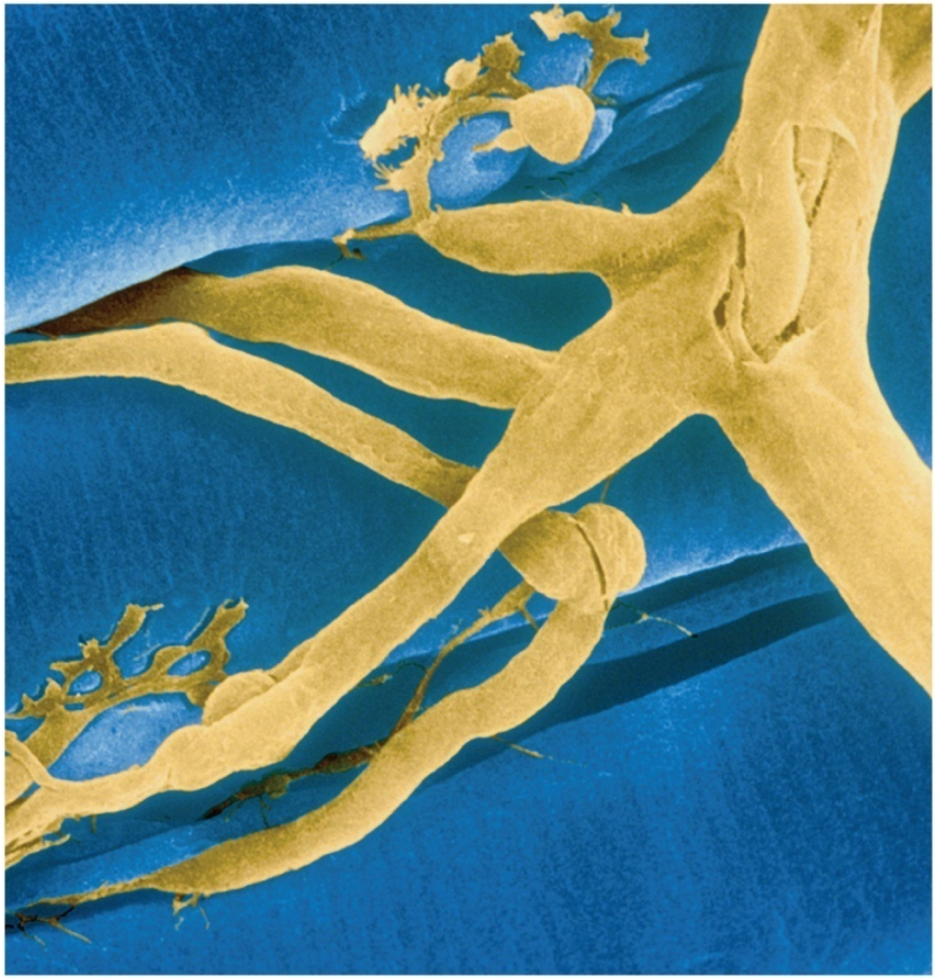

Cardiac Muscle

- limited to the heart where it functions to pump blood
- required properties of cardiac muscle
  - contraction with regular rhythm
  - muscle cells of each chamber must contract in unison
  - contractions must last long enough to expel blood
  - must work in sleep or wakefulness, with out fail, and without conscious attention
  - must be highly resistant to fatigue

Cardiac Muscle

- characteristics of cardiac muscle cells
  - **striated** like skeletal muscle, but myocytes (cardiocytes) are **shorter and thicker**
  - each myocyte is joined to several others at the uneven, notched linkages – **intercalated discs**
    - appear as thick dark lines in stained tissue sections
    - electrical **gap junctions** allow each myocyte to directly stimulate its neighbors
    - mechanical junctions that keep the myocytes from pulling apart
  - sarcoplasmic reticulum less developed, but T tubules are larger and admit supplemental Ca^{2+} from the extracellular fluid
  - damaged cardiac muscle cells repair by **fibrosis**
    - a little mitosis observed following heart attacks
    - not in significant amounts to regenerate functional muscle

Cardiac Muscle

- can contract without need for nervous stimulation
  - contains a built-in **pacemaker** that rhythmically sets off a wave of electrical excitation
  - wave travels through the muscle and triggers contraction of heart chambers
  - **autorhythmic** – because of its ability to contract rhythmically and independently
- **autonomic nervous system** does send nerve fibers to the heart
  - can increase or decrease heart rate and contraction strength
- very slow twitches - does not exhibit quick twitches like skeletal muscle
  - maintains tension for about 200 to 250 msec
  - gives the heart time to expel blood
- uses **aerobic respiration** almost exclusively
  - rich in myoglobin and glycogen
  - has especially **large mitochondria**
    - 25% of volume of cardiac muscle cell
    - 2% of skeletal muscle cell with smaller mitochondria
- very adaptable with respect to fuel used
- very vulnerable to interruptions of oxygen supply
- highly fatigue resistant