Chapter 20 (1)

The Heart

Learning Objectives

- **Describe the location and structure of the heart**
- **Describe the path of a drop of blood from the superior vena cava or inferior vena cava through the heart out of the aortic arch, listing all chambers, valves, and vessels involved.**
- **State the function of the atria, valves, chordae tendinae, papillary muscles, and ventricles of the heart**

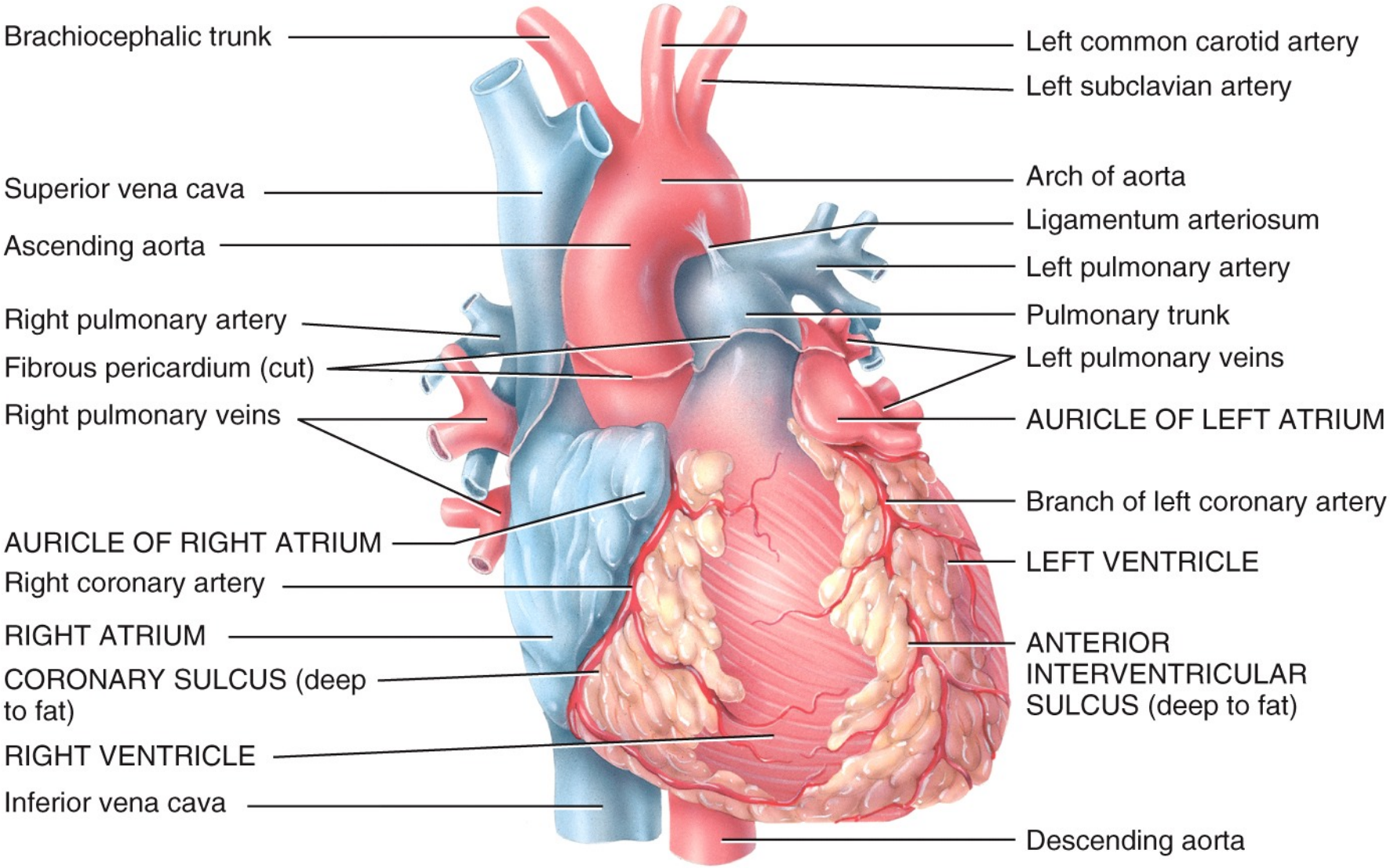

(a) Anterior external view showing surface features

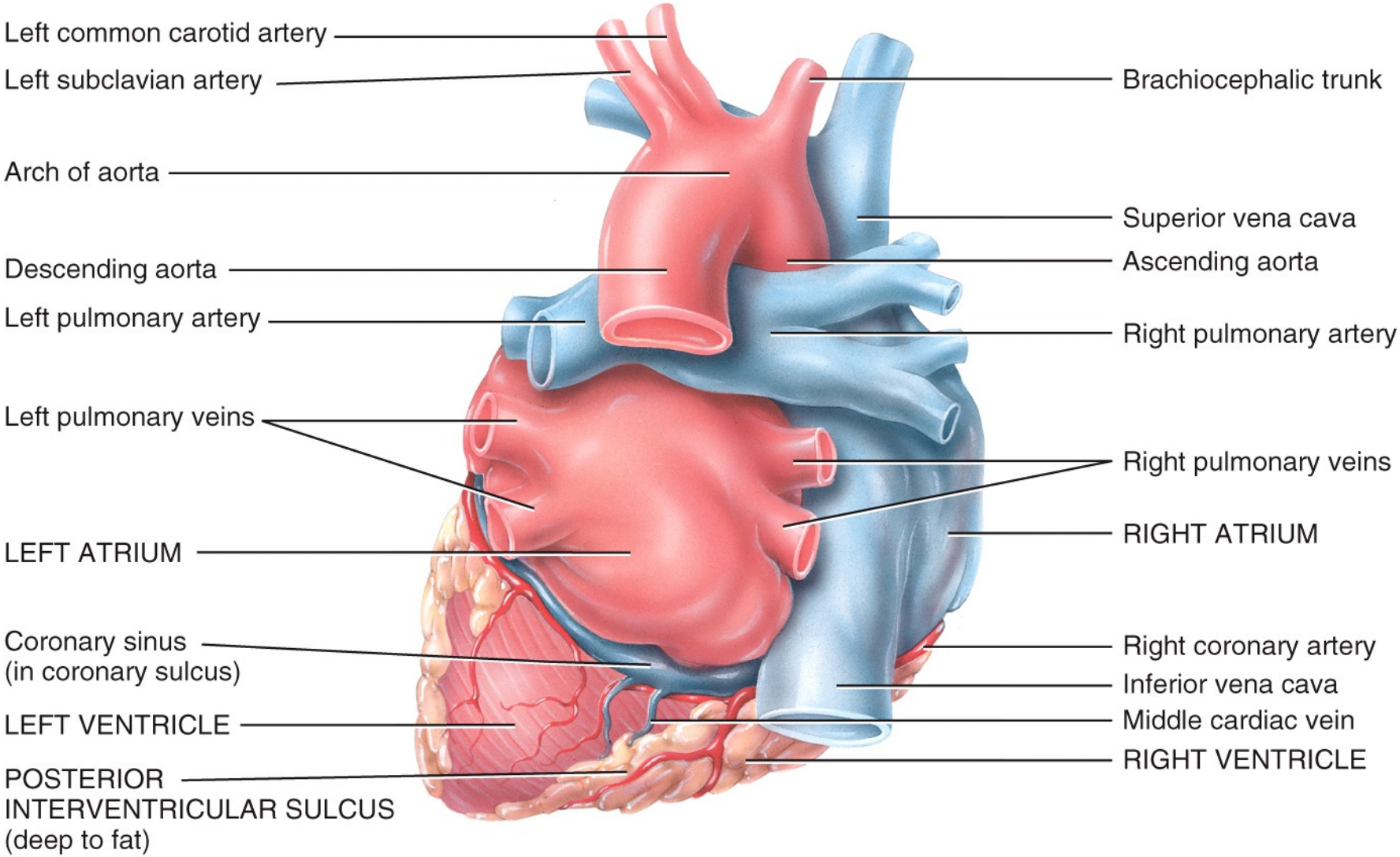

(c) Posterior external view showing surface features

Circulatory Circuits of the Heart

- Pulmonary circuit
  - right side of heart to lungs
  - carries blood to lungs for gas exchange and back to heart // low pressure
- Systemic circuit
  - left side of heart to all tissue of body except lungs
  - supplies oxygenated blood to all tissues of the body and returns it to the heart // high pressure

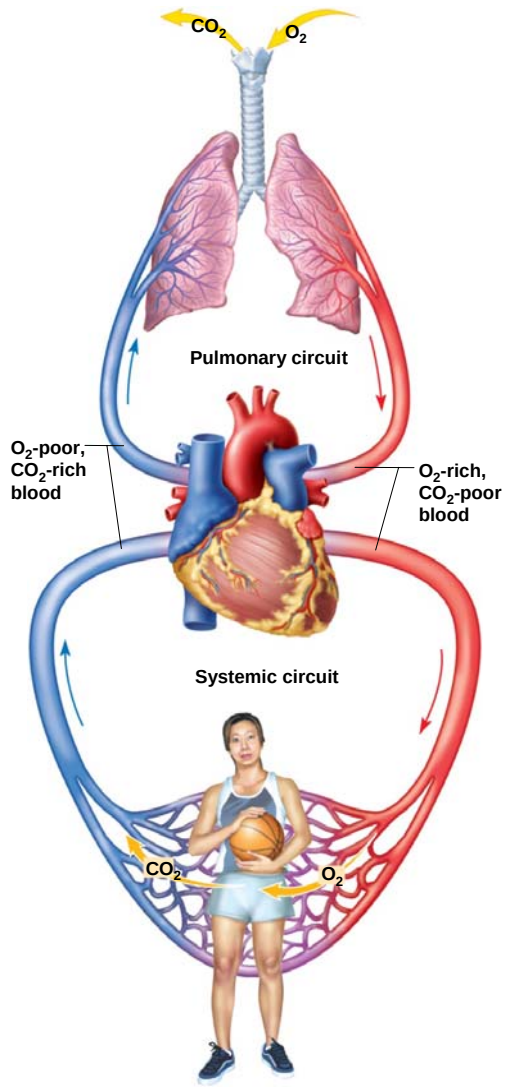

Circulatory Circuits of the Heart

– Coronary circuit

- part of the systemic circuit
- aortic recoil moves blood into the coronary arteries
- supply the myocardiocytes (the cells making the walls of the heart) with blood circulation

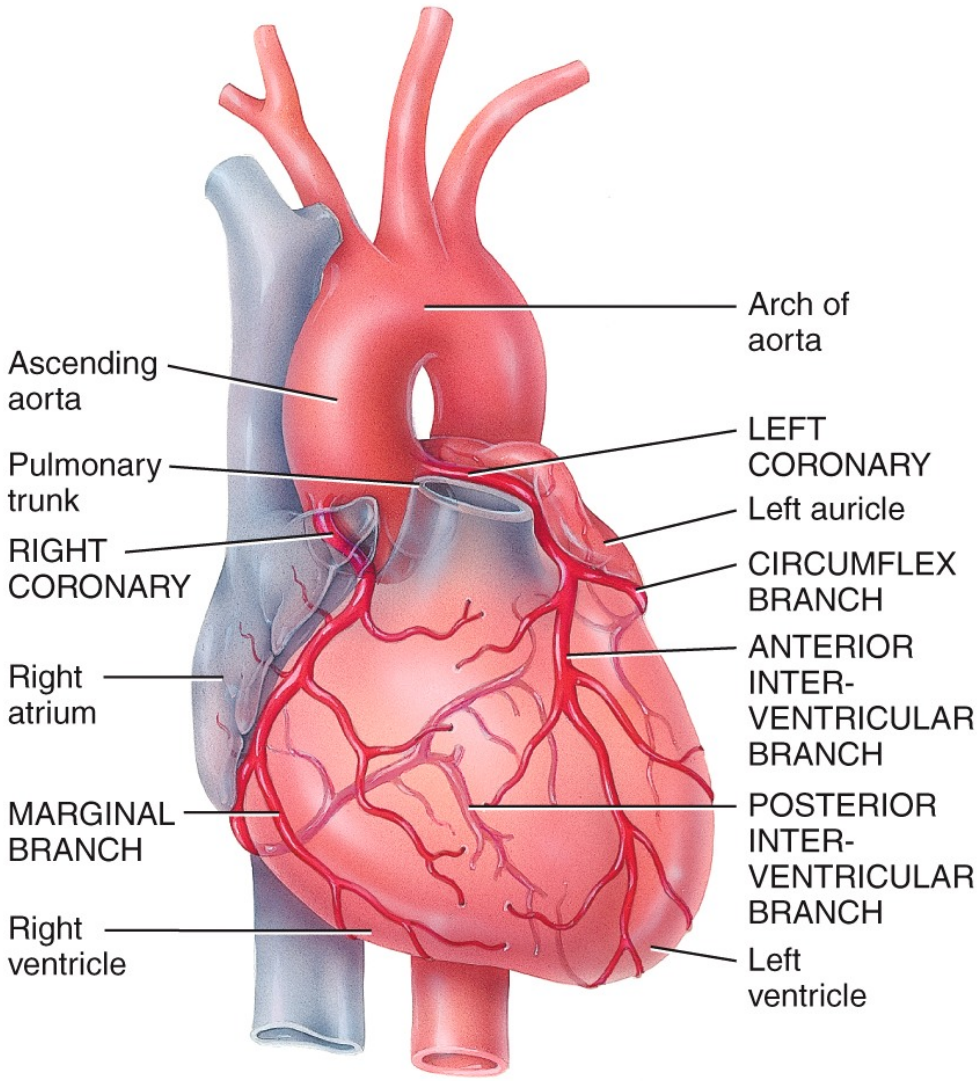

(a) Anterior view of coronary arteries

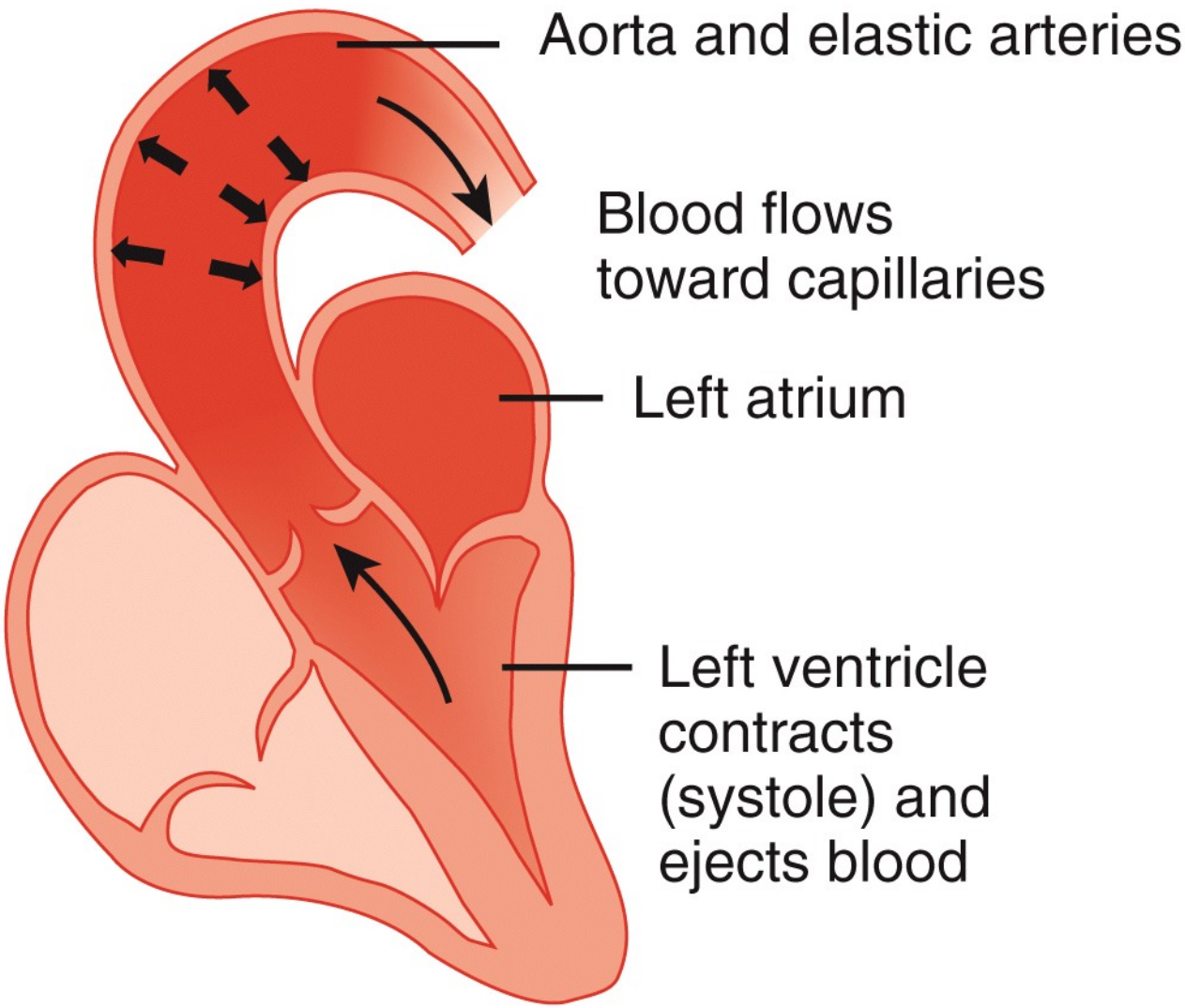

(a) Elastic aorta and arteries stretch during ventricular contraction

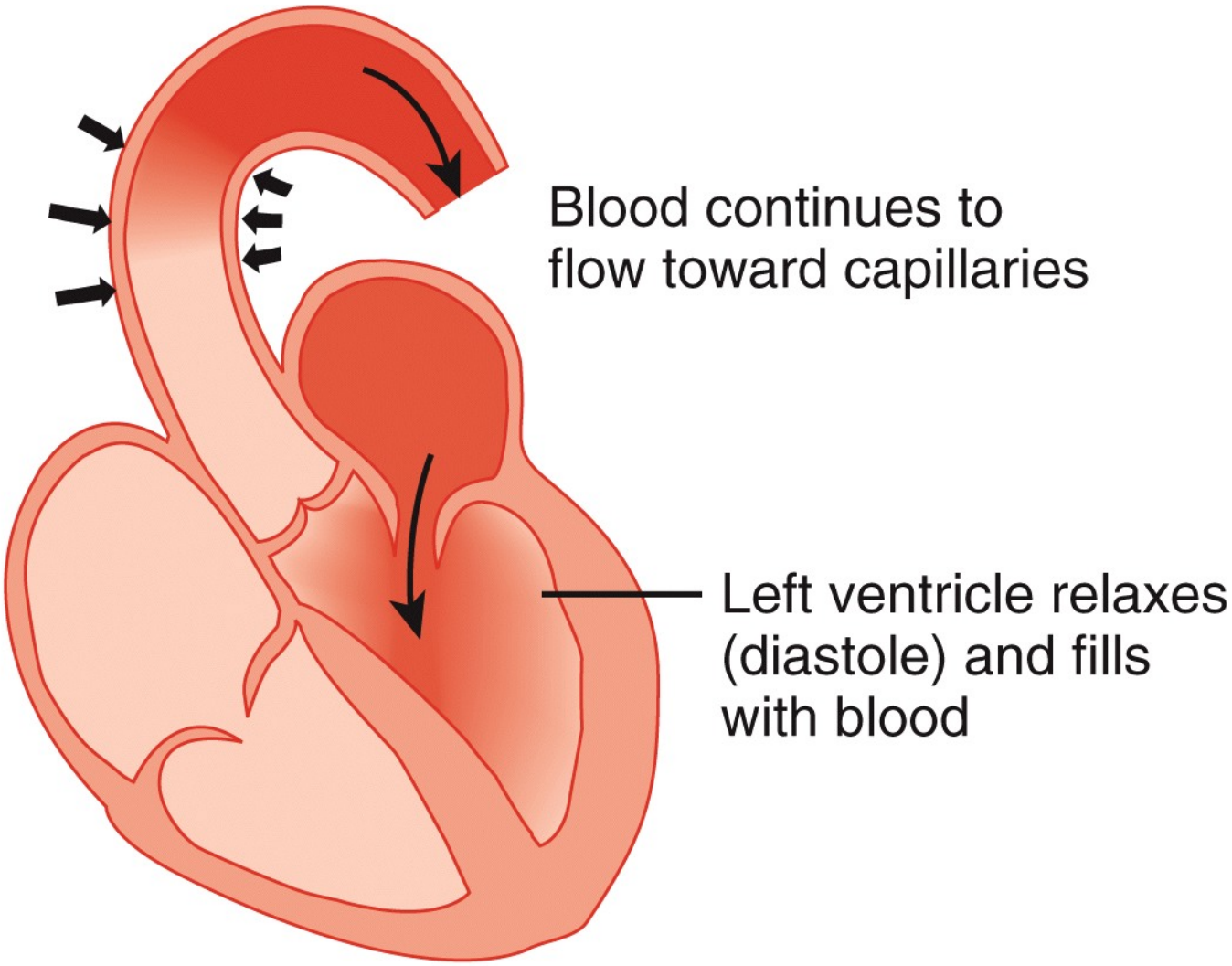

(b) Elastic aorta and arteries recoil during ventricular relaxation

Cardiovascular System Circuit

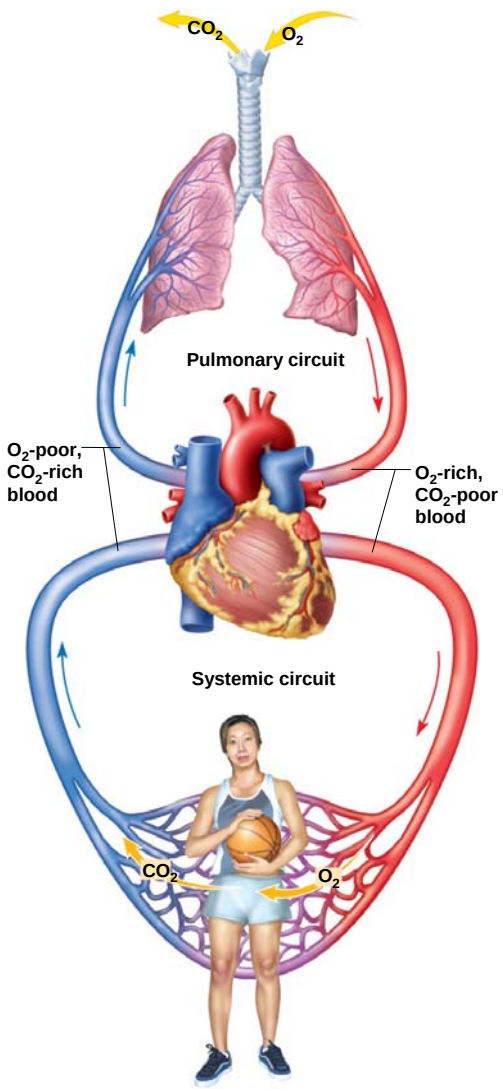

- Left side of heart
  - fully oxygenated blood arrives from lungs via pulmonary veins (100% Hb-O2)
  - blood sent to all organs of the body via aorta
  - high pressure “side”
- Right side of heart
  - lesser oxygenated blood arrives from inferior and superior vena cava (75% Hb-O2)
  - blood sent to lungs via pulmonary trunk
  - low pressure “side”

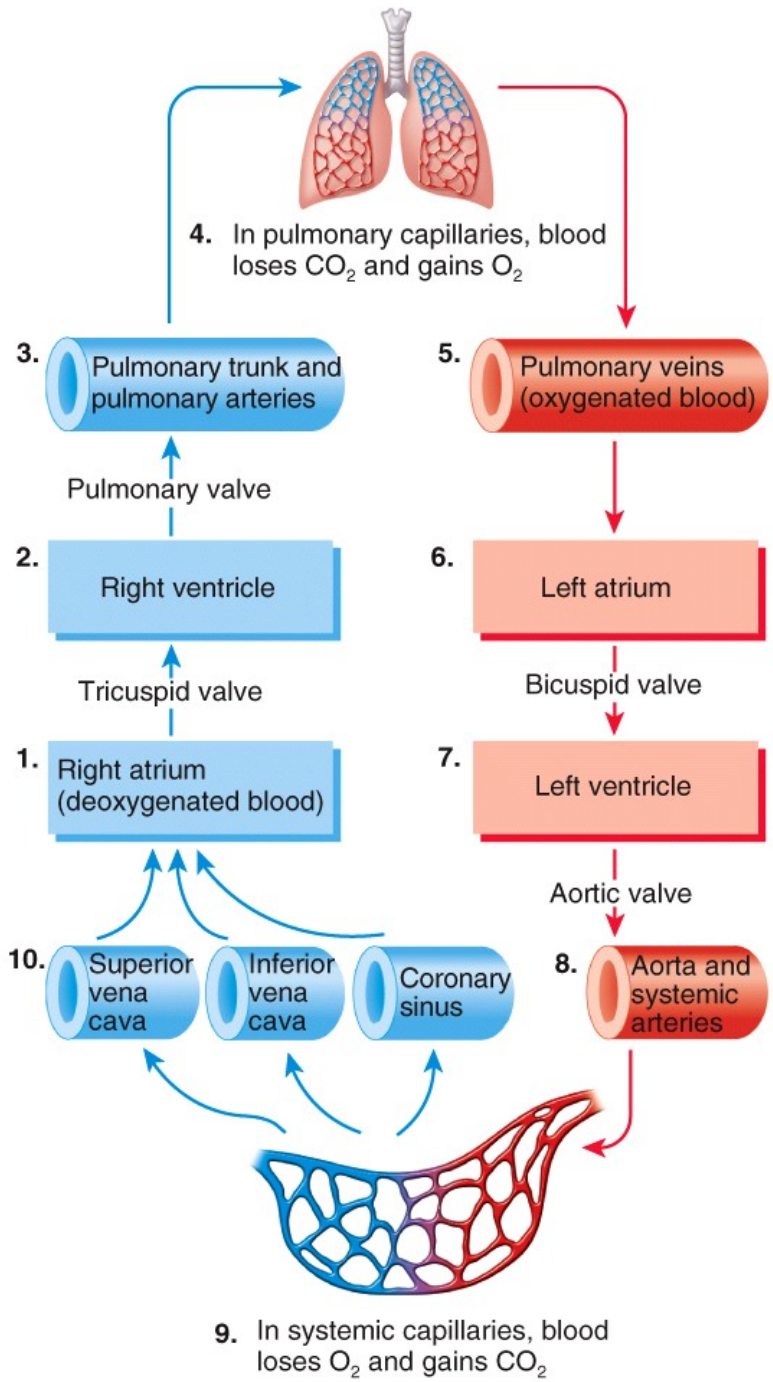

(b) Path of blood flow through systemic and pulmonary circulations

Position, Size, and Shape

- heart located in mediastinum, between lungs
- **base** – wide, superior portion of heart, blood vessels attach here
- **apex** - inferior end, tilts to the left, tapers to point
- 3.5 in. wide at base
- 5 in. from base to apex
- 2.5 in. anterior to posterior
- weighs 10 oz.

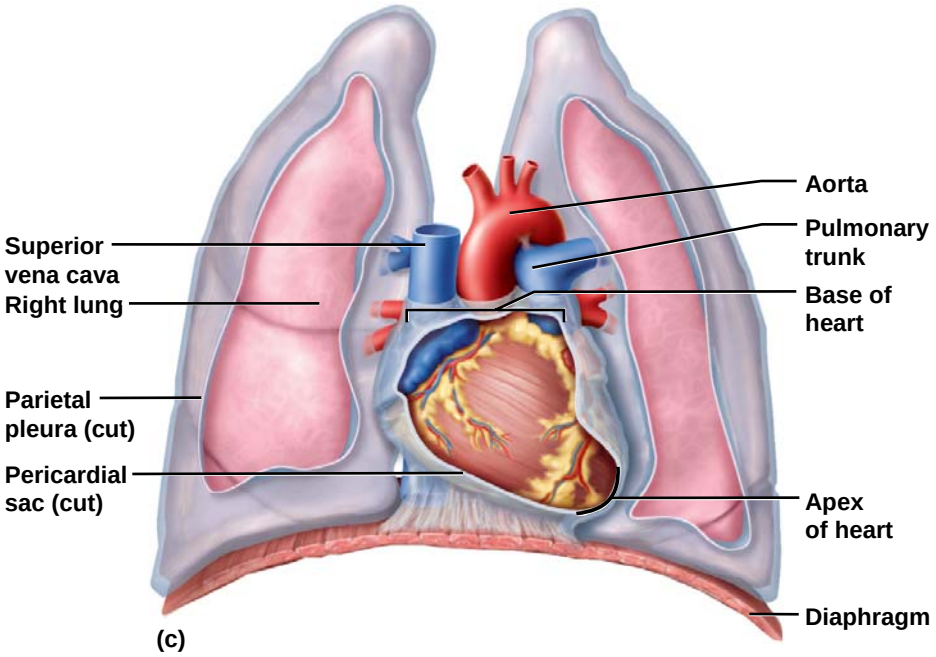

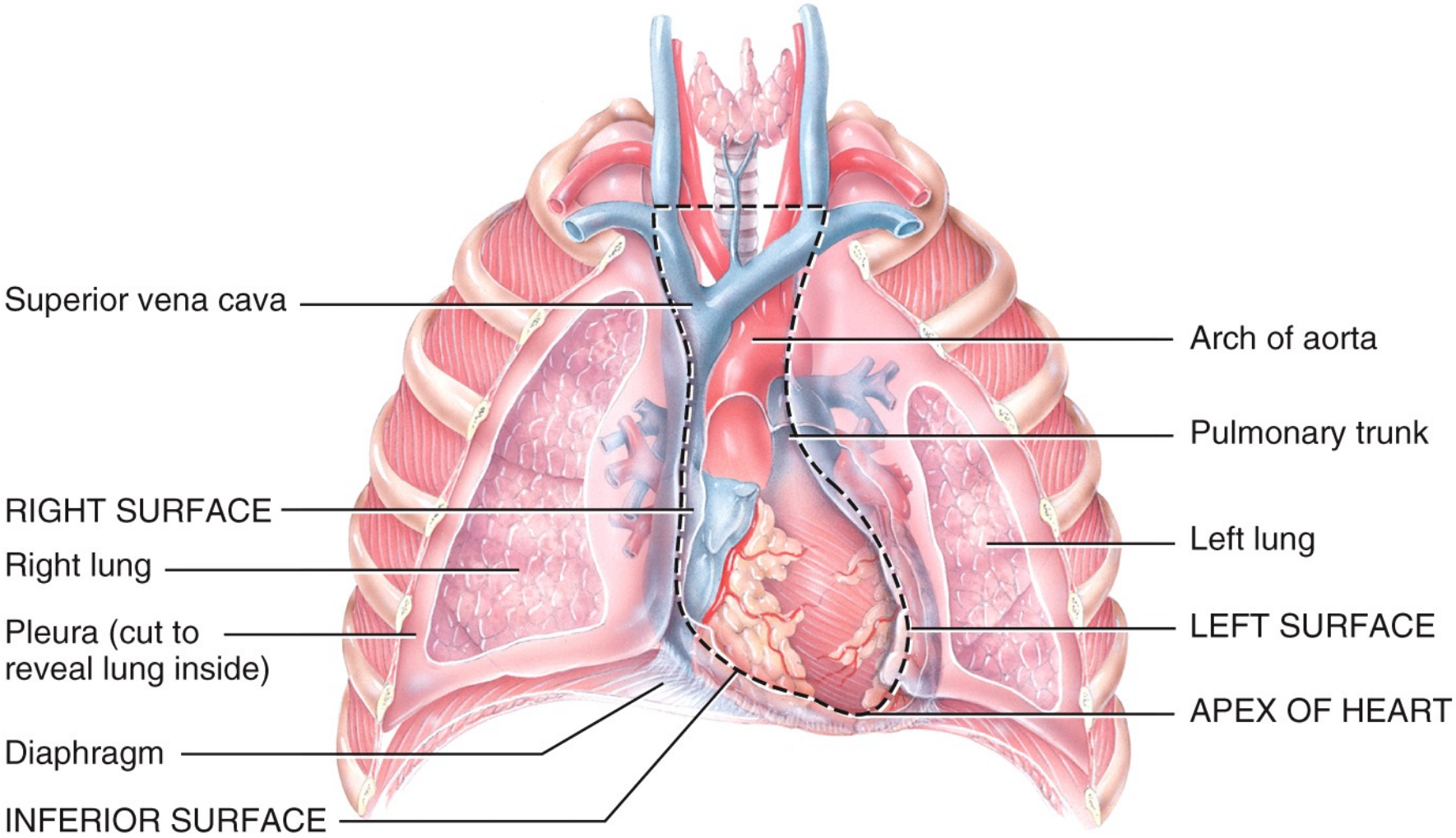

(b) Anterior view of the heart in the thoracic cavity

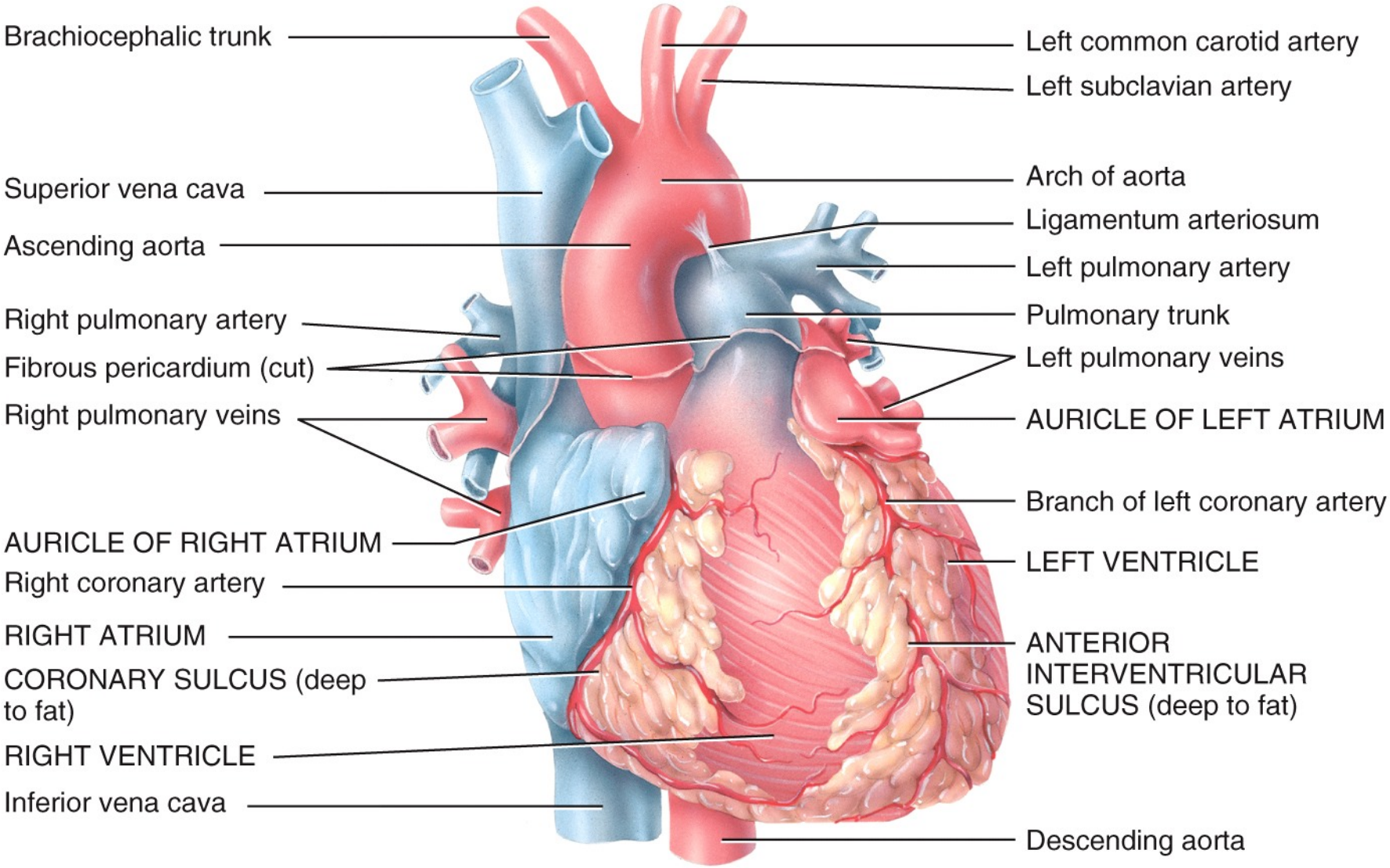

(a) Anterior external view showing surface features

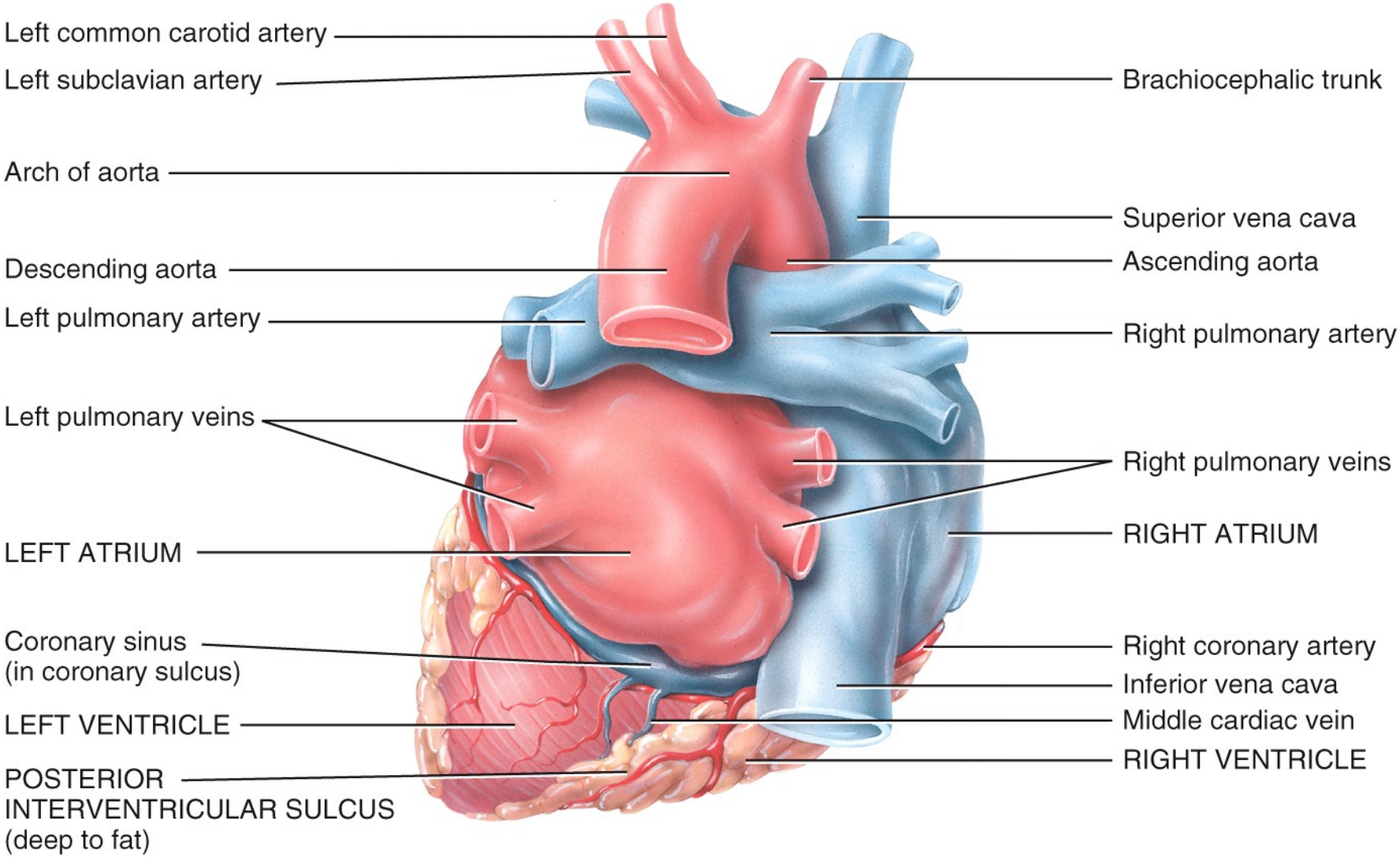

(c) Posterior external view showing surface features

Heart Position

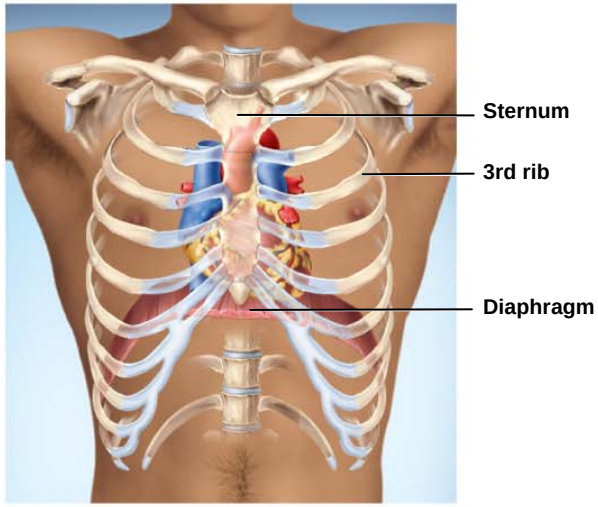

(a)

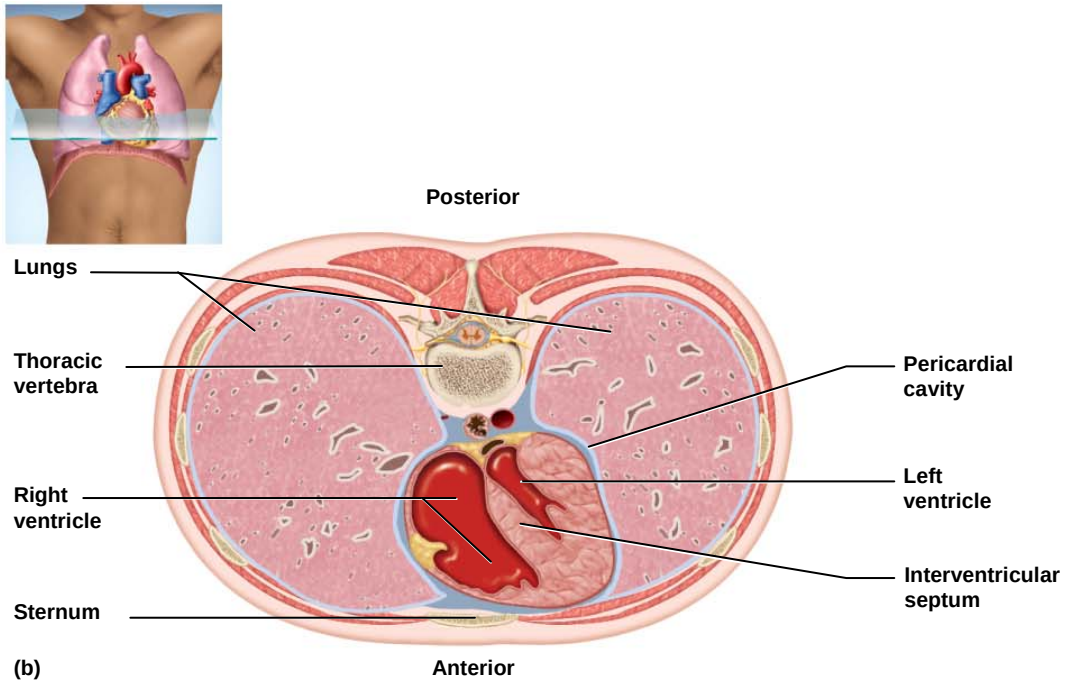

(b)

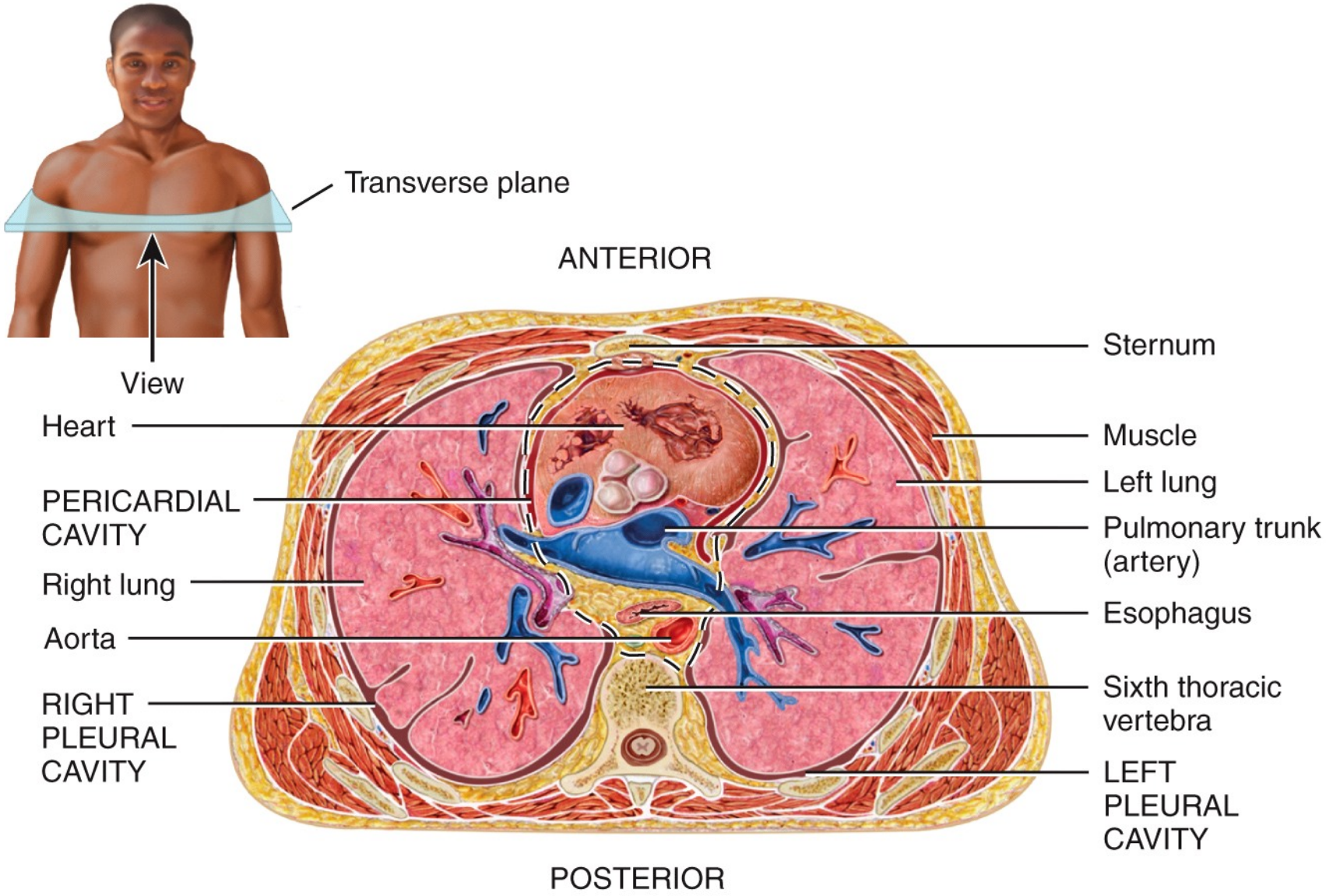

(a) Inferior view of transverse section of thoracic cavity showing the heart in the mediastinum

Blood Flow Through Heart

- Right atria
- Right ventricle
- Pulmonary truck into pulmonary circulation (lungs)
- Left atria
- Left ventricle
- Aorta to systemic circulation (all tissues of body except lungs)
- (see next slide)

Note: blood enters the right atria via superior vena cava, inferior vena cava, coronary sinus, and thebesian veins (highest concentration in right atria and lowest concentration in left ventricle)

Note: blood flow through the heart is different than the pumping action of the heart // pumping action occurs as two separate pumps working "in phase" /// first action is to move blood downward in both pumps – followed by both pumps moving blood upward

Blood Flow Through Heart

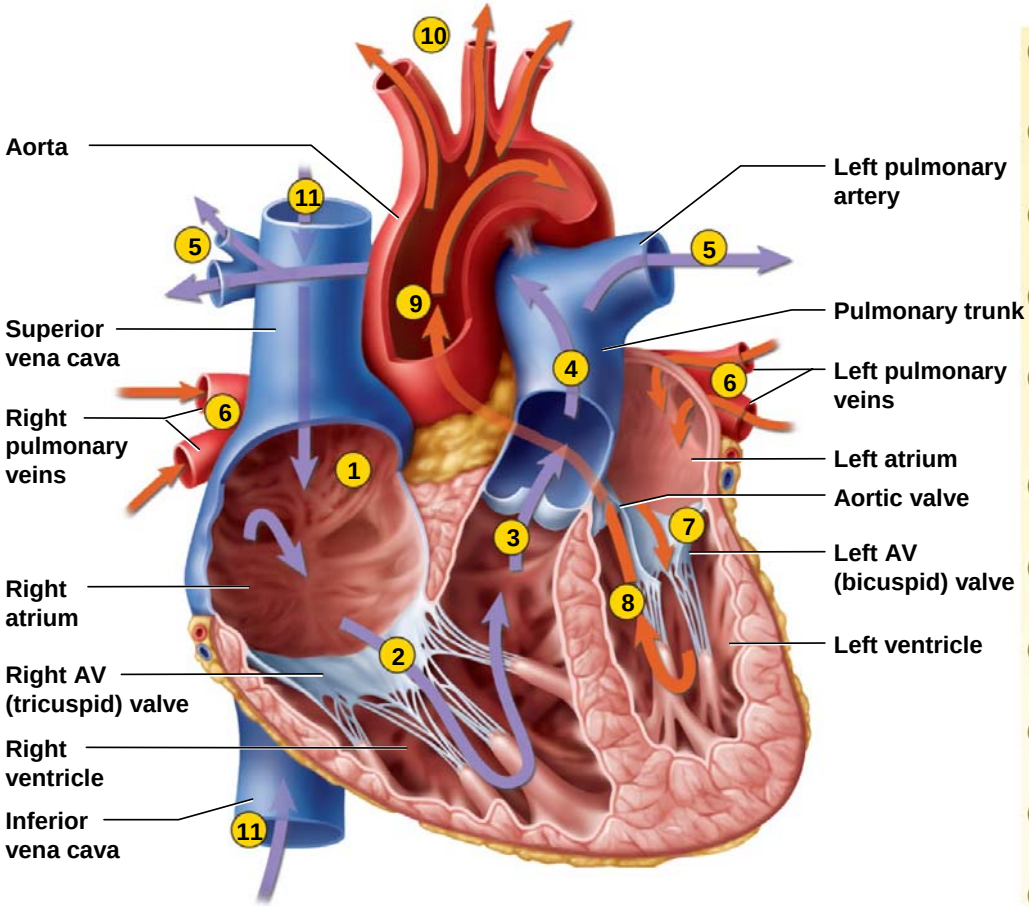

1. Blood enters right atrium from superior and inferior venae cavae.
2. Blood in right atrium flows through right AV valve into right ventricle.
3. Contraction of right ventricle forces pulmonary valve open.
4. Blood flows through pulmonary valve into pulmonary trunk.
5. Blood is distributed by right and left pulmonary arteries to the lungs, where it unloads CO_2 and loads O_2.
6. Blood returns from lungs via pulmonary veins to left atrium.
7. Blood in left atrium flows through left AV valve into left ventricle.
8. Contraction of left ventricle (simultaneous with step 3) forces aortic valve open.
9. Blood flows through aortic valve into ascending aorta.
10. Blood in aorta is distributed to every organ in the body, where it unloads O_2 and loads CO_2.
11. Blood returns to heart via venae cavae.

blood starts transit through heart in right atria / blood pressure and heart valves direct flow of blood / no valves associated with inferior or superior vena cava

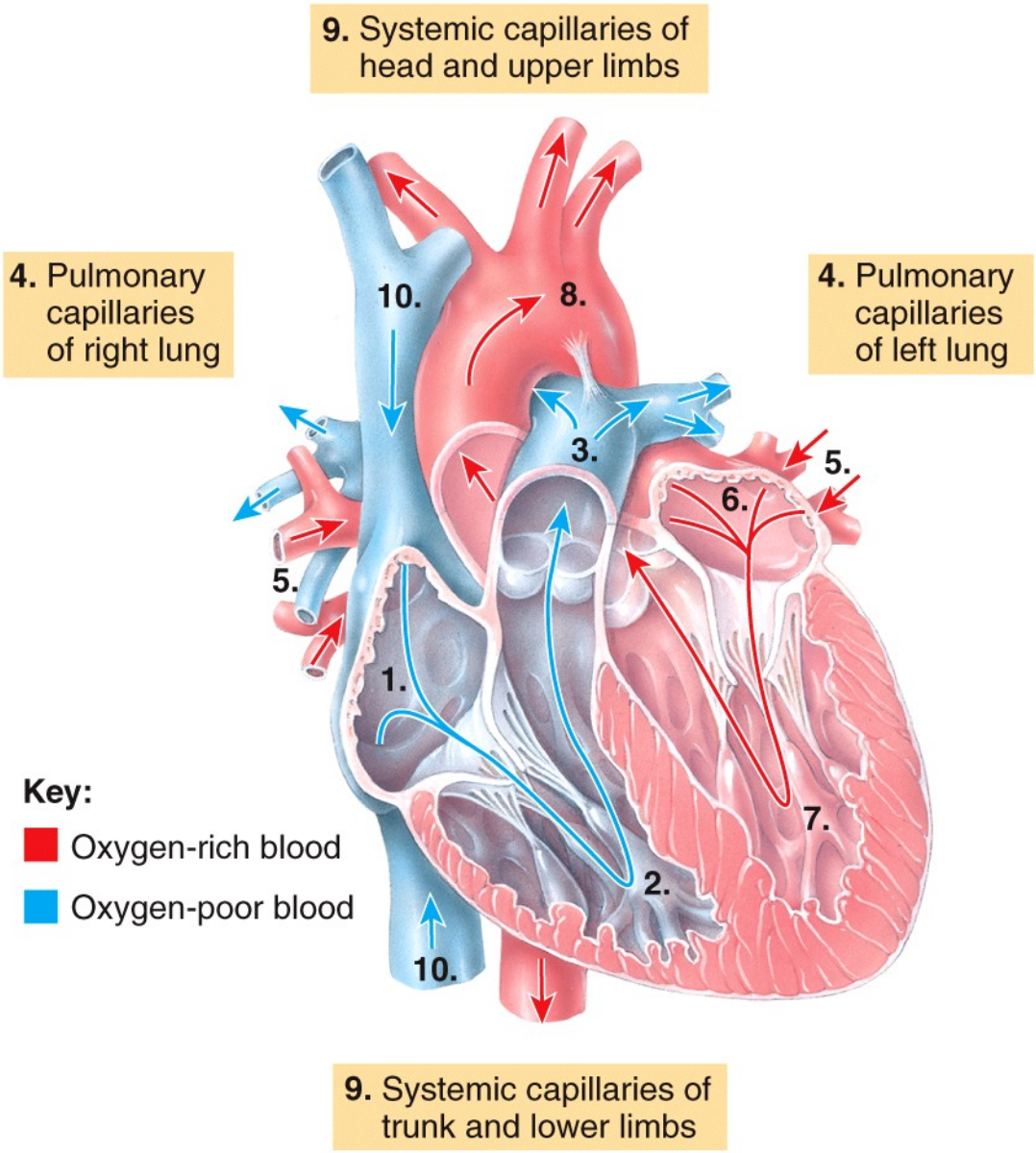

(a) Path of blood flow through heart

Pericardium and Heart Wall

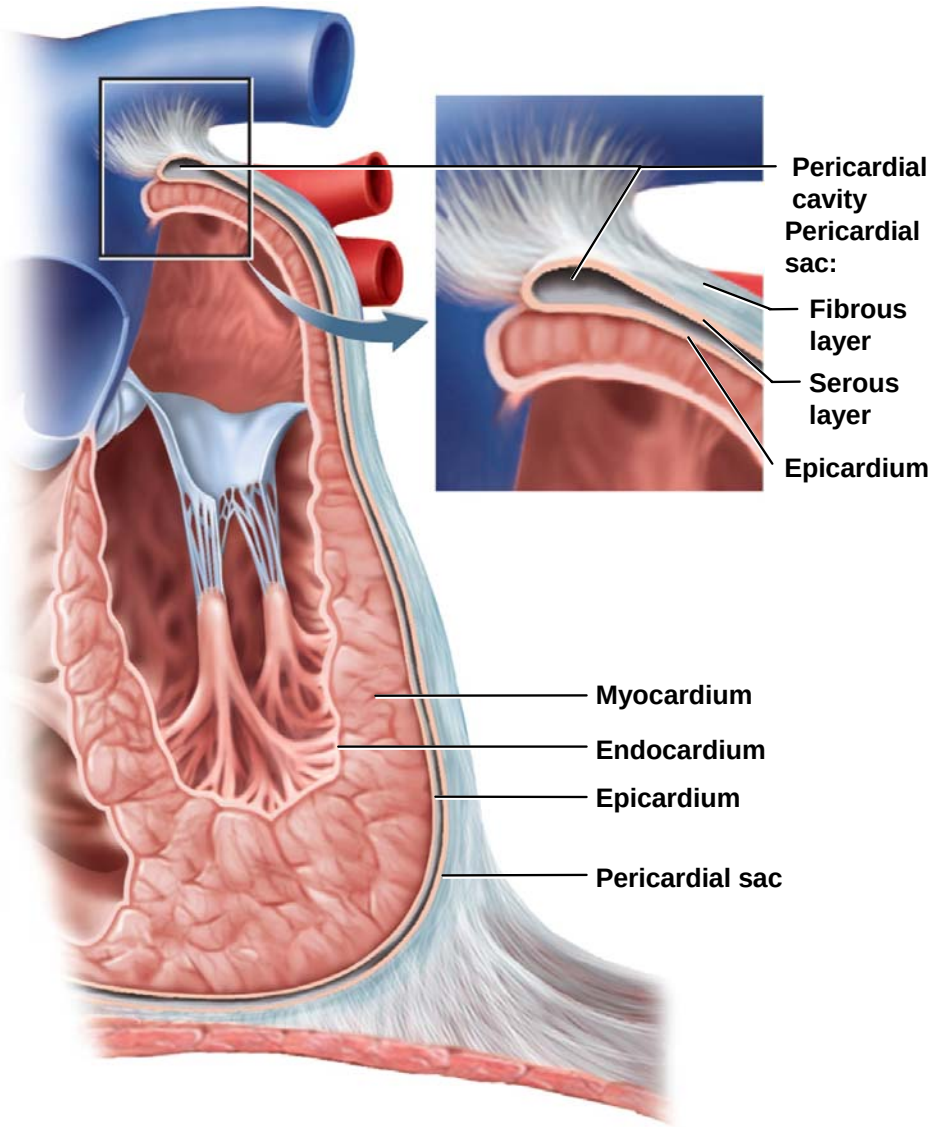

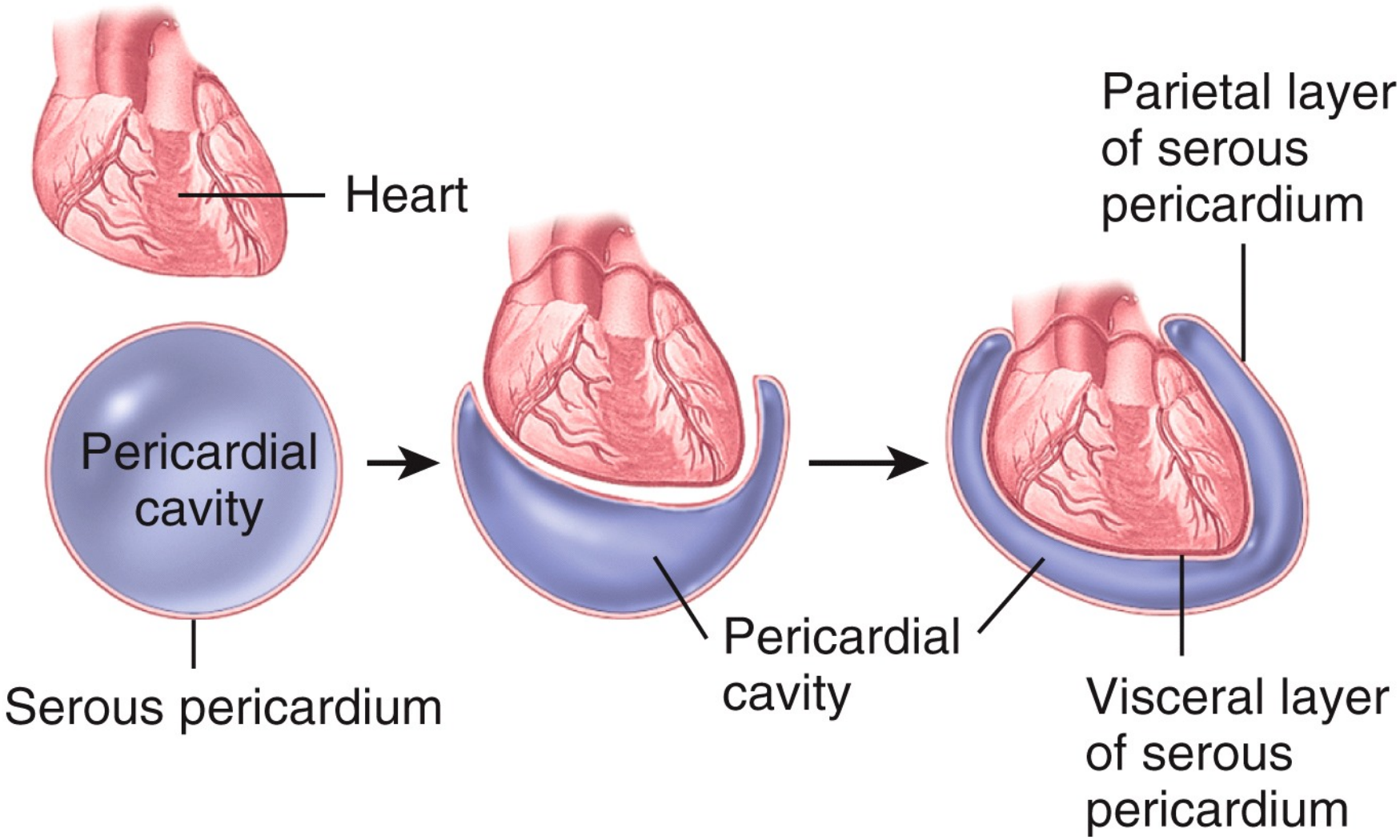

(b) Simplified relationship of serous pericardium to heart

Pericardium

- **Pericardium**
  - double-walled sac (pericardial sac) that encloses the heart // fibrous pericardium with inner and outer surface
  - allows heart to beat without friction, provides room to expand // resists excessive expansion
  - anchored to diaphragm inferiorly and sternum on anterior surface
- **Parietal pericardium**
  - outer wall of sac
  - superficial **fibrous layer** of connective tissue
  - a deep, thin **serous layer**

Pericardium

- **Visceral pericardium (epicardium)**
  - simple squamous epithelium / heart covering
  - serous lining of pericardial sac // turns inward at base of heart to cover the heart surface
- **Pericardial cavity //** space inside the pericardial sac filled with 5 - 30 mL of pericardial fluid
- **Pericarditis //** inflammation of the membranes // painful friction rub with each heartbeat

Heart Wall

- Epicardium (visceral pericardium)
  - serous membrane covering heart
  - adipose in thick layer in some places
  - coronary blood vessels travel through this layer
- Myocardium
  - layer of cardiac muscle proportional to work load
  - muscle spirals around heart which produces wringing motion

Heart Wall

- Endocardium
  - smooth inner lining of heart and blood vessels
  - covers the valve surfaces and continuous with endothelium of blood vessels

- Fibrous skeleton of the heart
    - framework of collagenous and elastic fibers
    - provides structural support and attachment for cardiac muscle and anchor for valve tissue
    - electrical insulation between atria and ventricles important in timing and coordination of contractile activity

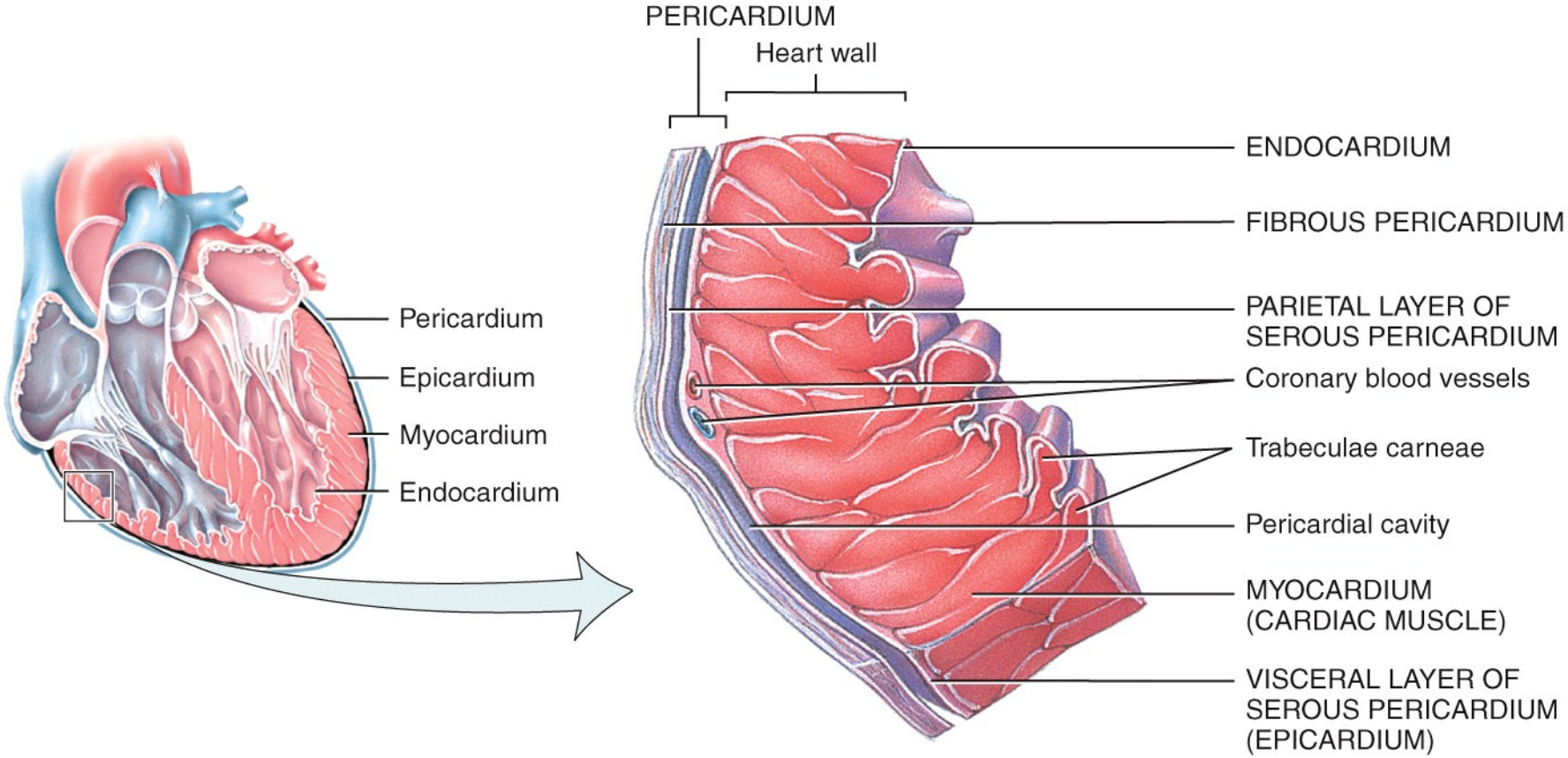

(a) Portion of pericardium and right ventricular heart wall showing divisions of pericardium and layers of heart wall

Four Chambers of he Heart

- Superior chambers
  - right and left atria
  - two superior chambers
  - receive blood returning to heart from pulmonary veins and vena cava
  - auricles (seen on surface) allow chambers to expand volume
  - both upper chambers contract together to move blood downward into the right and left ventricles

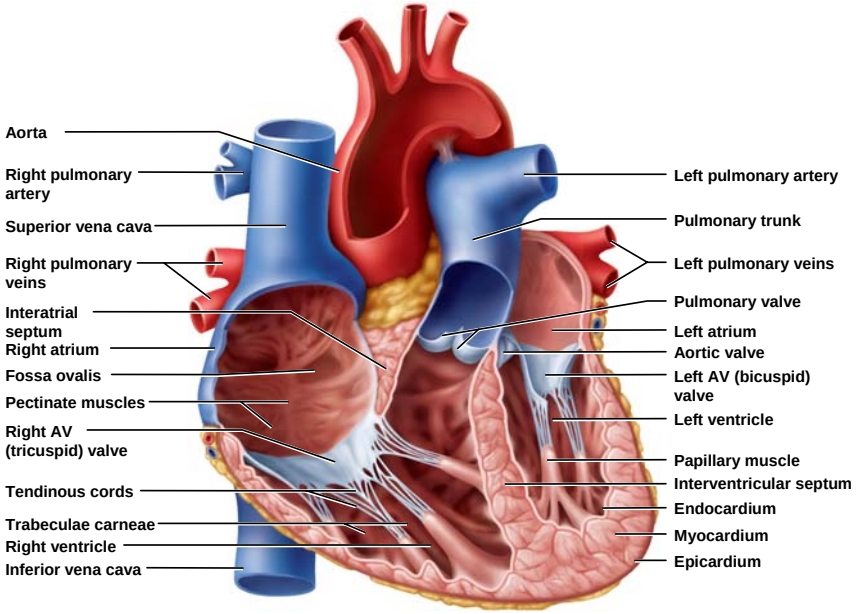

Four Chambers of he Heart

- Inferior chambers
  - right and left ventricles
  - both ventricles contract together
  - right ventricle pump blood into pulmonary truck
  - left ventricle pump blood into aorta

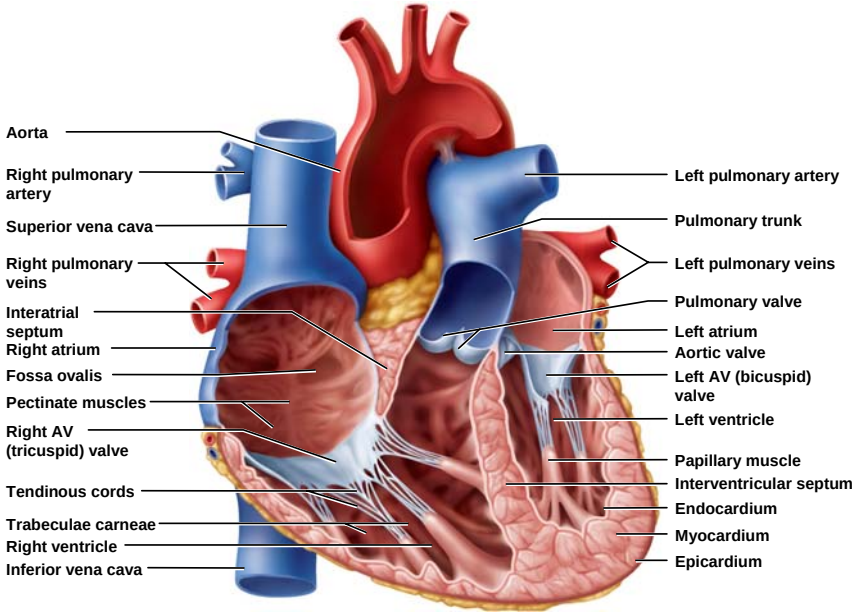

Note: heart is a four chamber pump // low pressure and high pressure sides // blood circulates through heart however blood flow moves as an “atrial downward” phase followed by a “ventricular upward” phase

External Anatomy - Anterior

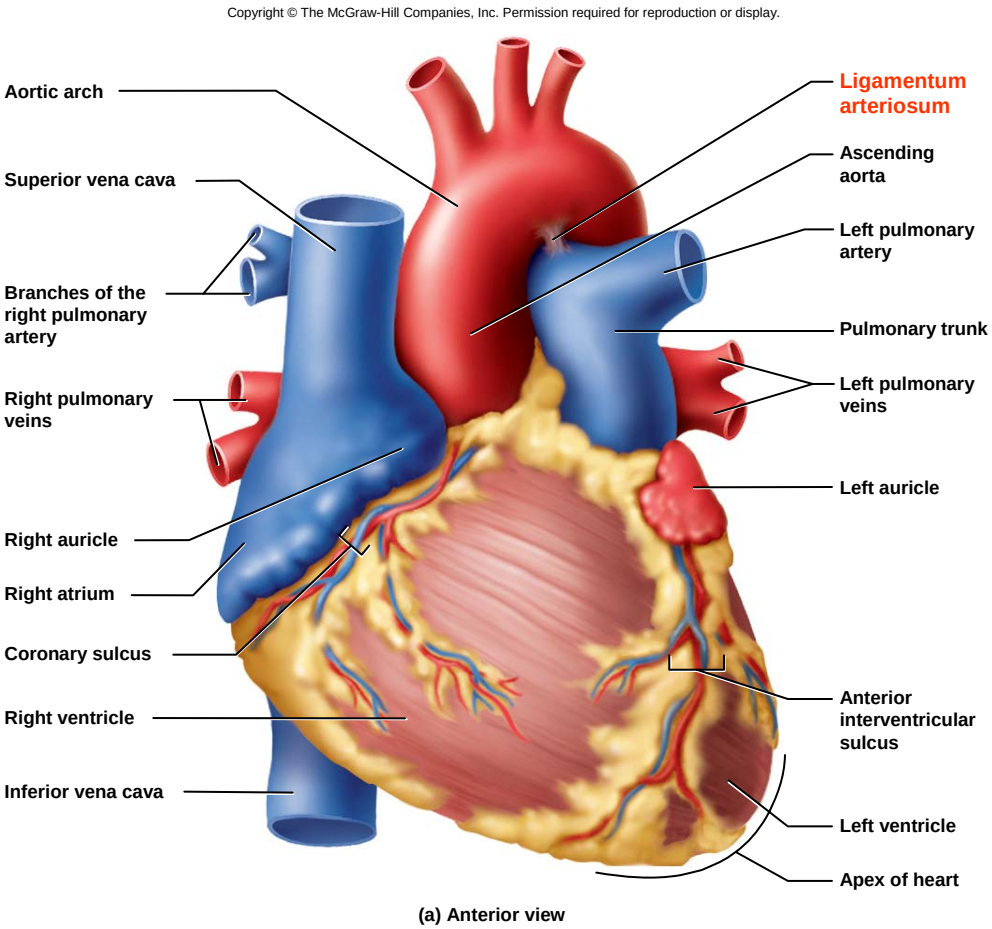

- atrioventricular sulcus
  - separates atria and ventricles
- interventricular sulcus
  - lies over the interventricular septum that divides the right ventricle from the left
  - anterior and posterior
- Note: sulci are grooves on surface of heart that contain coronary arteries, as well as other heart arteries and veins

SCHEME OF DISTRIBUTION

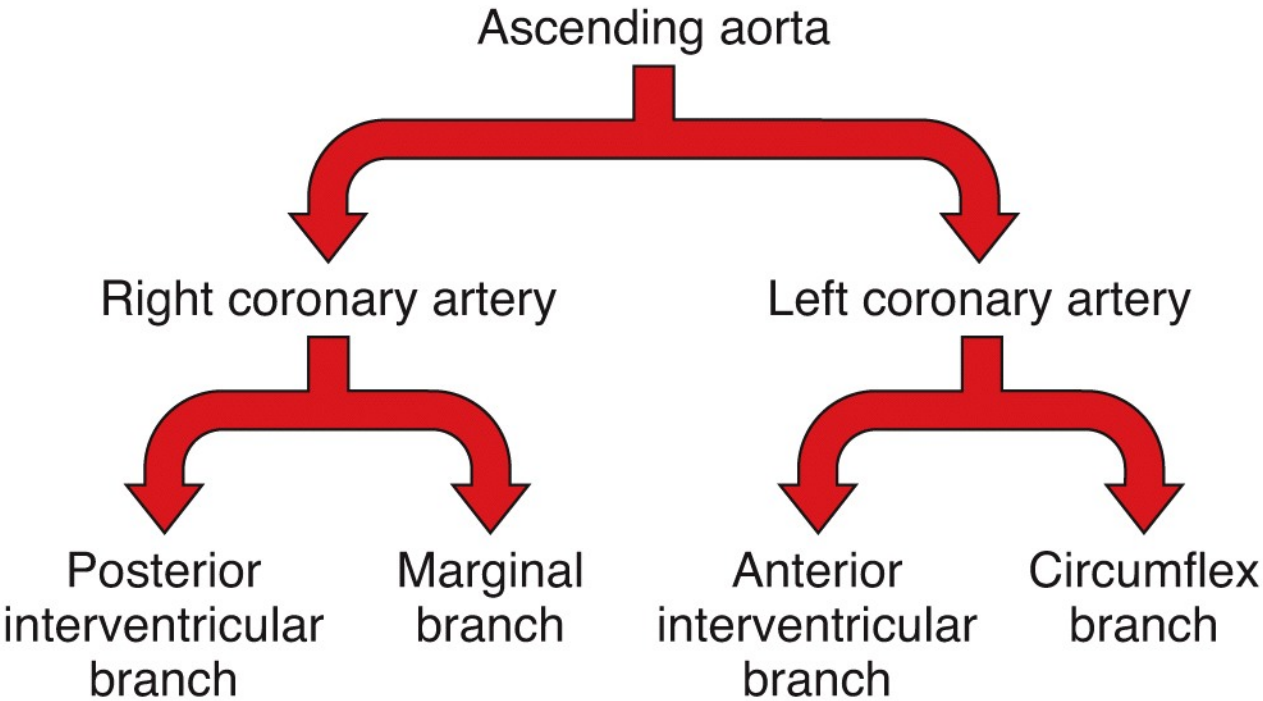

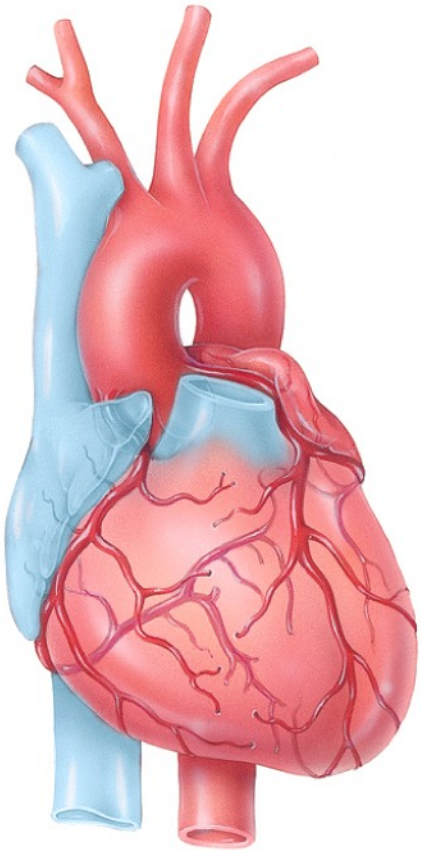

External Anatomy - Posterior

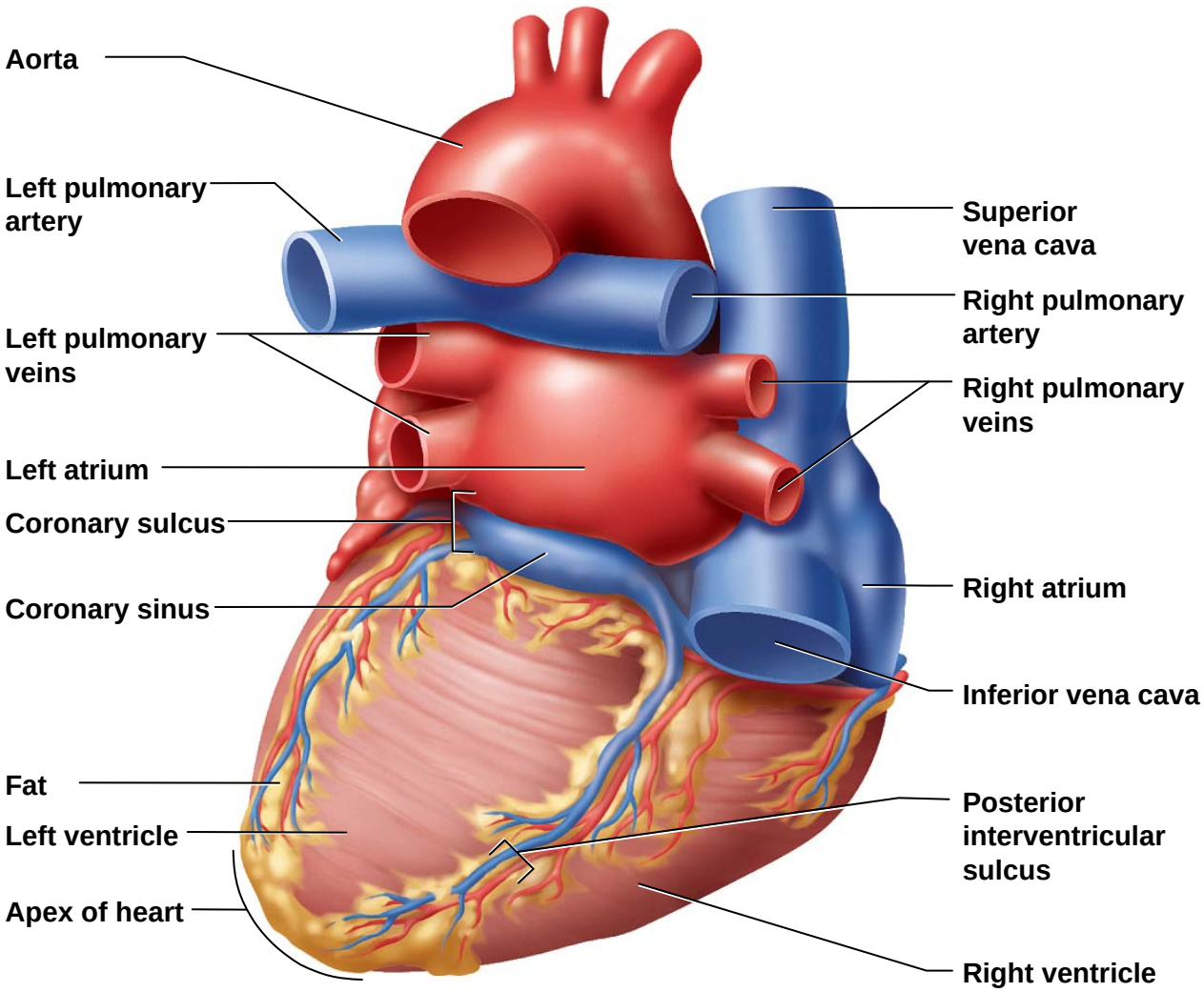

(b) Posterior view

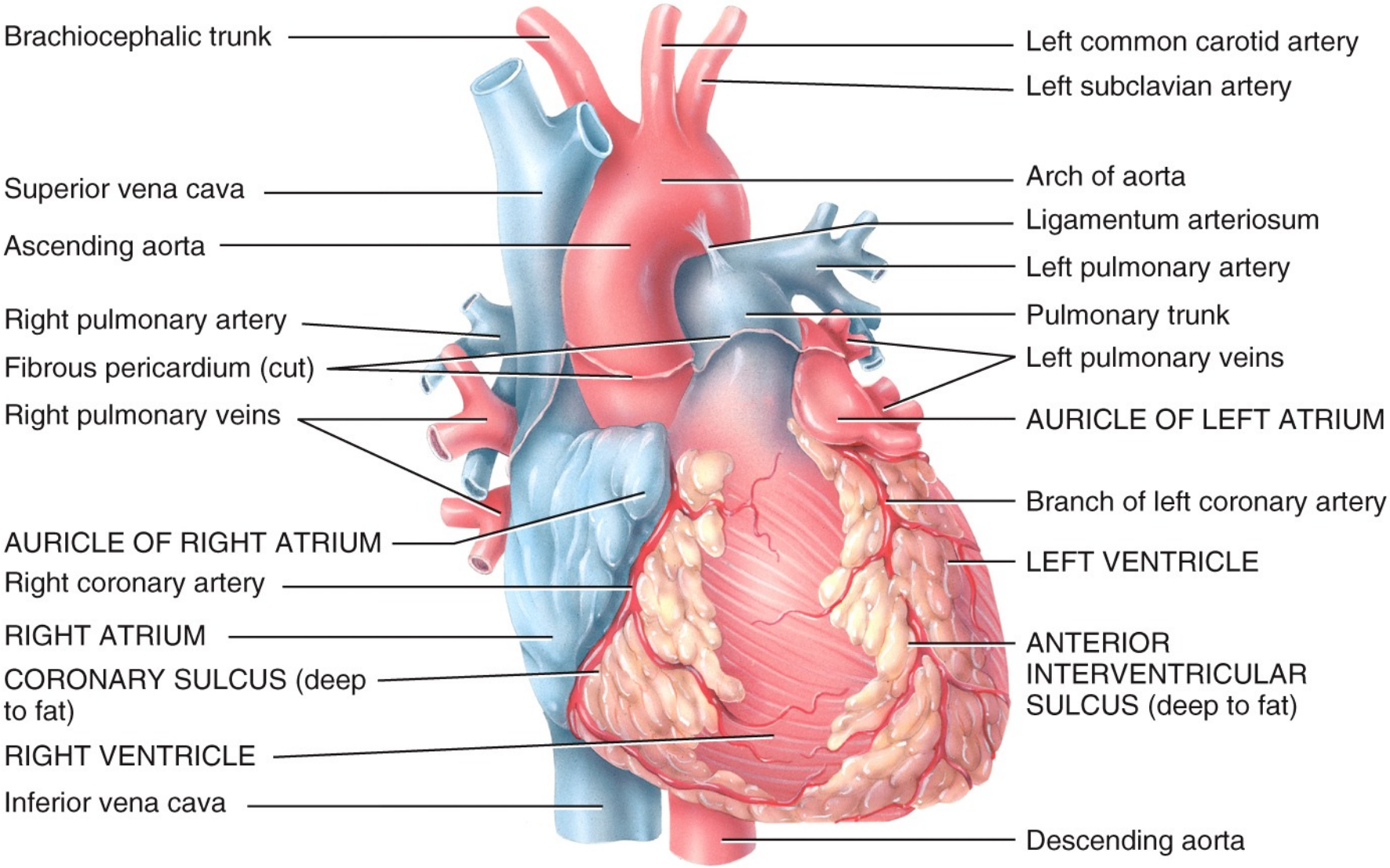

(a) Anterior external view showing surface features

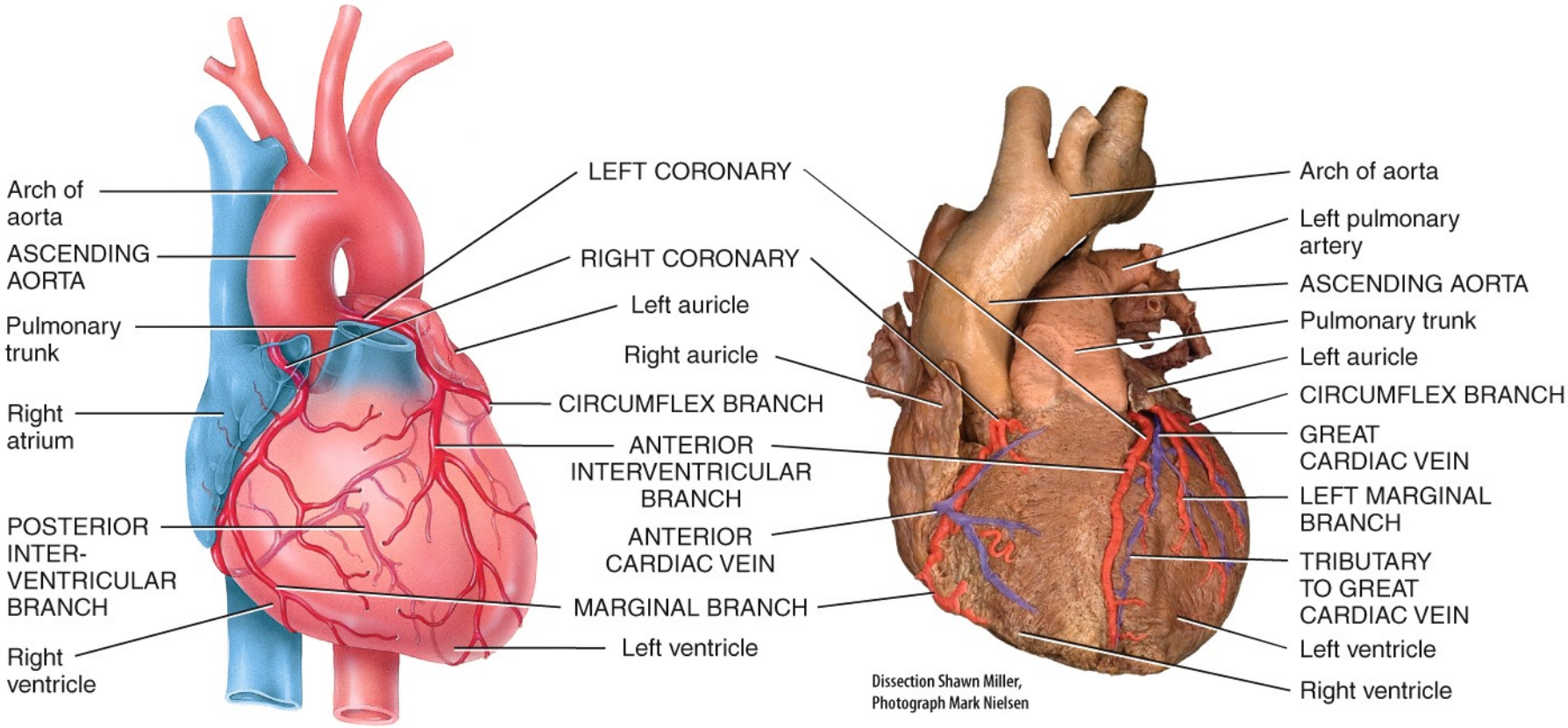

Anterior view of coronary arteries and their major branches

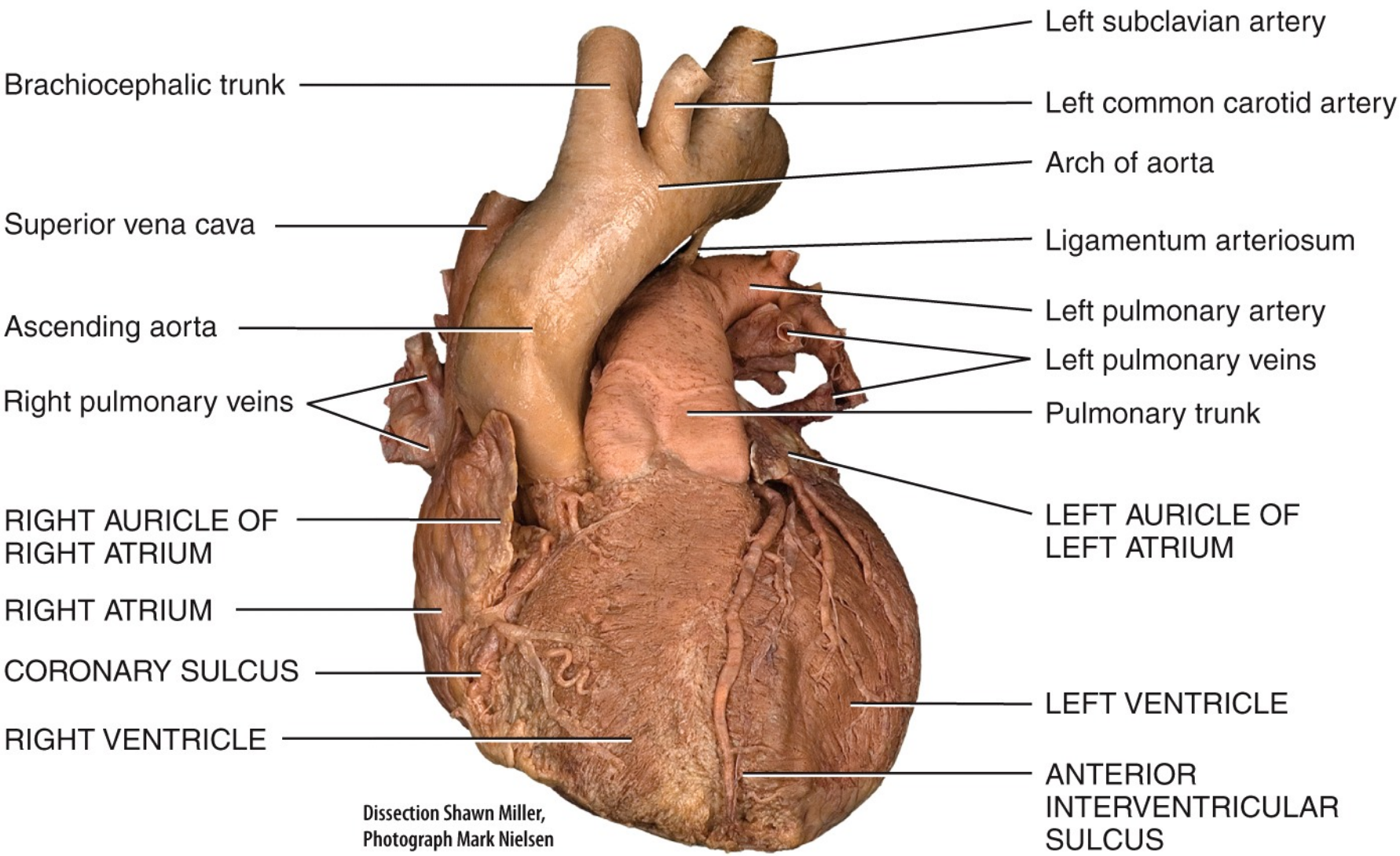

(b) Anterior external view

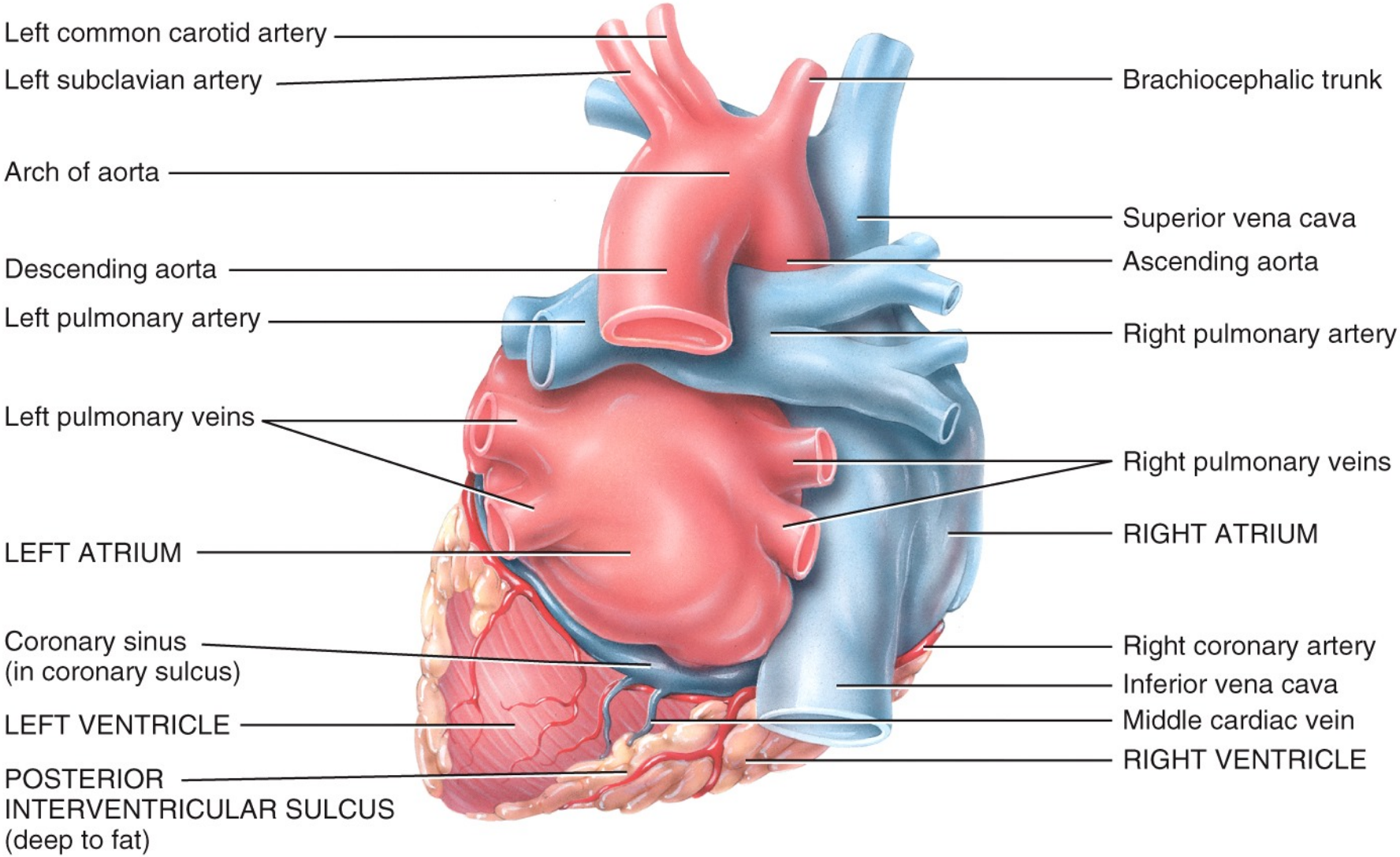

(c) Posterior external view showing surface features

Internal Anatomy - Anterior

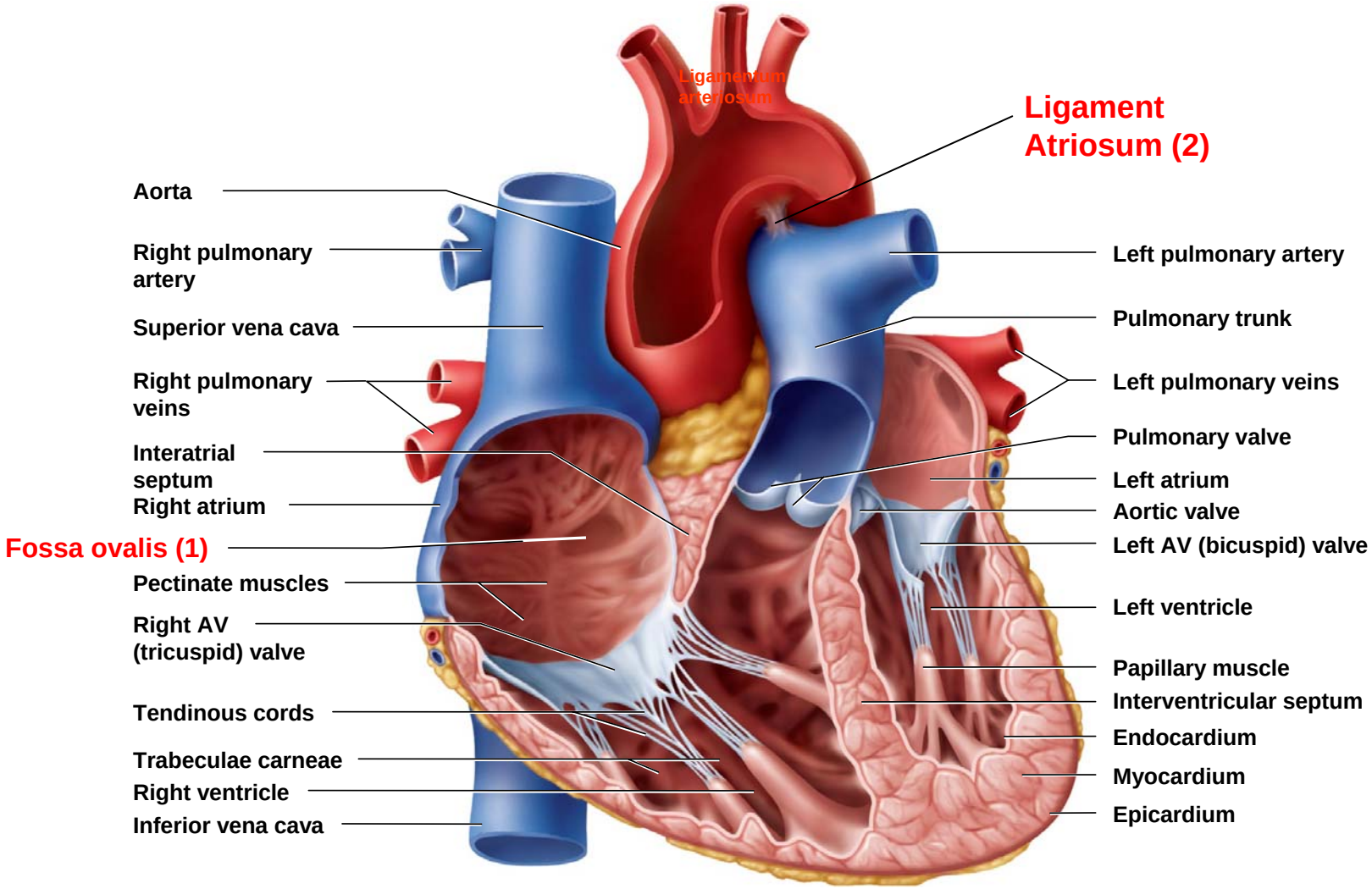

(Notes: (1) foramine ovalis / (2) Dutus Atriosum / fetal structures to redirect blood into systemic circulation)

Heart Chambers – Internal Structures

- interatrial septum
  - wall that separates atria
- pectinate muscles
  - internal ridges of myocardium in right atrium and both auricles
- interventricular septum
  - muscular wall that separates ventricles
- trabeculae carneae
  - internal ridges in both ventricles

Internal Anatomy - Anterior

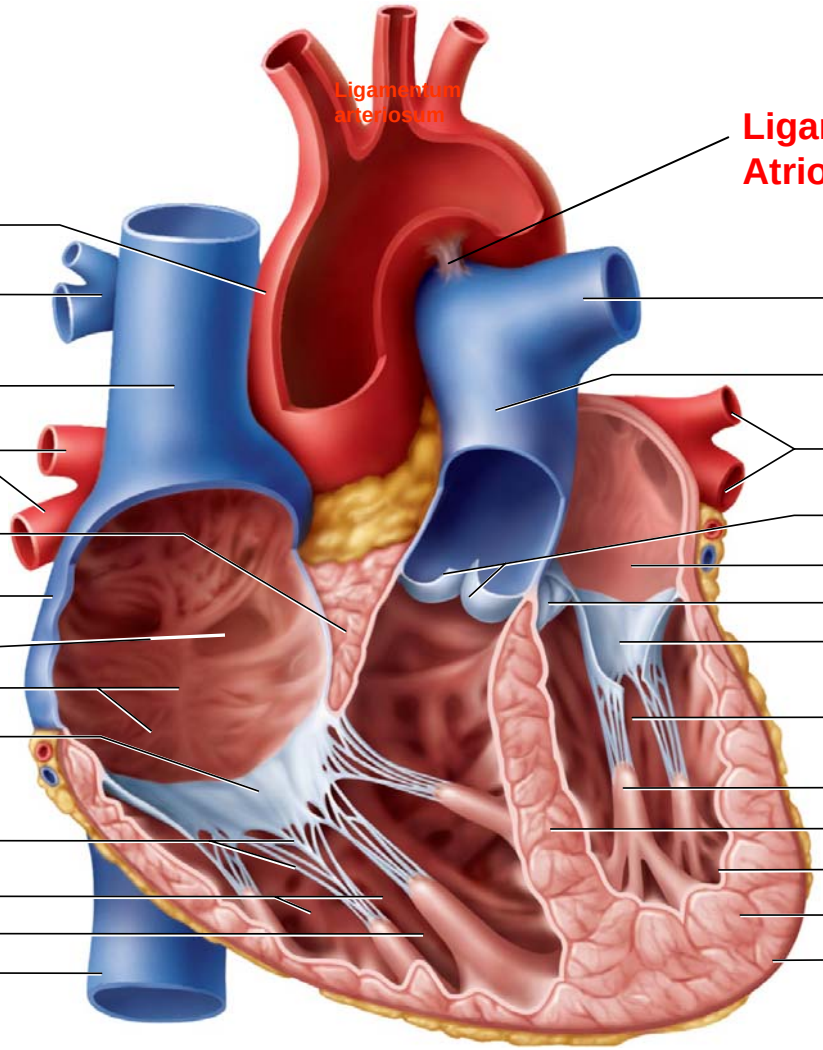

(Notes: (1) foramine ovalis / (2) Dutus Atriosum / fetal structures to redirect blood into systemic circulation)

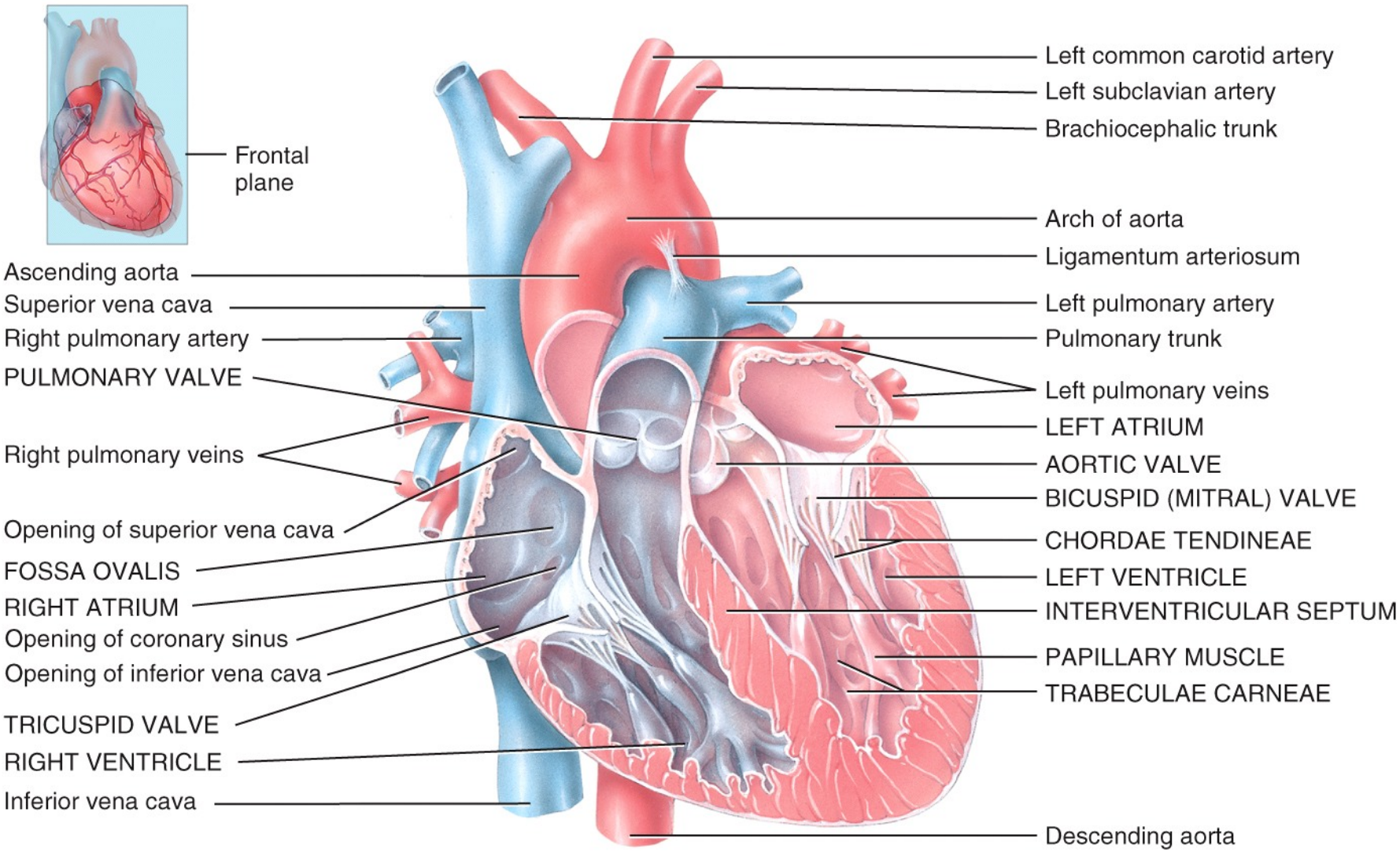

(a) Anterior view of frontal section showing internal anatomy

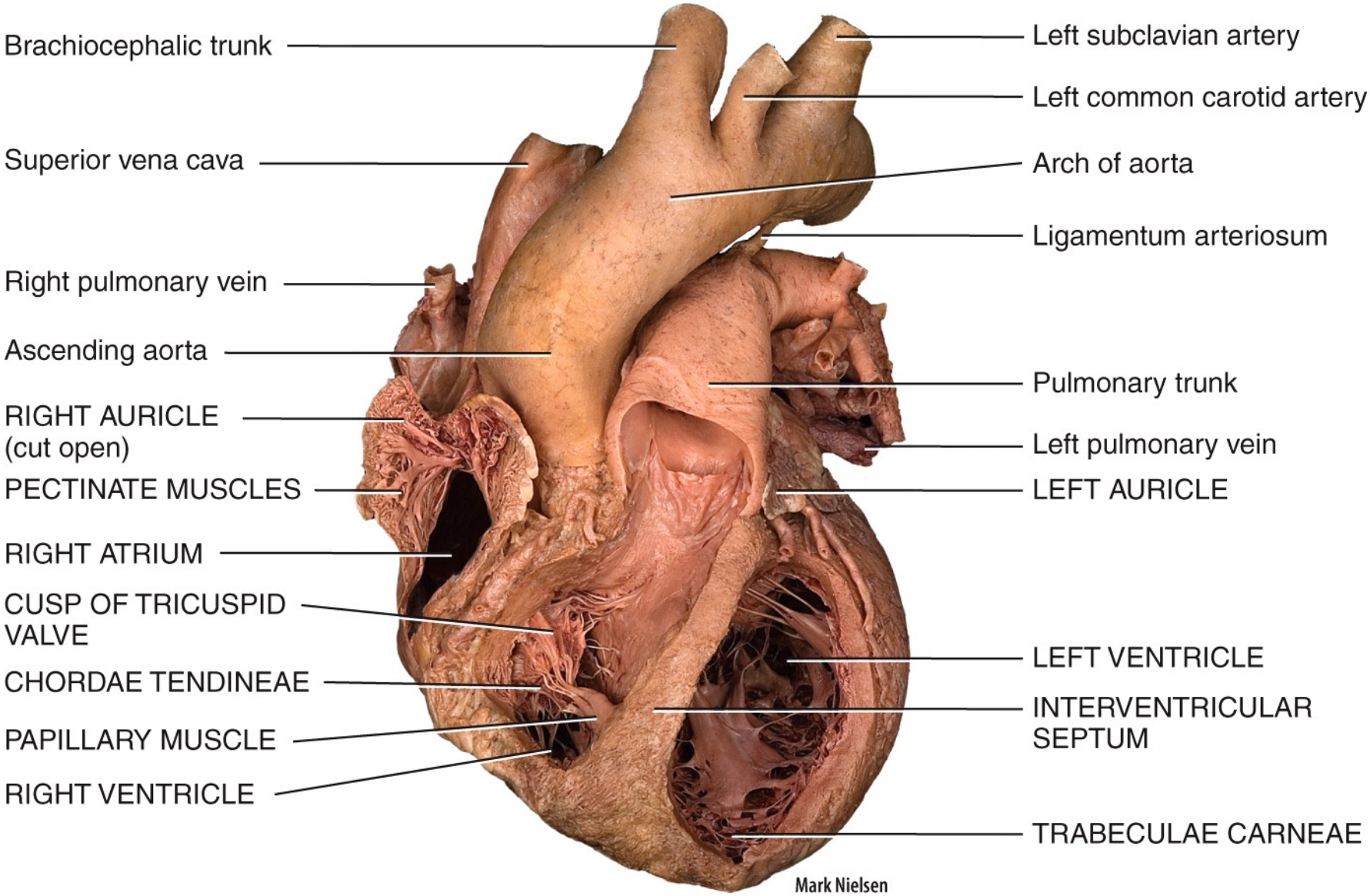

(b) Anterior view of partially sectioned heart

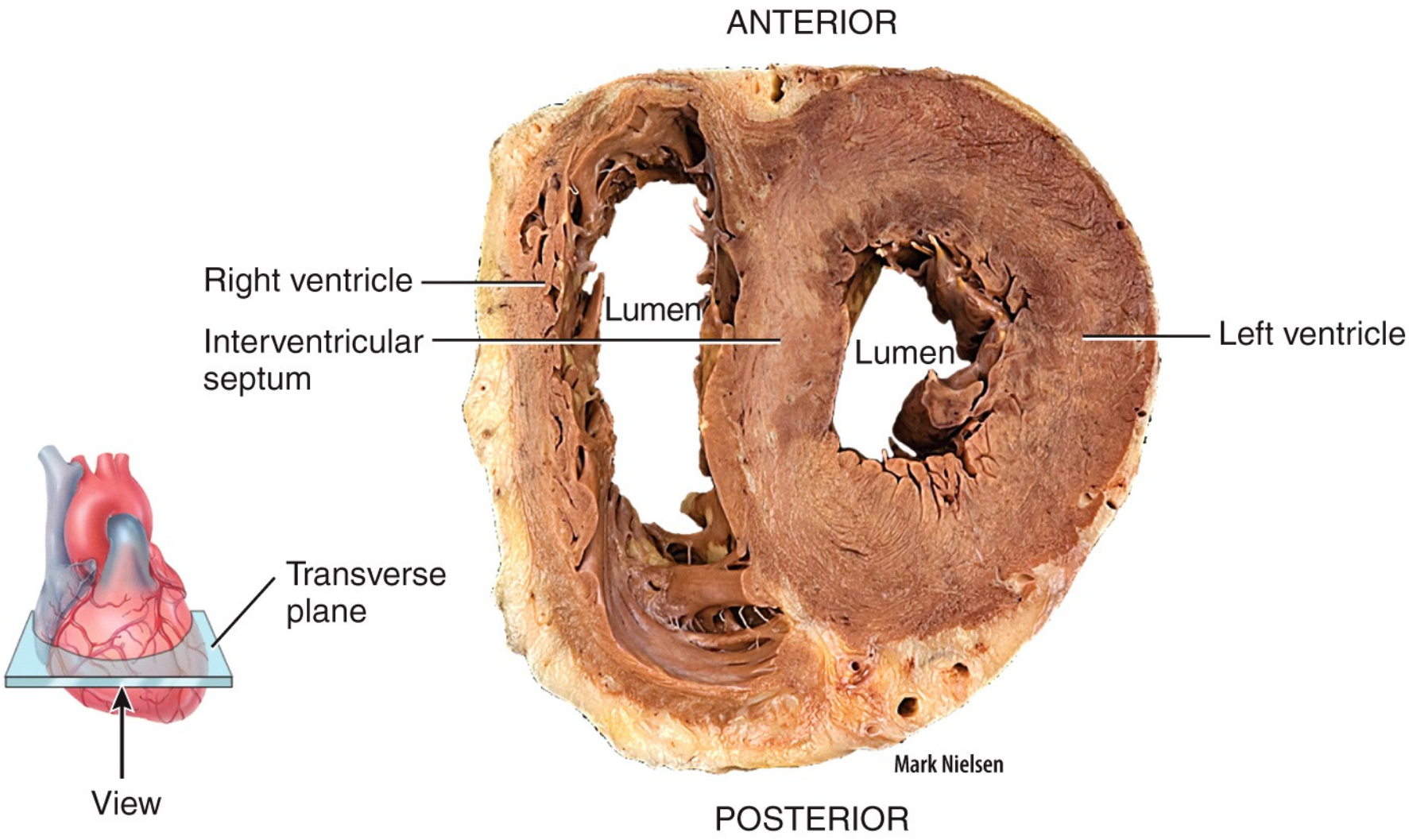

(c) Inferior view of transverse section showing differences in thickness of ventricular walls

Heart Valves

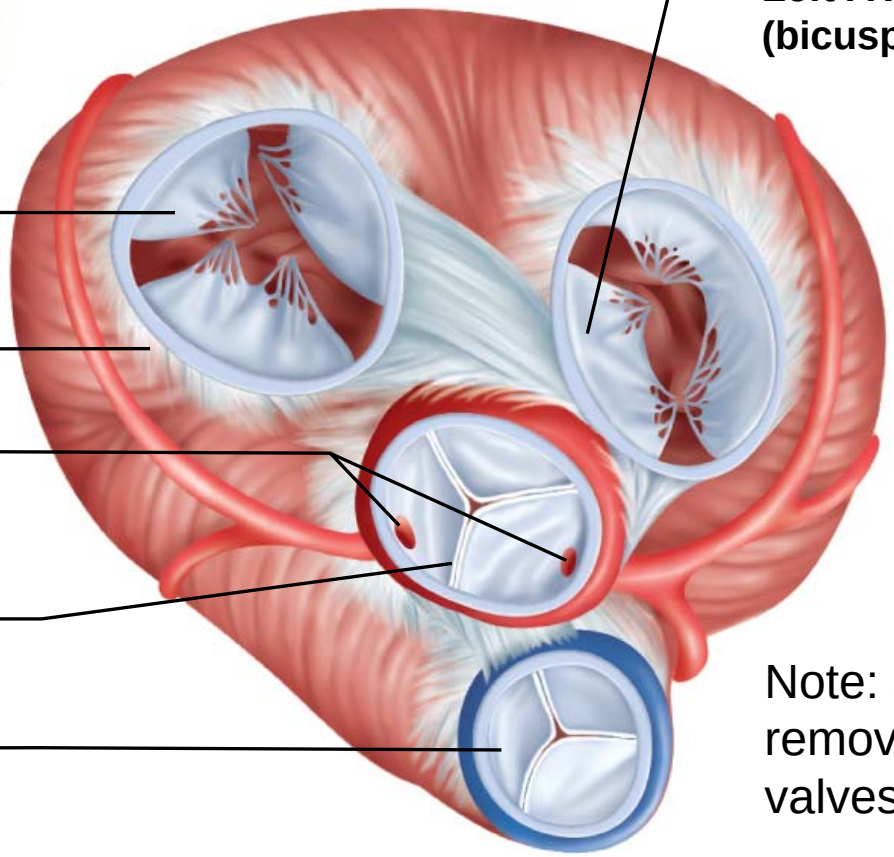

Note: atria have been removed to show AV valves

Note: all valves are “built” into the atrioventricular septum / it is a strong connective tissue transverse plane / this also prevents action potentials from moving into ventricles via gap junctions

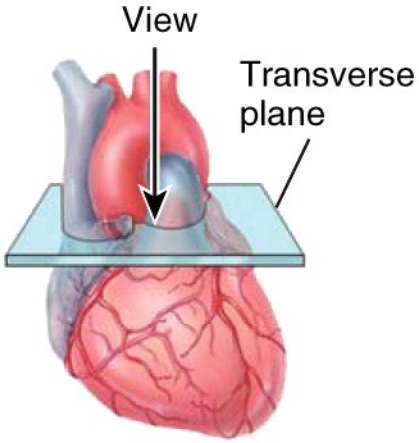

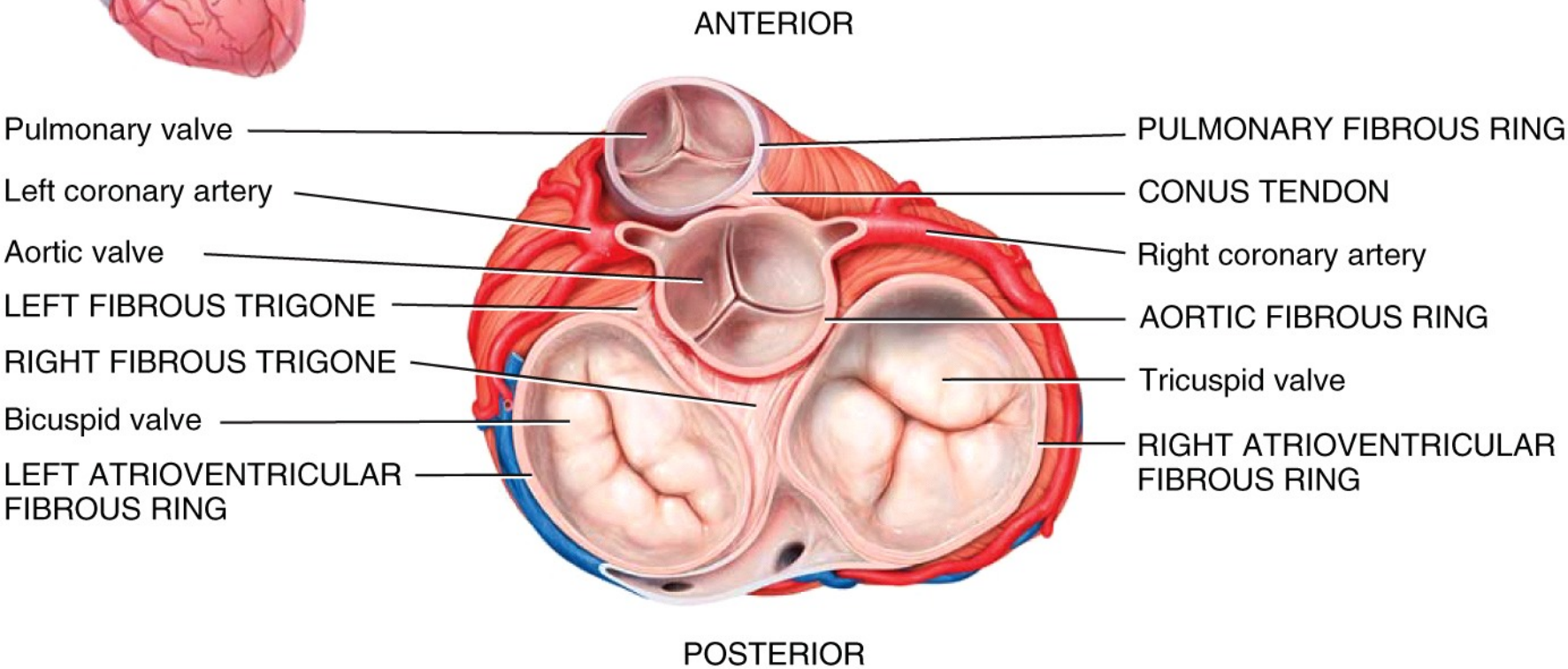

Superior view (the atria have been removed)

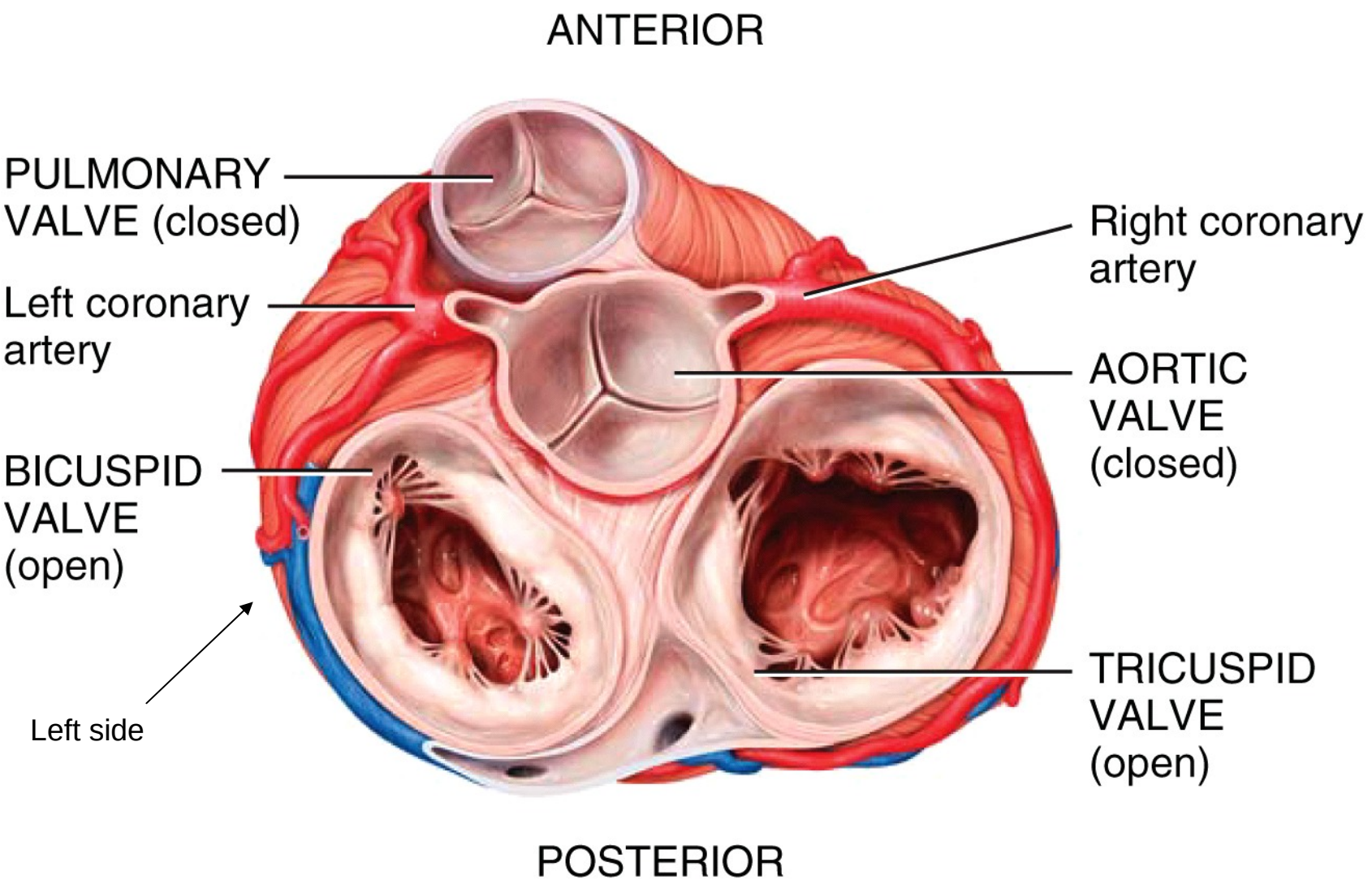

(d) Superior view with atria removed: pulmonary and aortic valves closed, bicuspid and tricuspid valves open

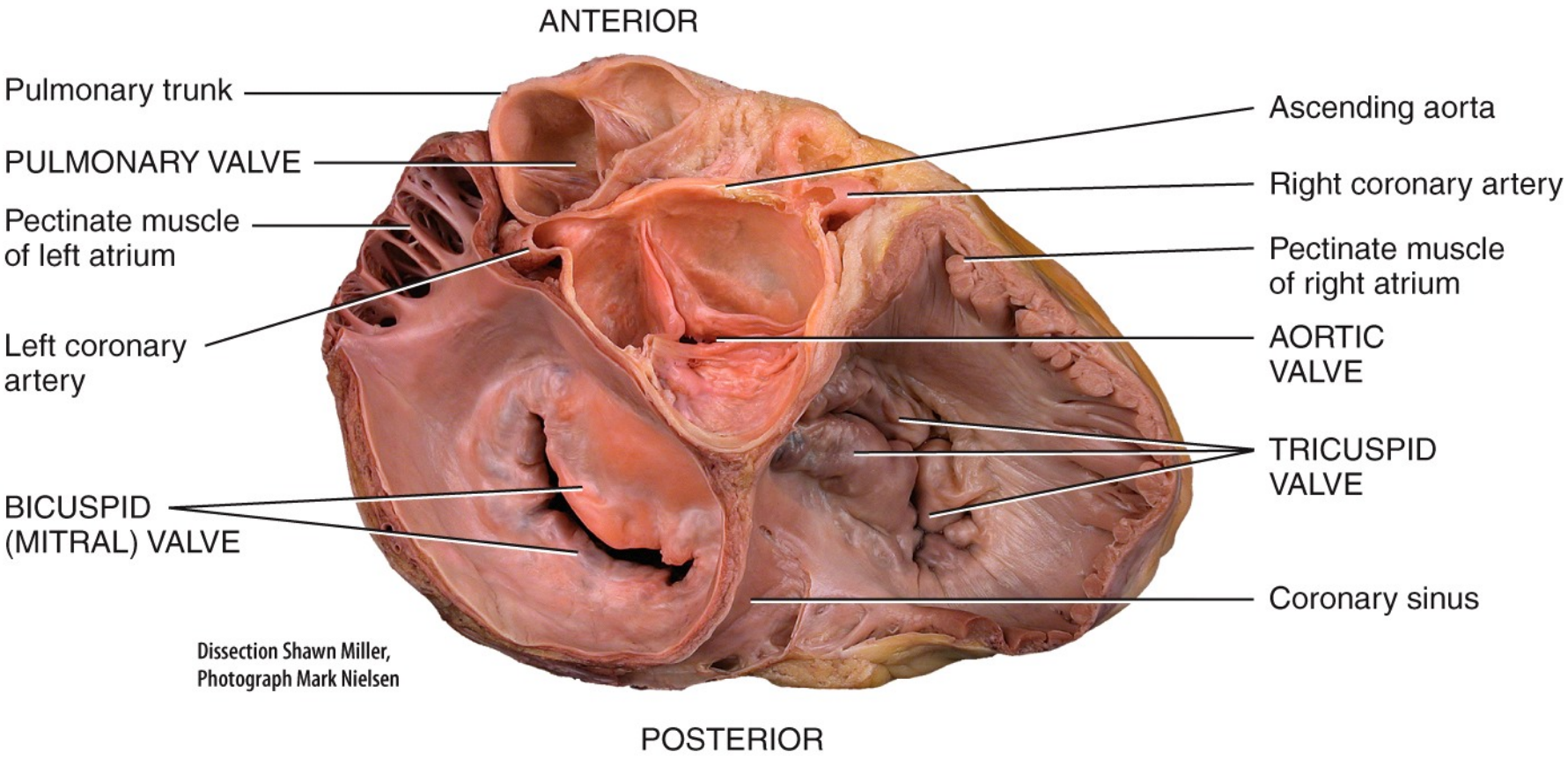

(f) Superior view of atrioventricular and semilunar valves

Heart Valve Functions / Atrioventricular

- controls blood flow between atria and ventricles
- Valves open and close due to blood pressure between chambers guarded by valves
- right AV valve has 3 cusps (tricuspid valve)
- left AV valve has 2 cusps (mitral or bicuspid valve)
- chordae tendineae – connective tissue fibers that connect AV valves to papillary muscles on floor of ventricles
- papillary muscles prevent AV valves from flipping inside out or bulging into the atria when the ventricles contract

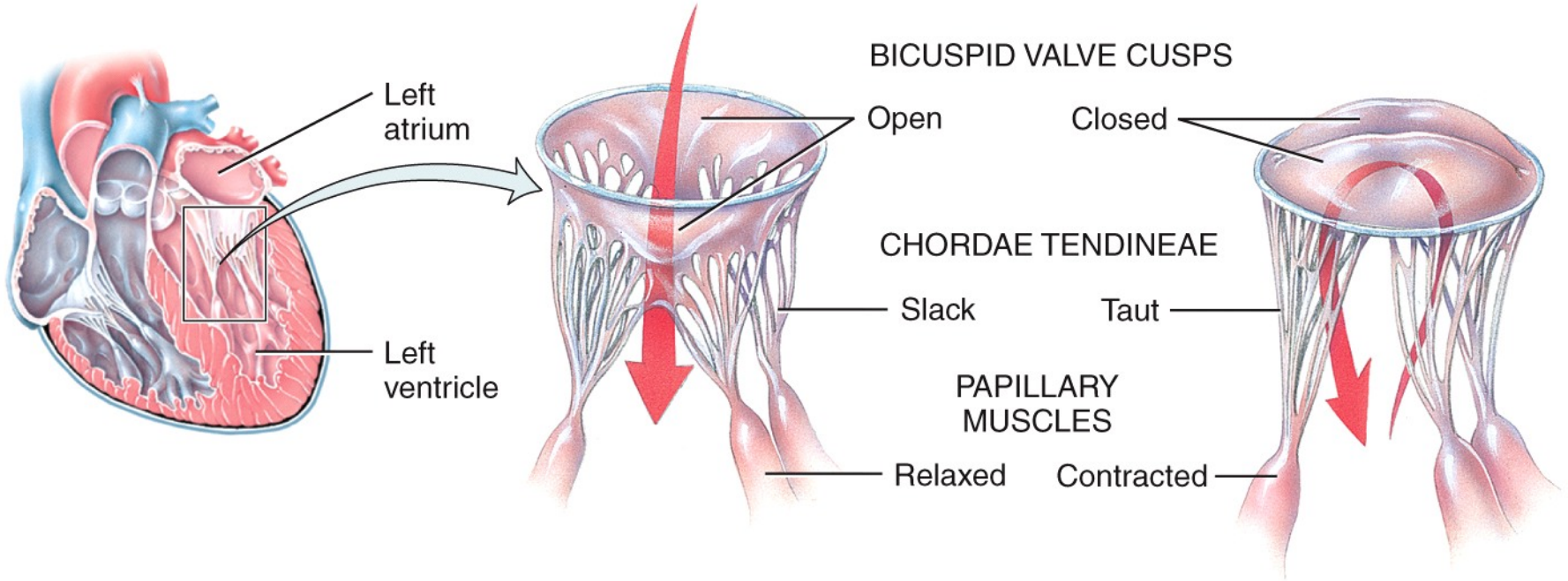

(a) Bicuspid valve open

(b) Bicuspid valve closed

AV Valve Mechanics

- When ventricles relax
  - pressure drops inside the ventricles
  - semilunar valves close as blood attempts to back up into the ventricles from the vessels
  - AV valves open
  - blood flows from atria to ventricles
- When ventricles contract
  - AV valves close as blood attempts to back up into the atria
  - pressure rises inside of the ventricles
  - semilunar valves open and blood flows into great vessels

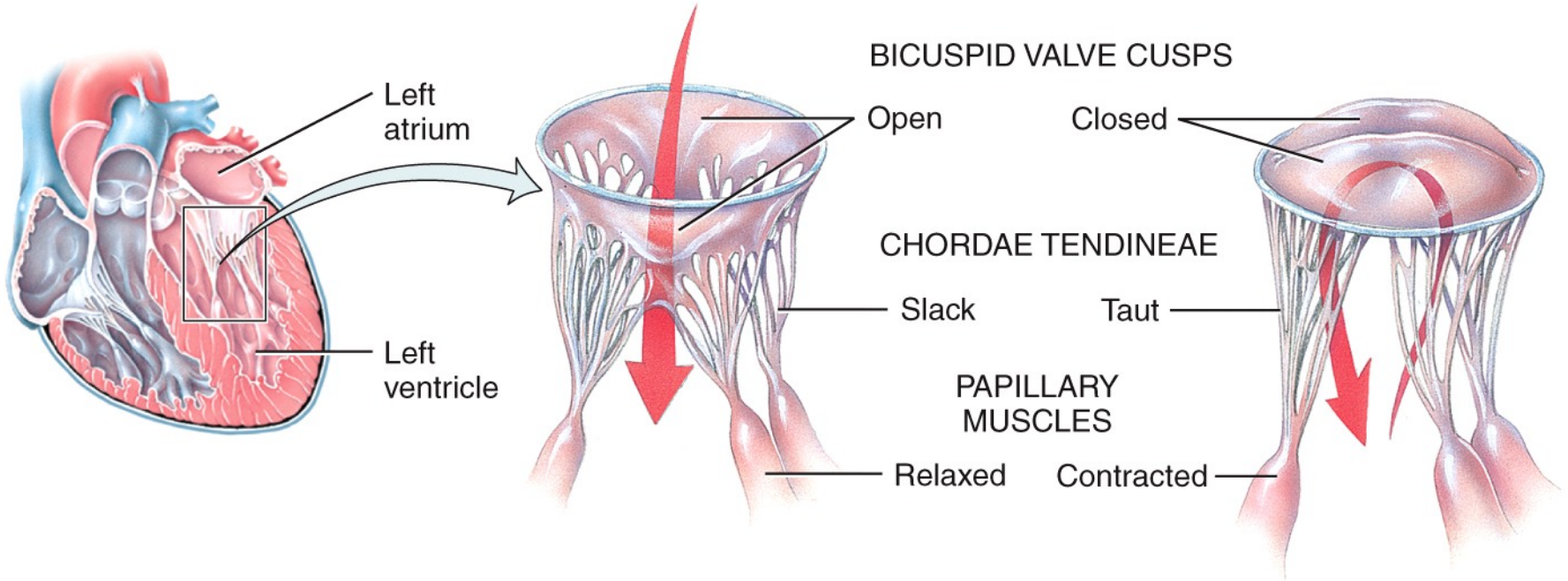

(a) Bicuspid valve open

(b) Bicuspid valve closed

Dissection Shawn Miller, Photograph Mark Nielsen

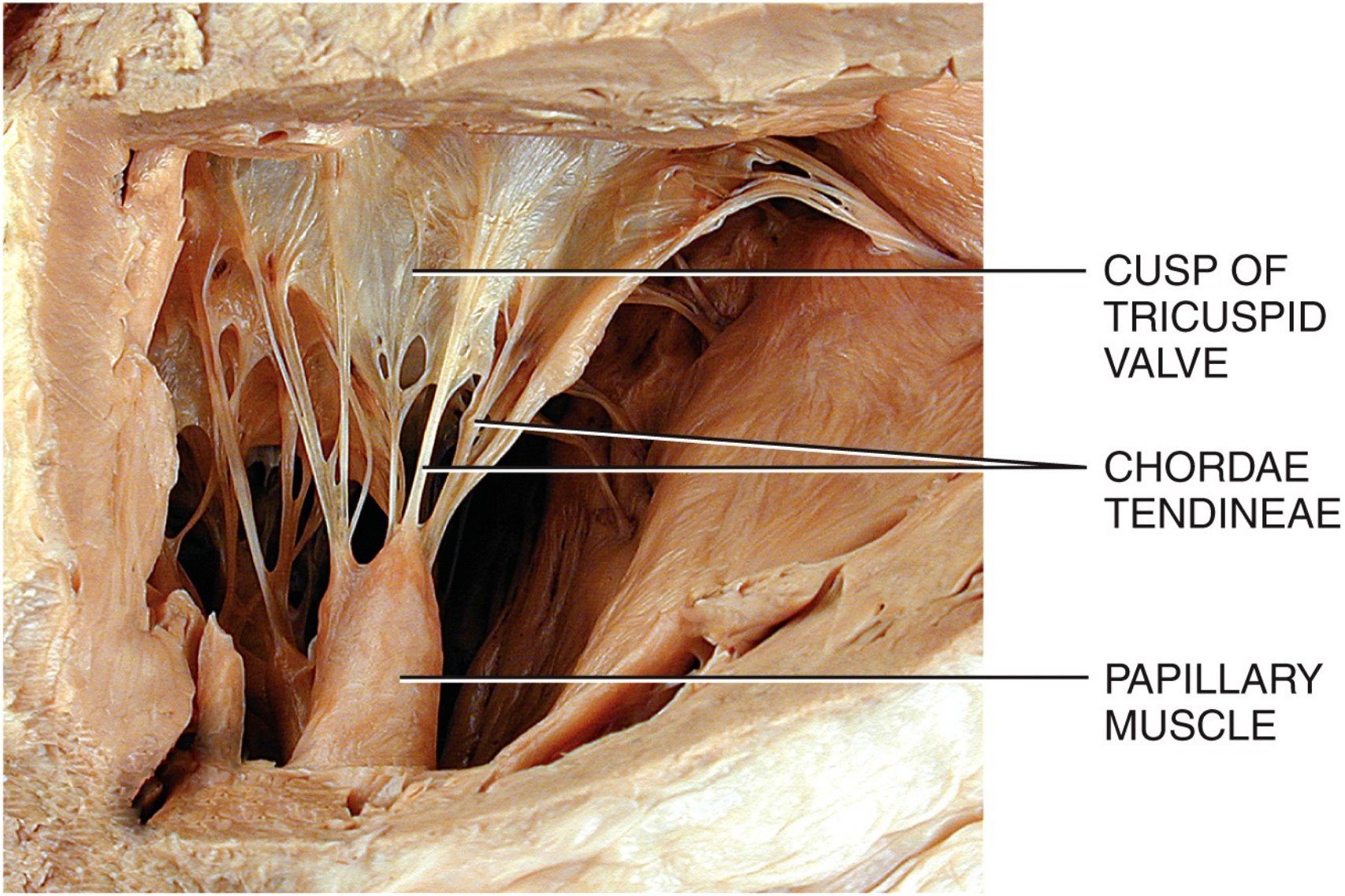

(c) Tricuspid valve open

Heart Valves / AV Valves

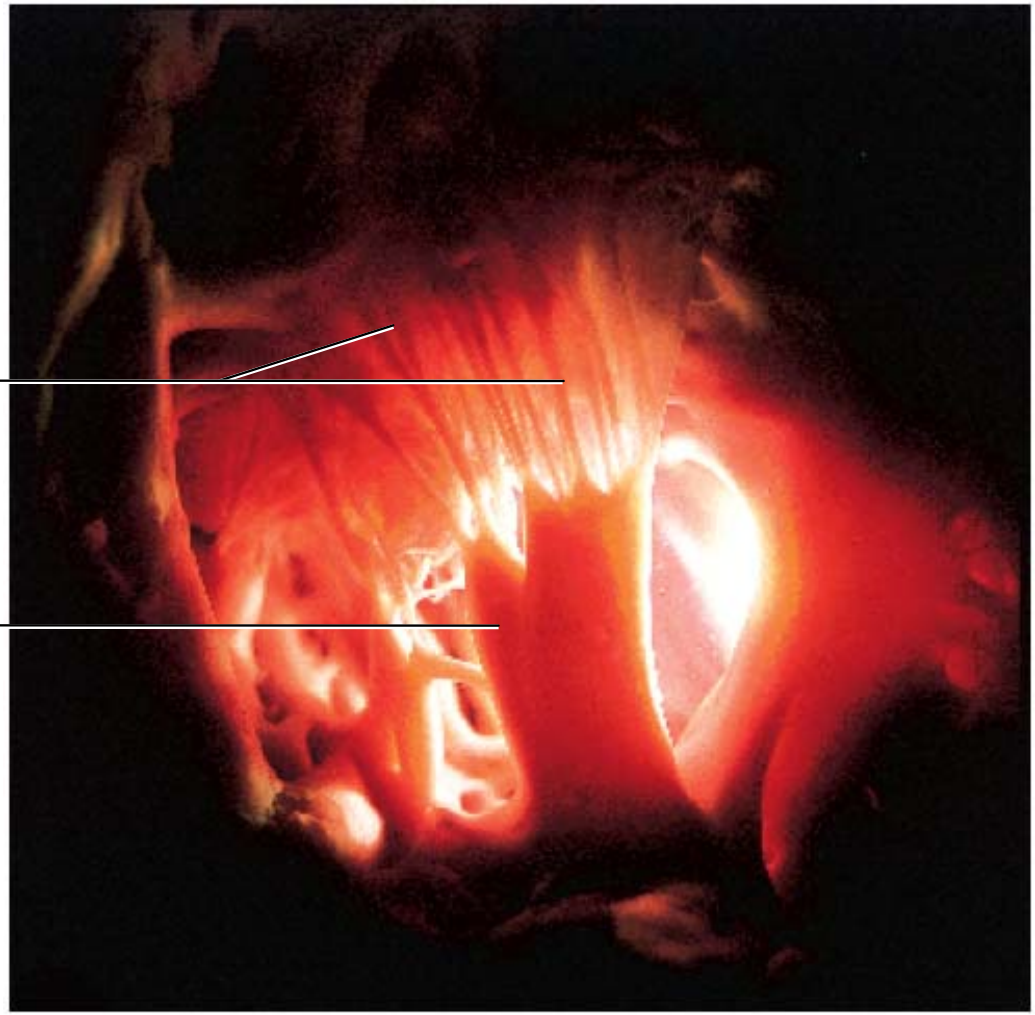

Heart Valve Function / Semilunar

- control flow into pulmonary truck and aorta // the great arteries of the heart
- these valves open and close because of blood flow and pressure
- pulmonary semilunar valve // between right ventricle and pulmonary trunk
- aortic semilunar valve // between left ventricle and aorta
- semilunar valves do not have chordae tenineae
- cusps of valves close as ventricles relax and blood starts to flow back towards ventricles // backflow of blood fill cusps which cause them to close

Endoscopic View of Semi Lunar Heart Valve

Dissection Shawn Miller, Photograph Mark Nielsen

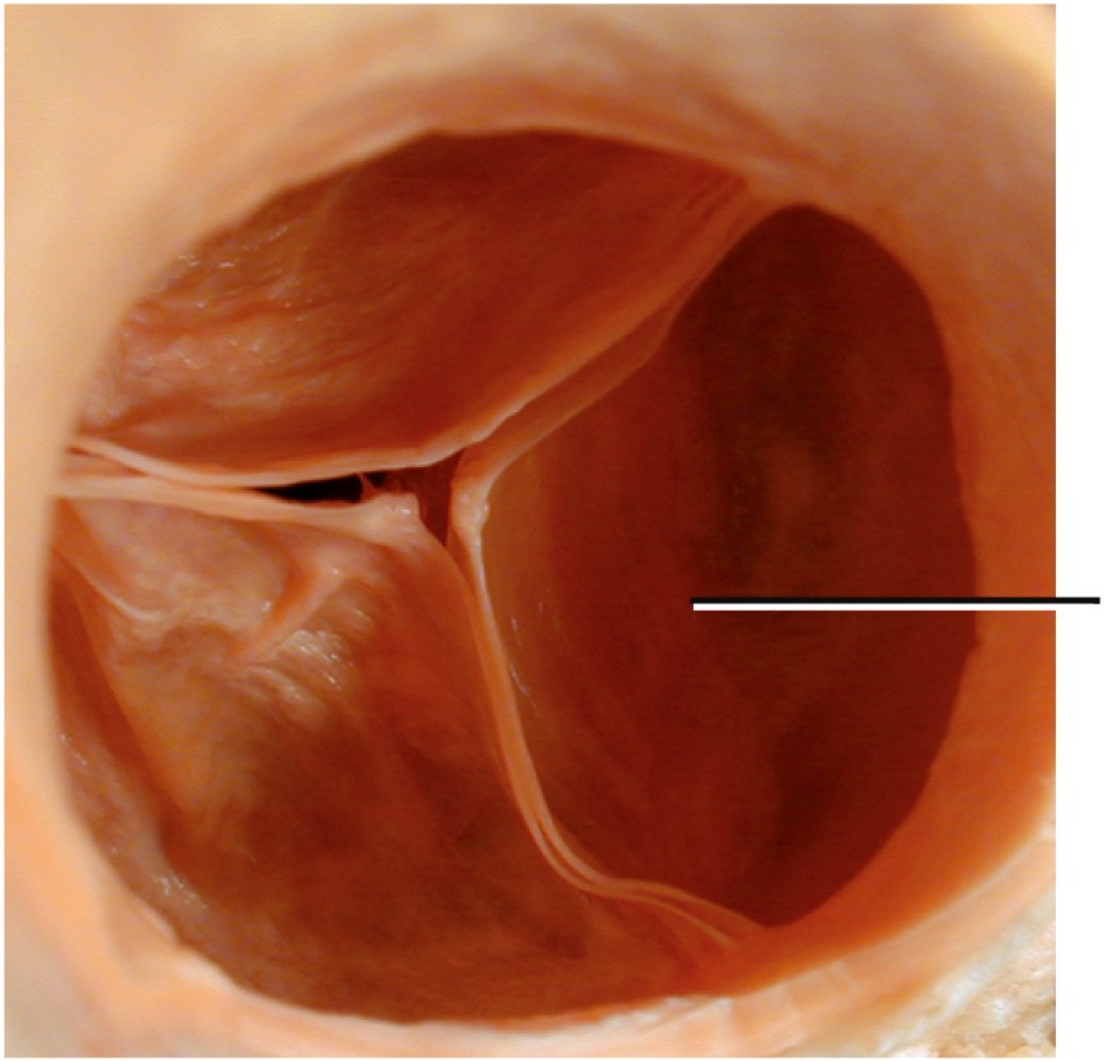

No papillary muscles or cordae tendinae

(g) Superior view of aortic valve

Function of Heart Valves

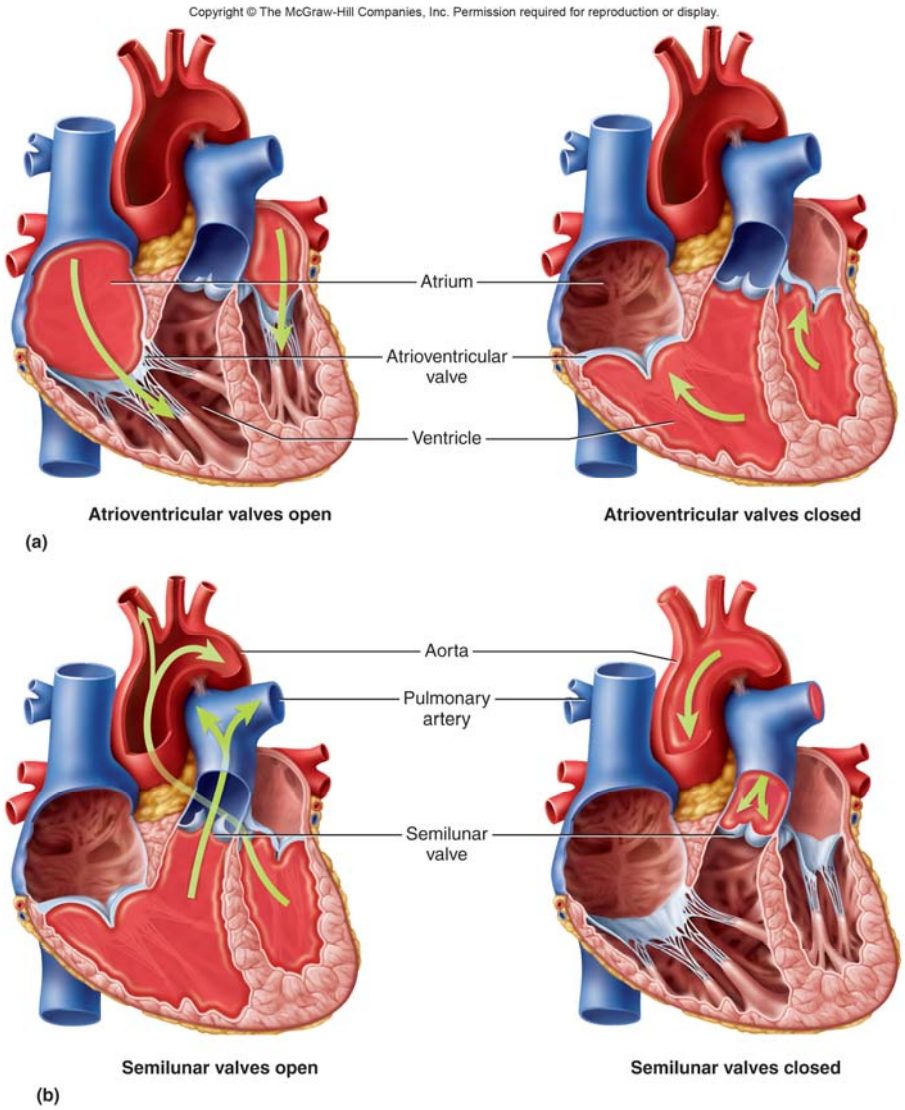

- Valves ensure a one-way flow of blood through the heart
- Blood flows from an area of high pressure to an area of low pressure
- The pressure difference across the valve open and close these valves