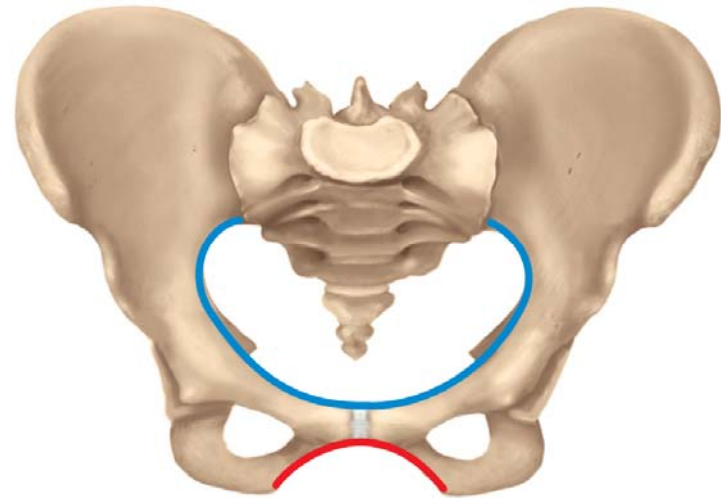
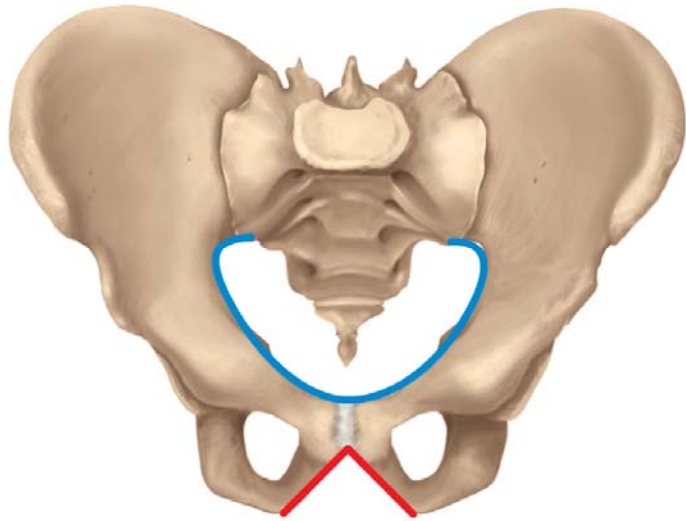


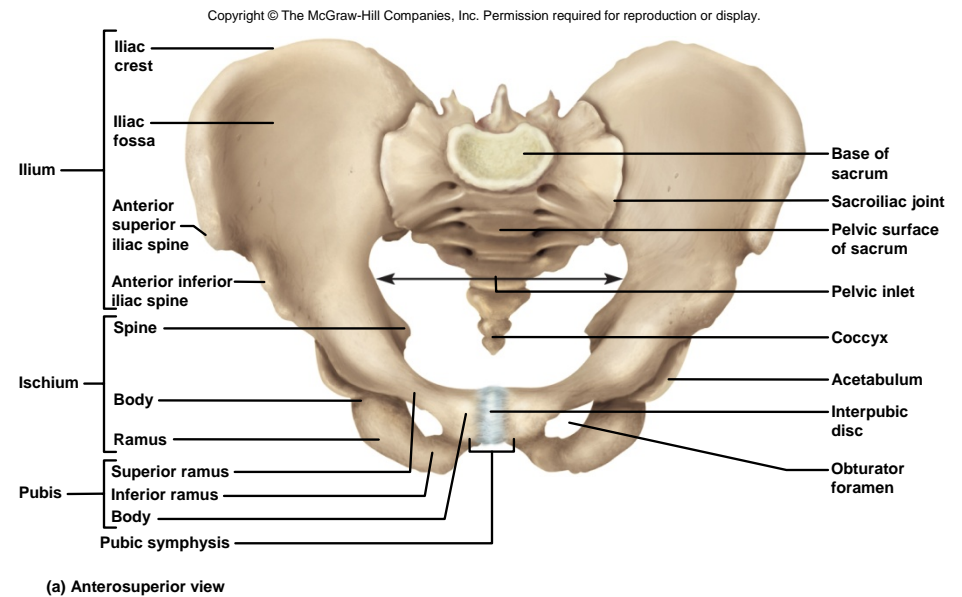
Chapter 8

Pelvic Girdle & Lower Limb



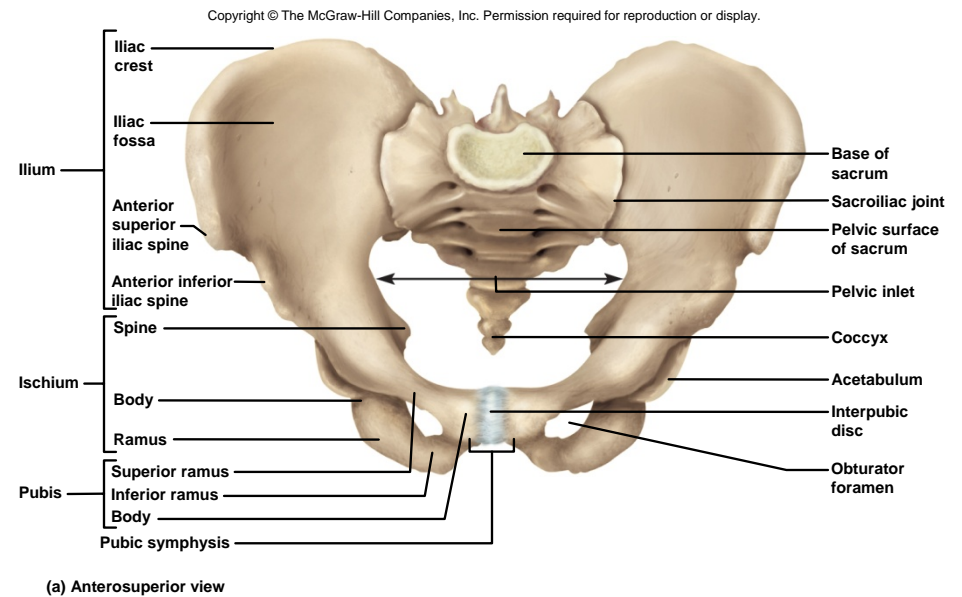
- pelvic girdle – consists of a complete ring composed of three bones
 - two hip (coxal) bones // also called ossa coxae or innominate bones
 - sacrum that is also part of the vertebral column
- pelvis – bowl-shaped structure composed of the two coxal bones and sacrum as well as their ligaments and muscles that line the pelvic cavity and form its floor
 - supports trunk on the lower limbs and protects viscera, lower colon, urinary bladder, and internal reproductive organs

Pelvic Girdle

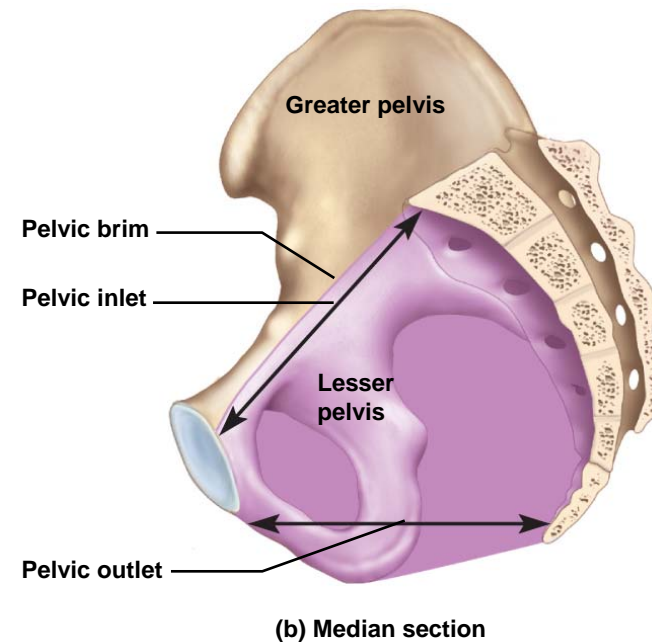
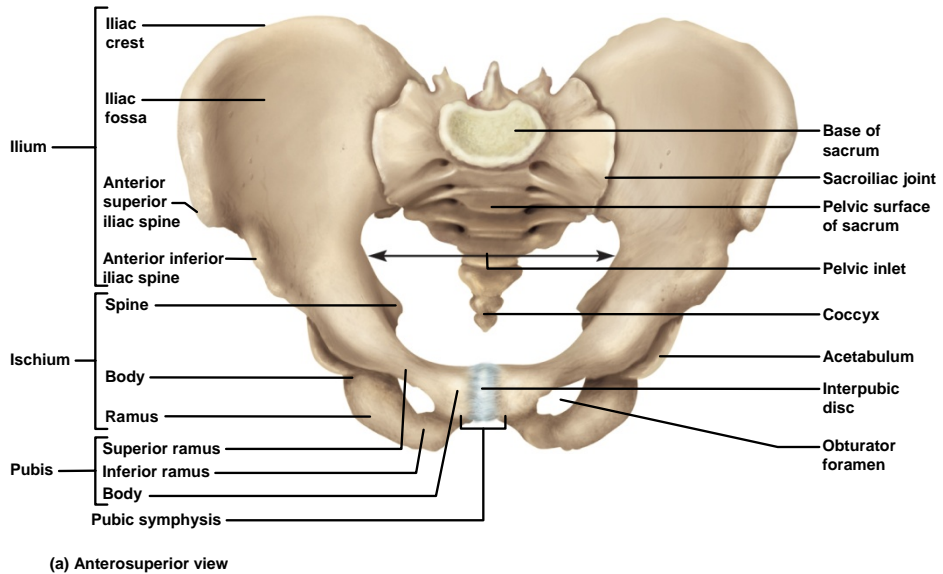


Pelvic Girdle

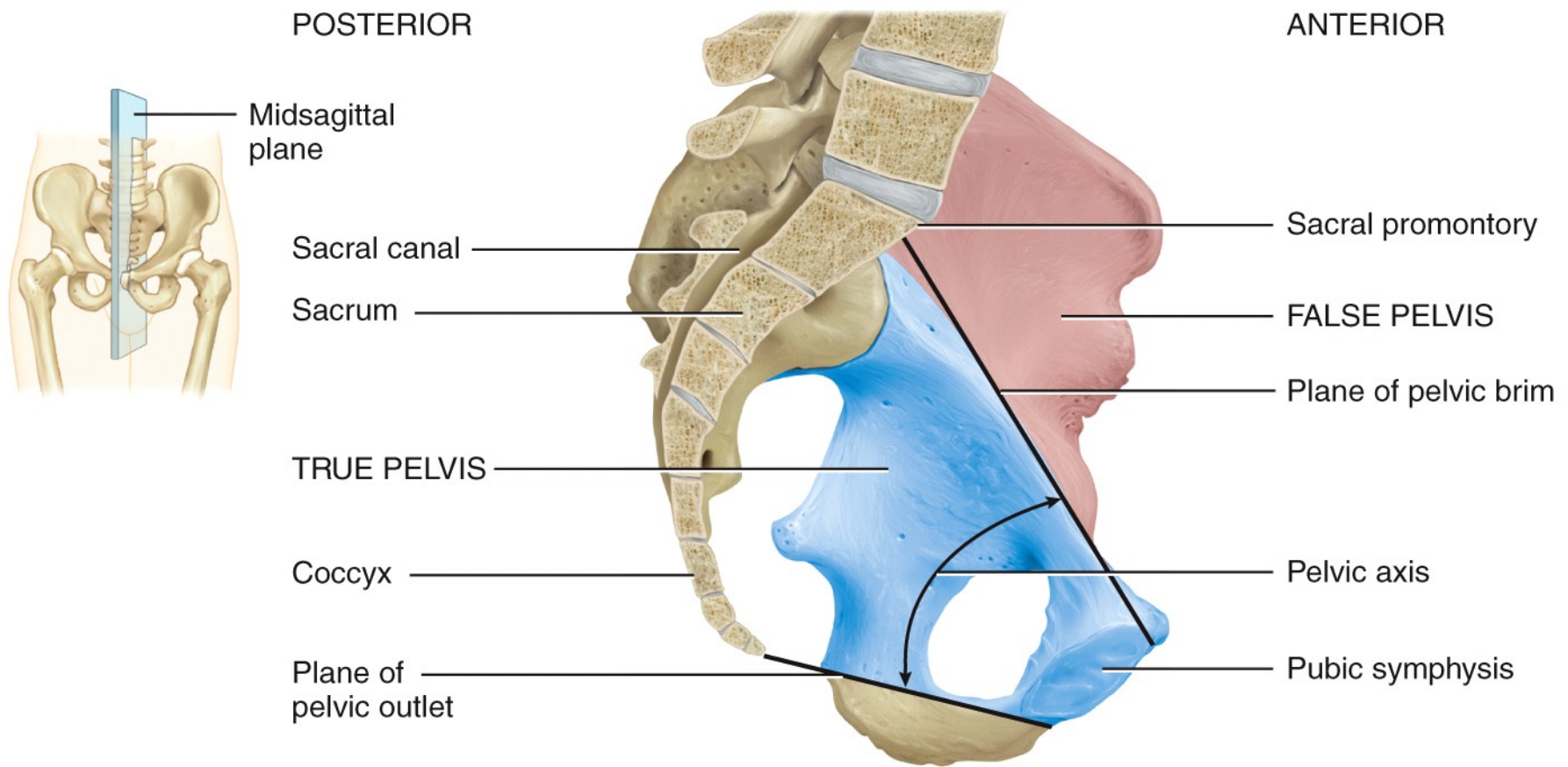
- **sacroiliac joint** - joins hipbone to the vertebral column
 - **auricular surface** of ileum to **auricular surface** of sacrum
- anteriorly, **interpubic disc** – pad of fibrocartilage joins pubic bones
- **pubic symphysis** – the interpubic disc and adjacent regions of the pubic bone on each side



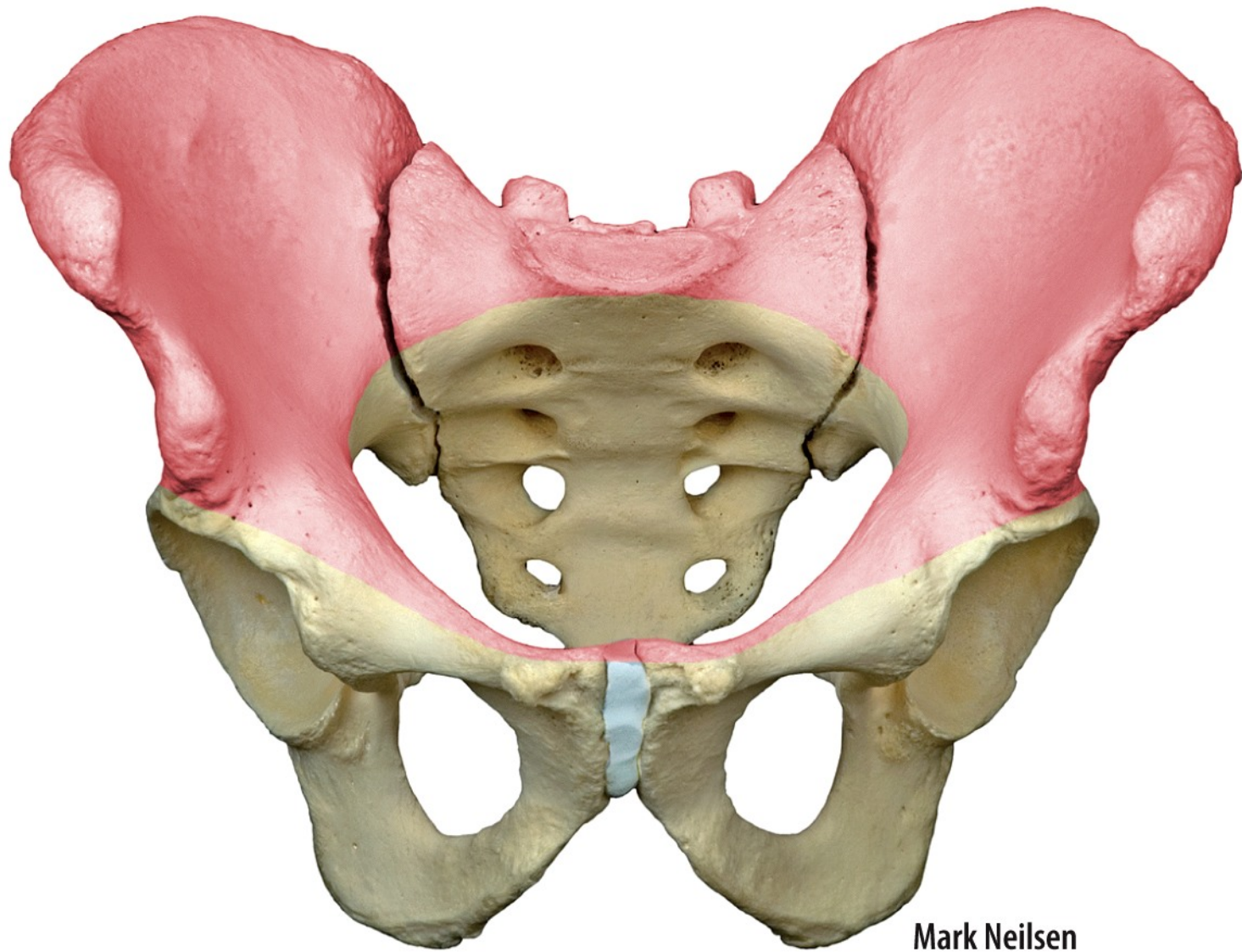
Pelvic Inlet and Outlet



- **greater (false) pelvis** – between flare of the hips
- **lesser (true) pelvis** – narrower and below
- **pelvic brim** – round margin that separates the two
- **pelvic inlet** – opening circumscribed by brim that infant's head must pass during birth

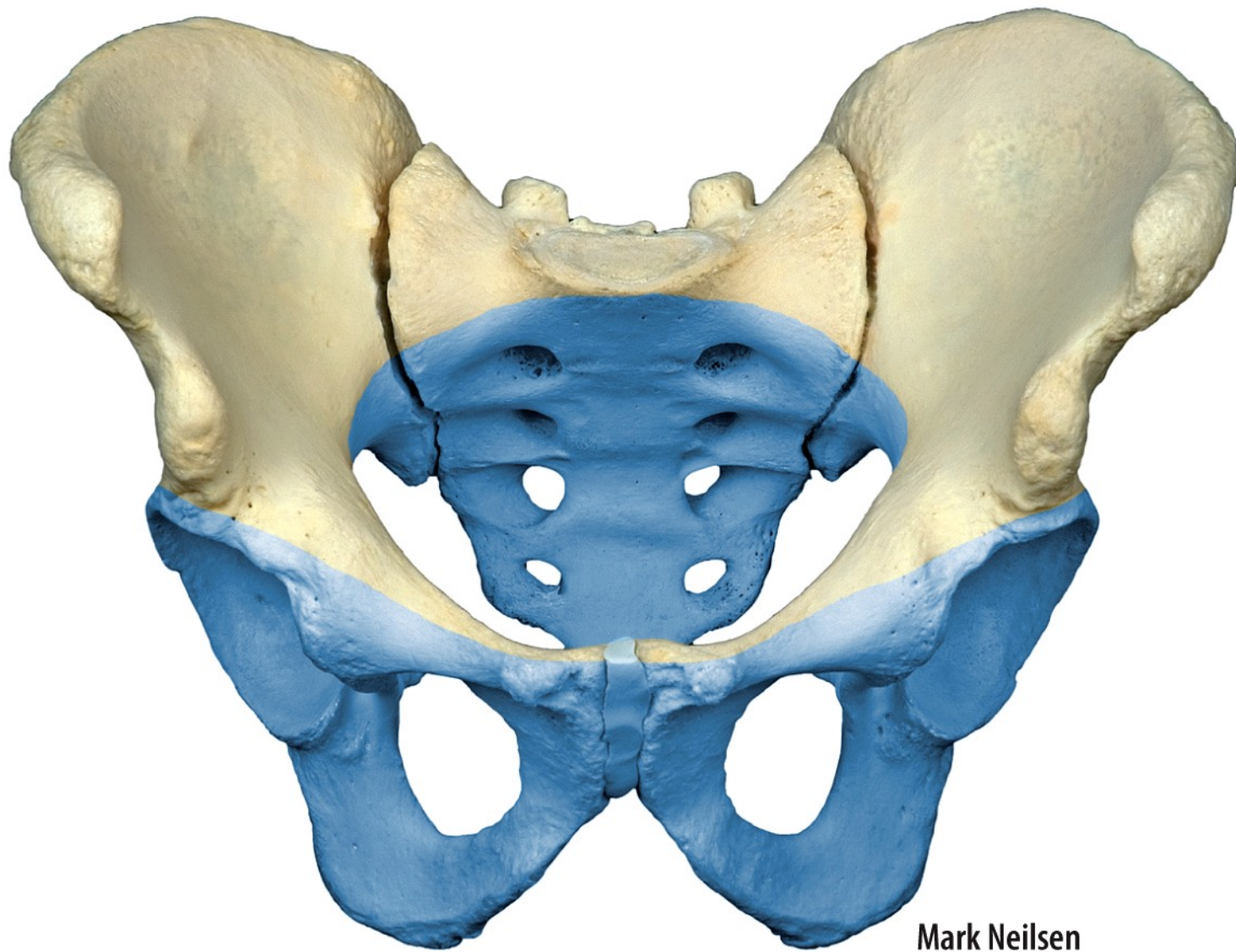


(b) Midsagittal section indicating locations of true and false pelvis



Mark Neilsen

(c) Anterosuperior view of false pelvis (pink)



Mark Neilsen

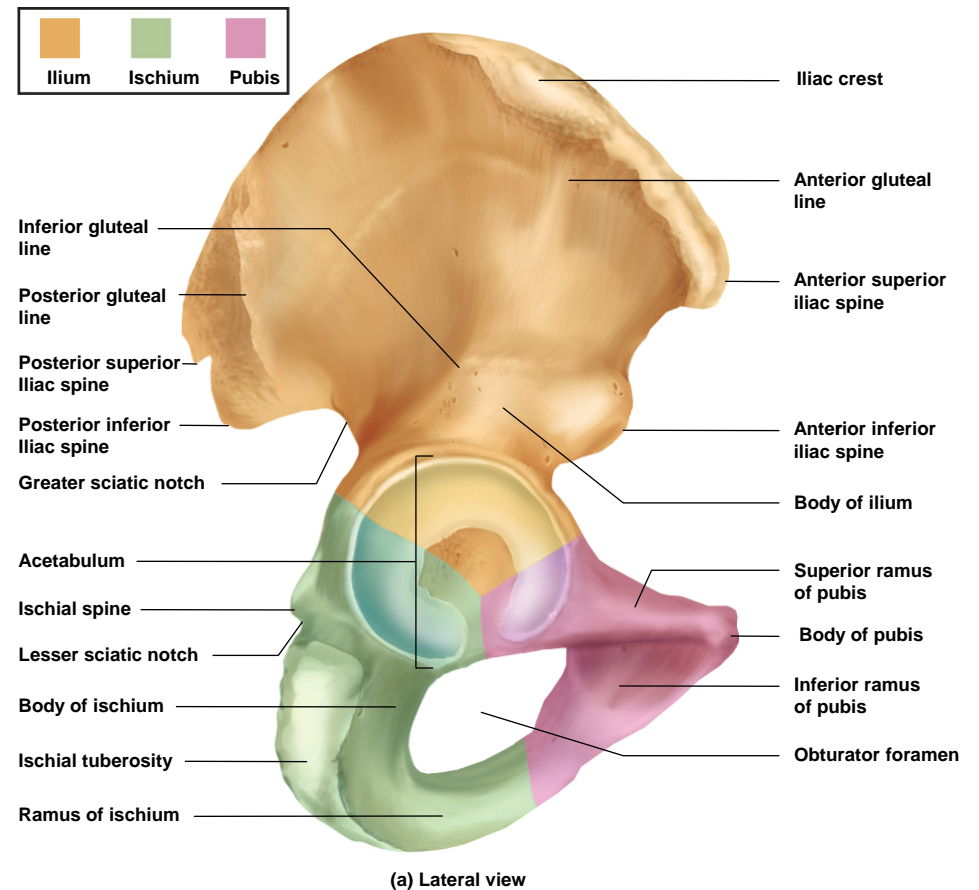
(d) Anterosuperior view of true pelvis (blue)

Hip Bone

- three distinct features of hip bone

- **iliac crest** – superior crest of hip
- **acetabulum** – the hip socket
- **obturator foramen** – large hole below acetabulum

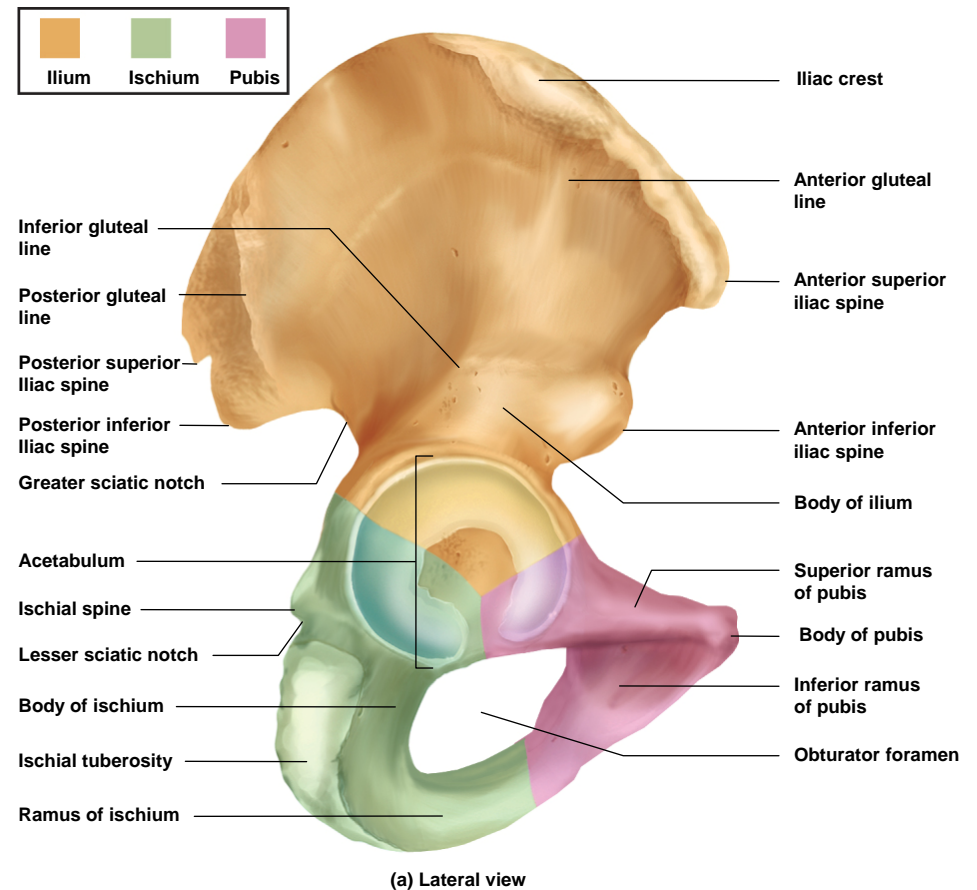
Copyright © The McGraw-Hill Companies, Inc. Permission required for reproduction or display.



- each adult hip bone is formed by the fusion of three childhood bones
 - Ilium // the largest
 - extends from the iliac crest to the center of the acetabulum
 - anterior and posterior superior spine
 - anterior and posterior inferior spines
 - greater sciatic notch and iliac fossa
 - Ischium // inferioposterior portion of hip
 - heavy body with prominent spine
 - lesser sciatic notch
 - ischial tuberosity
 - Ramus
 - pubis (pubic bone) // most anterior portion of the hip bone // body, superior and inferior ramus

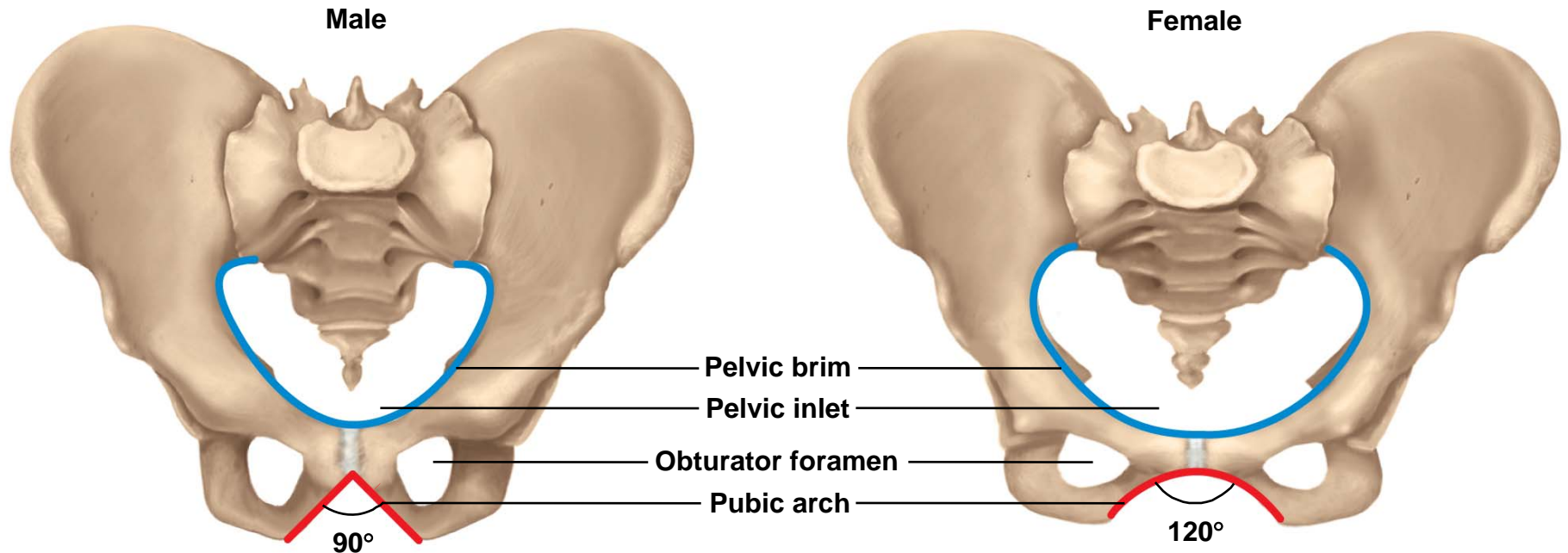
Hip Bone

Copyright © The McGraw-Hill Companies, Inc. Permission required for reproduction or display.



Comparison of Male and Female

Copyright © The McGraw-Hill Companies, Inc. Permission required for reproduction or display.

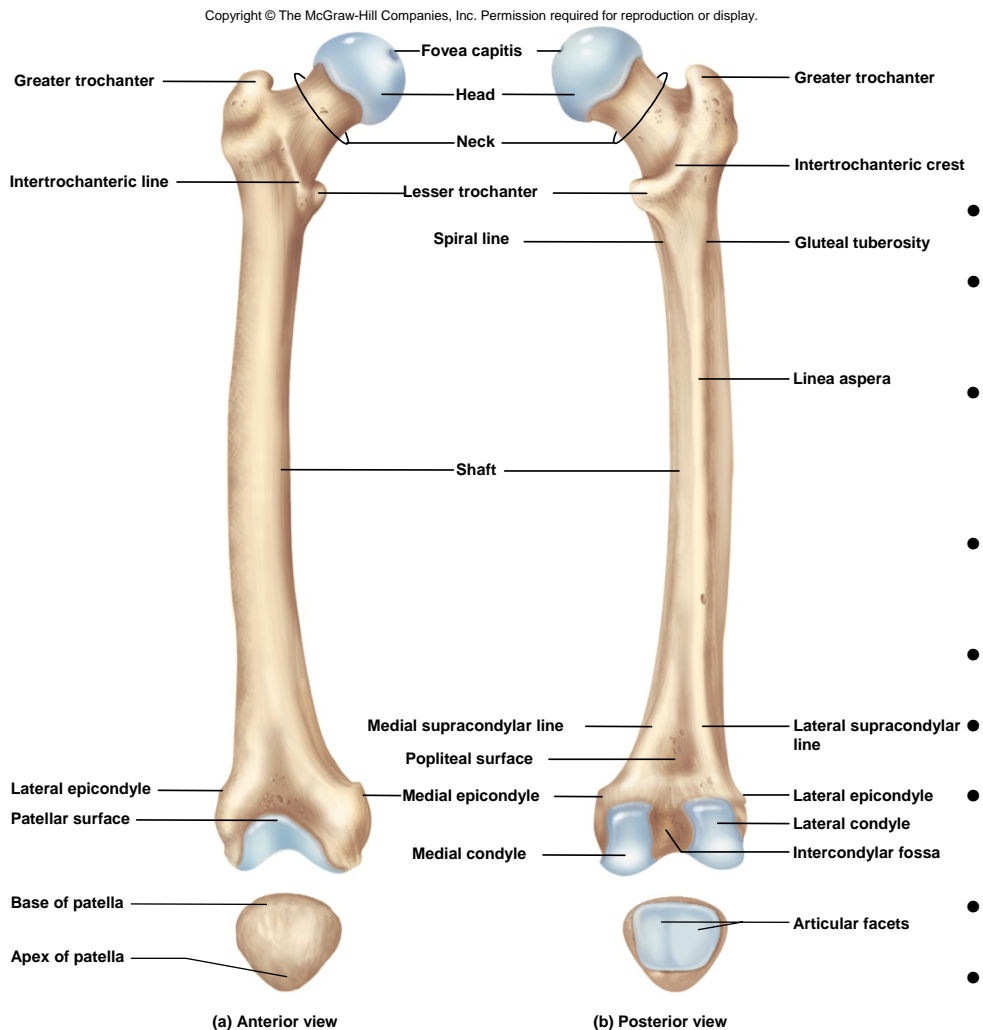


- male - heavier and thicker due to forces exerted by stronger muscles
- female - wider and shallower, and adapted to the needs of pregnancy and childbirth, larger pelvic inlet and outlet for passage of infant's head

Lower Limb

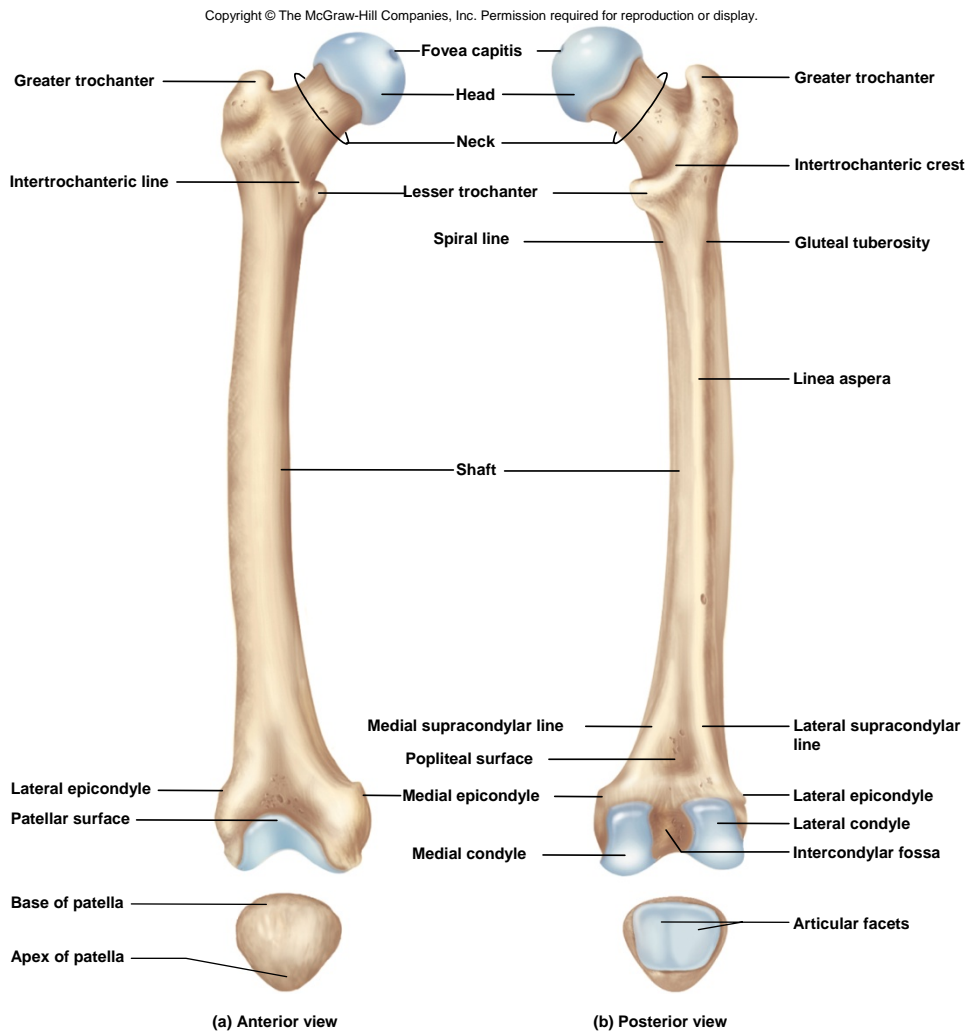
- lower limb divided into **four regions** containing **30 bones** per limb
 - **femoral region** (thigh) – extends from hip to knee region // contains the **femur** and **patella**
 - **crural region** (leg proper) – extends from knee to ankle // contains medial **tibia** and lateral **fibula**
 - **tarsal region** (tarsus) – ankle – the union of the crural region with the foot // tarsal bones are considered part of the foot
 - **pedal region** (pes) – foot // composed of 7 tarsal bones, 5 metatarsals, and 14 phalanges in the toes

Femur



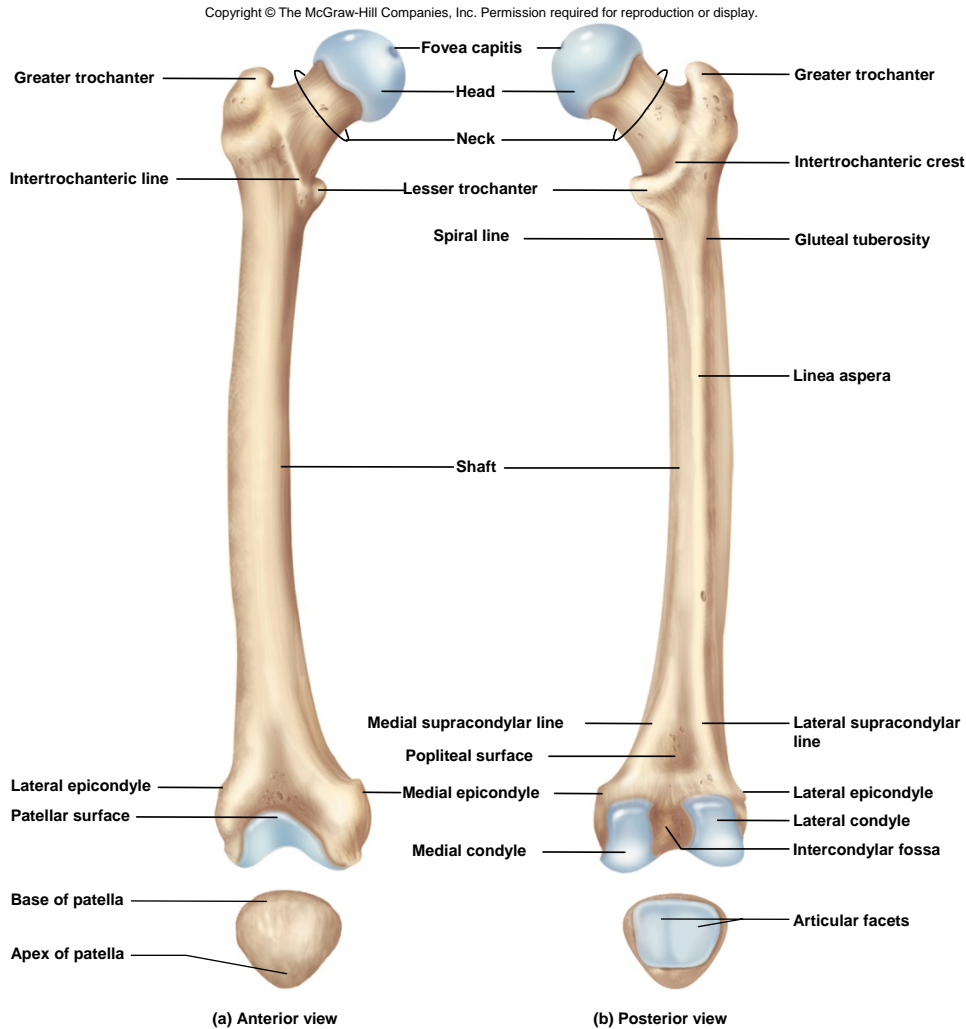
- longest and strongest bone of the body
- hemispherical **head** that articulates with the acetabulum of the pelvis
 - forms ball-and-socket joint
 - **fovea capitis** – pit in head of femur for attachment of a ligament
- constricted **neck**
- **greater** and **lesser trochanters** for muscle attachment
- **intertrochanteric crest** – thick oblique ridge on the posterior surface that connects the trochanters
- **intertrochanteric line** – more delicate ridge on the anterior surface that connects trochanters
- **linea aspera** – ridge on posterior of the shaft
- **spiral (pectineal) line** and **gluteal tuberosity**
- **medial** and **lateral condyles** and **epicondyles** found distally
- **intercondylar fossa**
- **patellar** and **popliteal surface**

Patella (Kneecap)



- **patella** - triangular sesamoid bone embedded in tendon of the knee
- cartilaginous at birth // ossifies at 3 to 6 year
- **base** – broad, superior portion
- **apex** – pointed, inferior portion

Patella (Kneecap)

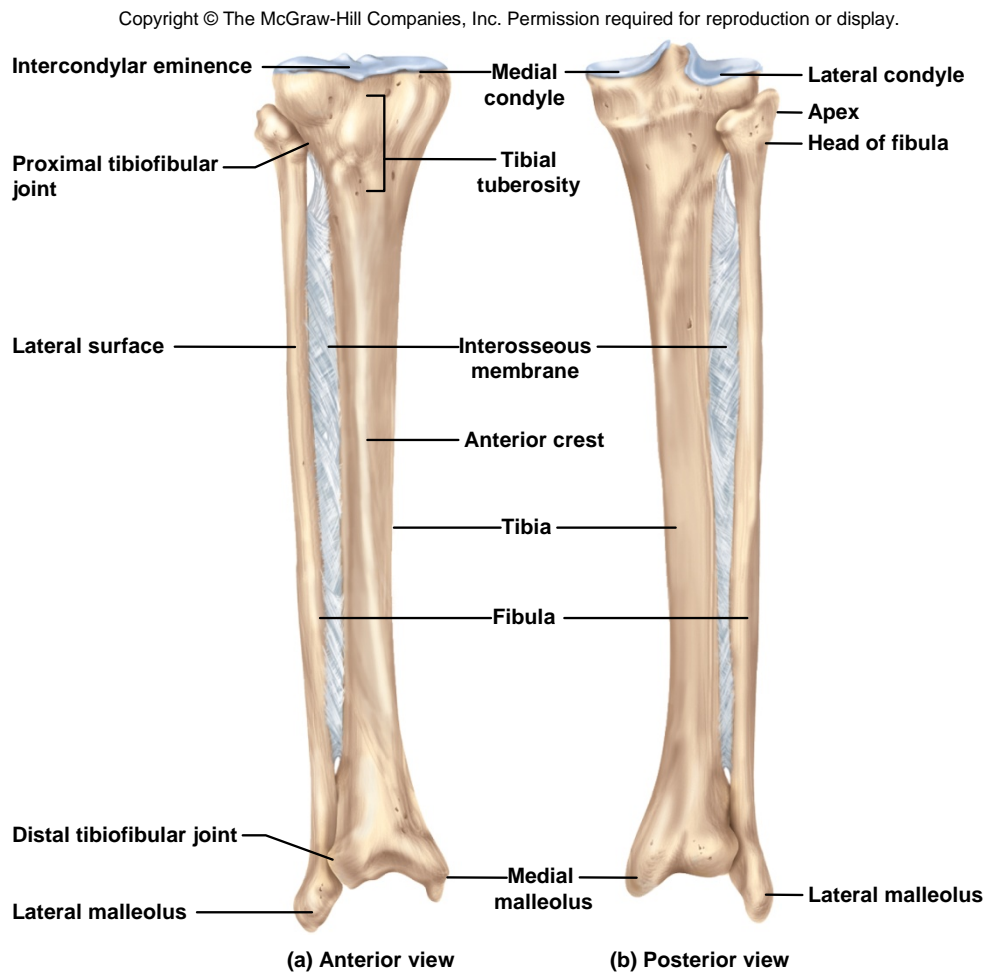


- **articular facets** – shallow, posterior portion

- *quadriceps femoris tendon* extends from the anterior muscle of the thigh to the patella

- continues as the **patellar ligament** from the patella to the tibia

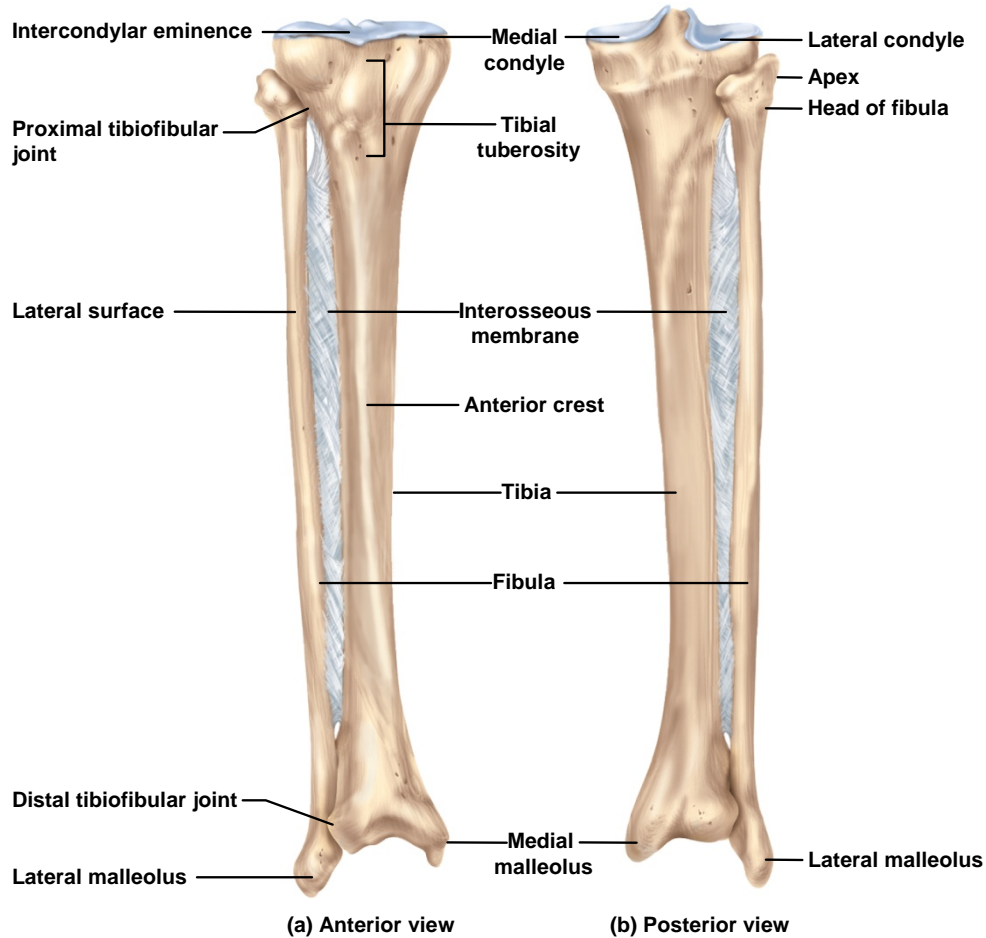
Tibia



- **thick, medial, weight-bearing bone**
- **only weight bearing bone of the crural region**
- **broad superior head**
- **medial and lateral condyles**
- **fairly flat articular surfaces**
- **articulate with condyle of femur**

Tibia

Copyright © The McGraw-Hill Companies, Inc. Permission required for reproduction or display.



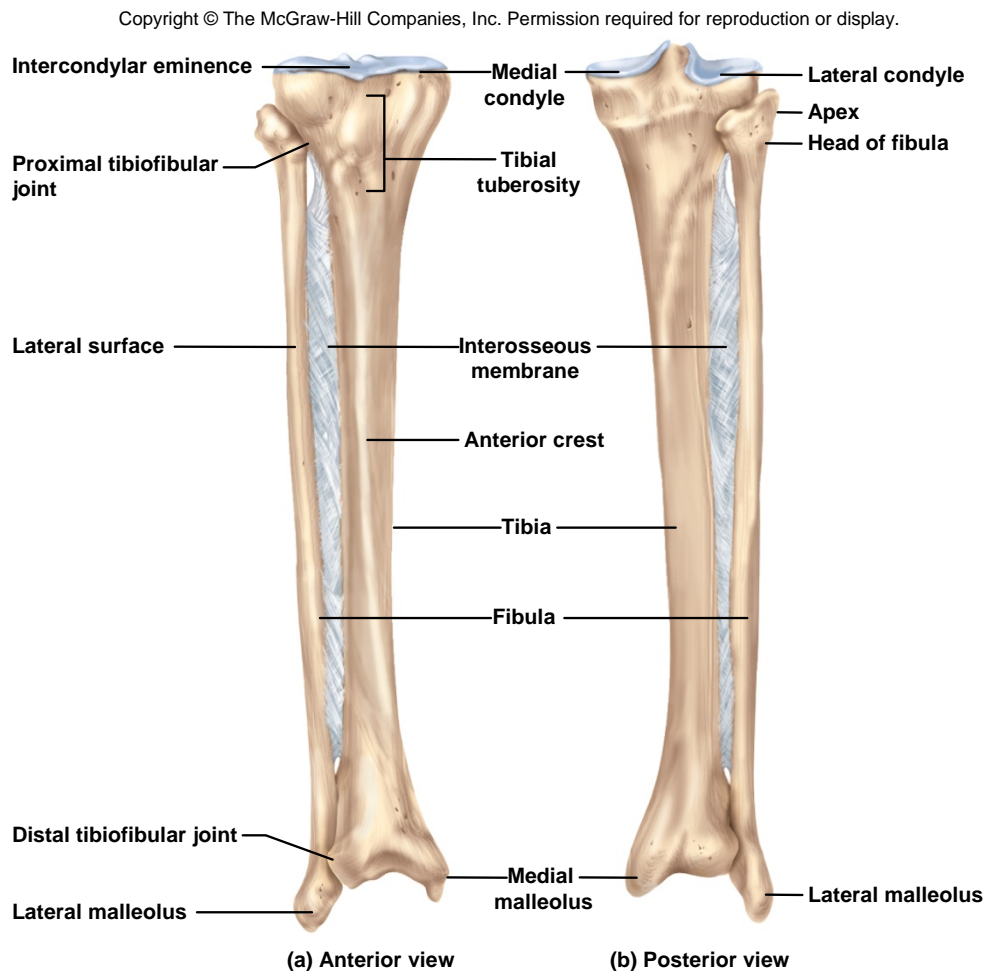
– **intercondylar eminence** – ridge separating condyles

– **tibial tuberosity** – attachment of quadriceps muscles

– **anterior crest** – sharp, angular

– **medial malleolus** – bony knob on inside of ankle

Fibula



- slender, lateral strut that helps stabilize ankle
- does not bear any body weight
 - spare bone tissue for grafts
- **head** - proximal end
- **apex** – point of the head
- **lateral malleolus** - distal expansion, bony knob on lateral side of ankle
- joined to tibia by **interosseous membrane**

The Ankle and Foot

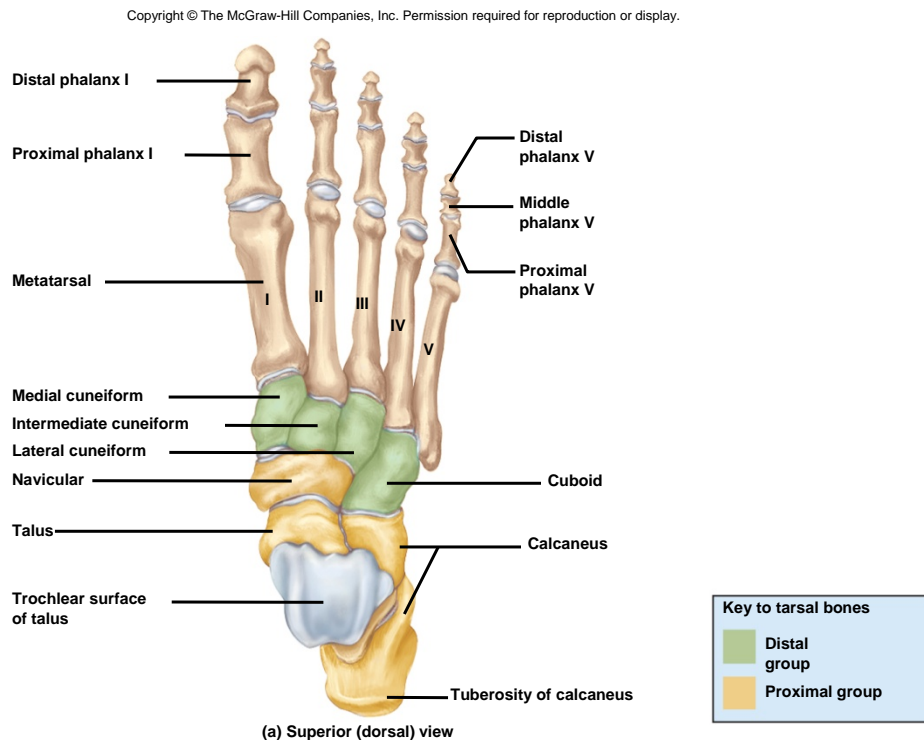
- **talus** is most superior tarsal bone

- forms ankle joint with tibia and fibula

- sits upon calcaneus and articulates with navicular

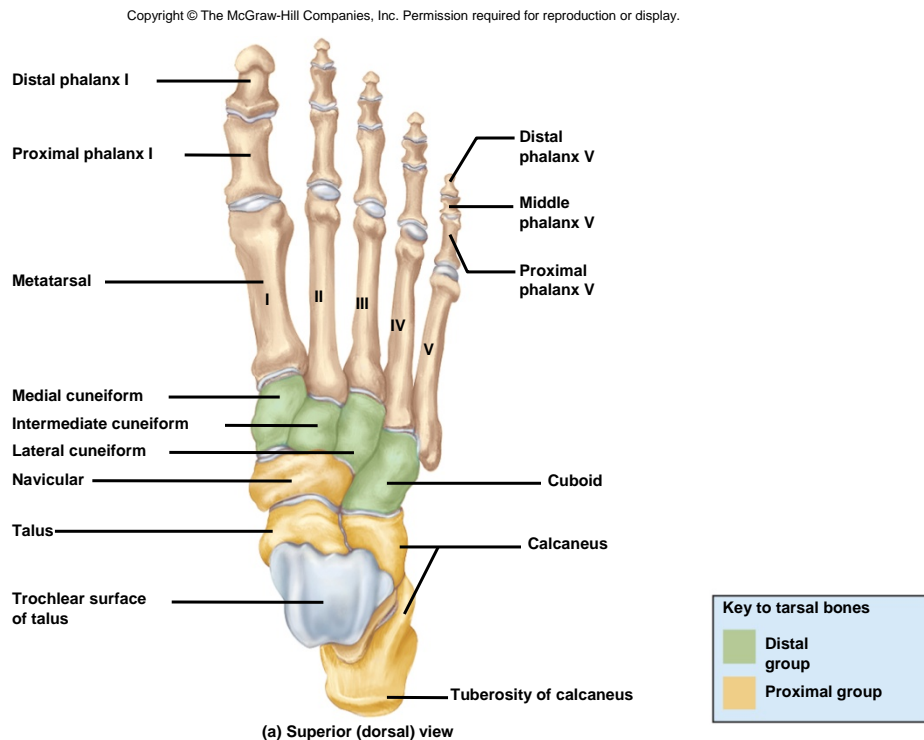
- **proximal row** of tarsal bones // talus, calcaneus, and navicular

- **distal row** of tarsal bones // medial, intermediate and lateral cuneiforms and cuboid



The Ankle and Foot

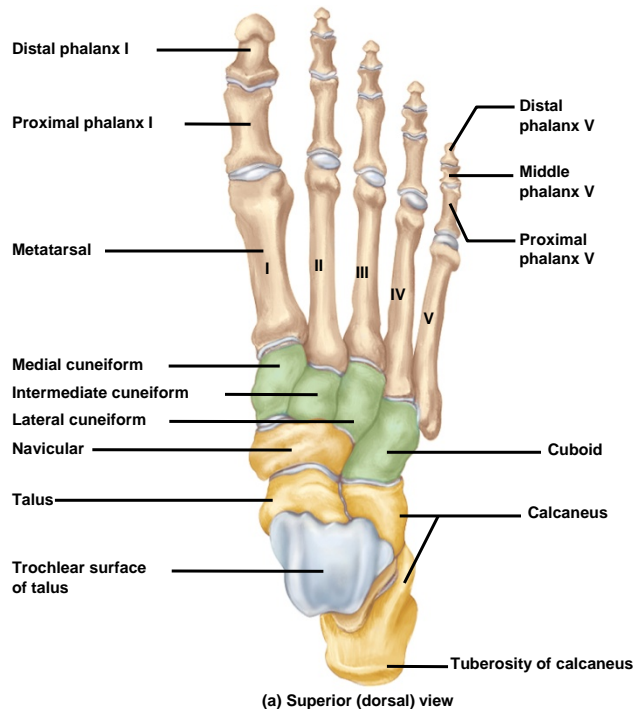
- **tarsal bones** – arranged in proximal and distal groups
- tarsal bones are shaped and arranged differently from carpal bones due to load-bearing role of the ankle
- **calcaneus** – largest tarsal bone
 - forms heel
 - distal portion is point of attachment for **calcaneal (Achilles) tendon**



The Foot

- remaining bones of foot are similar in name and arrangement to the hand

Copyright © The McGraw-Hill Companies, Inc. Permission required for reproduction or display.



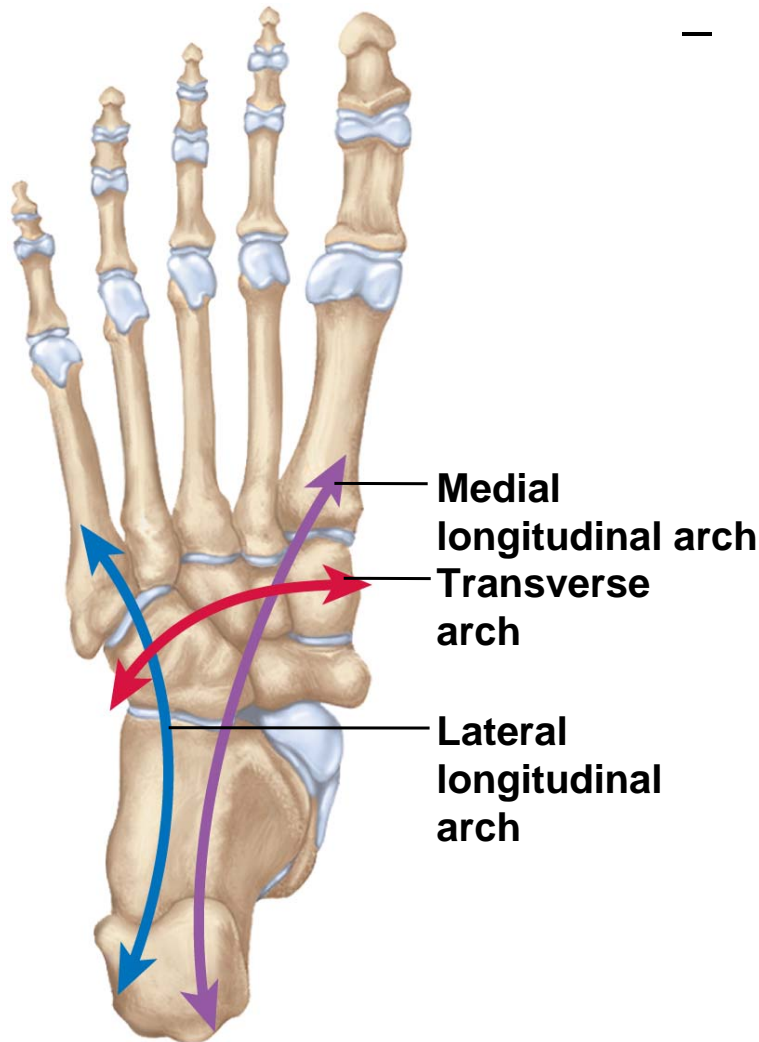
Metatarsals

- metatarsal I is proximal to the great toe (hallux)
- metatarsal V is proximal to the little toe
- proximal base, intermediate shaft, and distal head

Phalanges

- 2 in great toe // proximal and distal phalanx
- 3 in all other toes // proximal, middle and distal phalanx

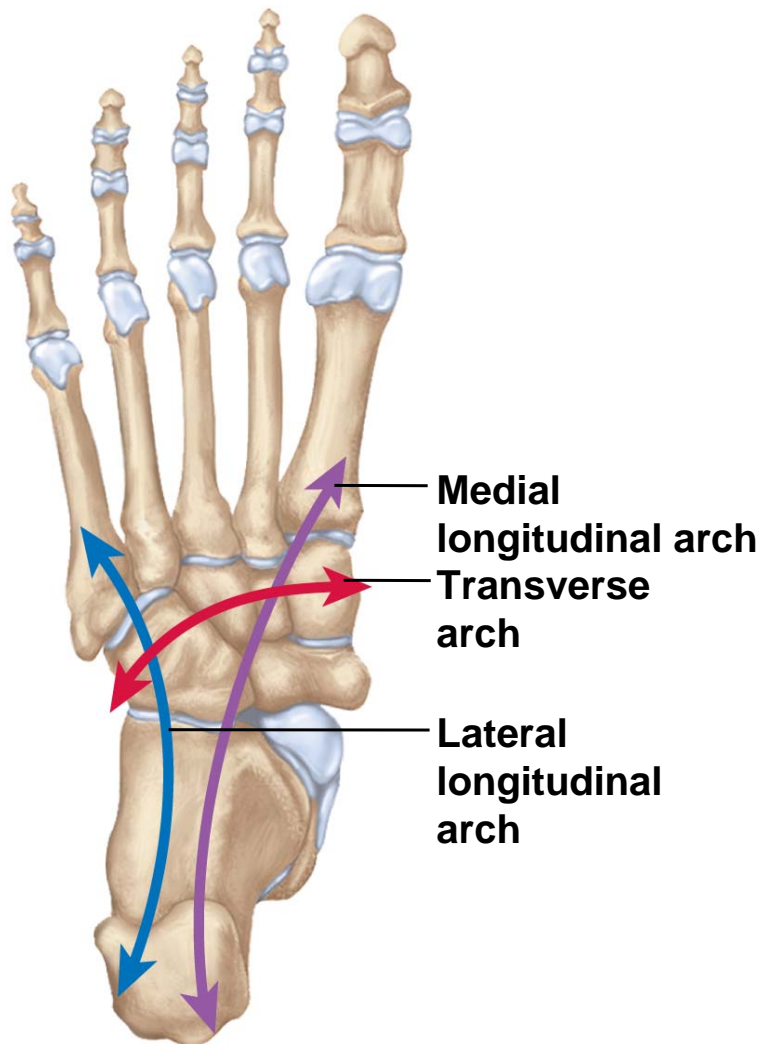
Foot Arches



(a) Inferior (plantar) view

- sole of foot is not flat on ground
- **3 springy arches** absorb stress
-
- **medial longitudinal arch**
 - from heel to hallux
 - formed from the calcaneus, talus, navicular, cuneiforms and metatarsals I and III
- **lateral longitudinal arch**
 - from heel to little toe
 - includes calcaneus, cuboid, and metatarsals IV and V
- **transverse arch**
 - across middle of foot
 - includes the cuboid, cuneiforms, and proximal heads of metatarsals

Foot Arches



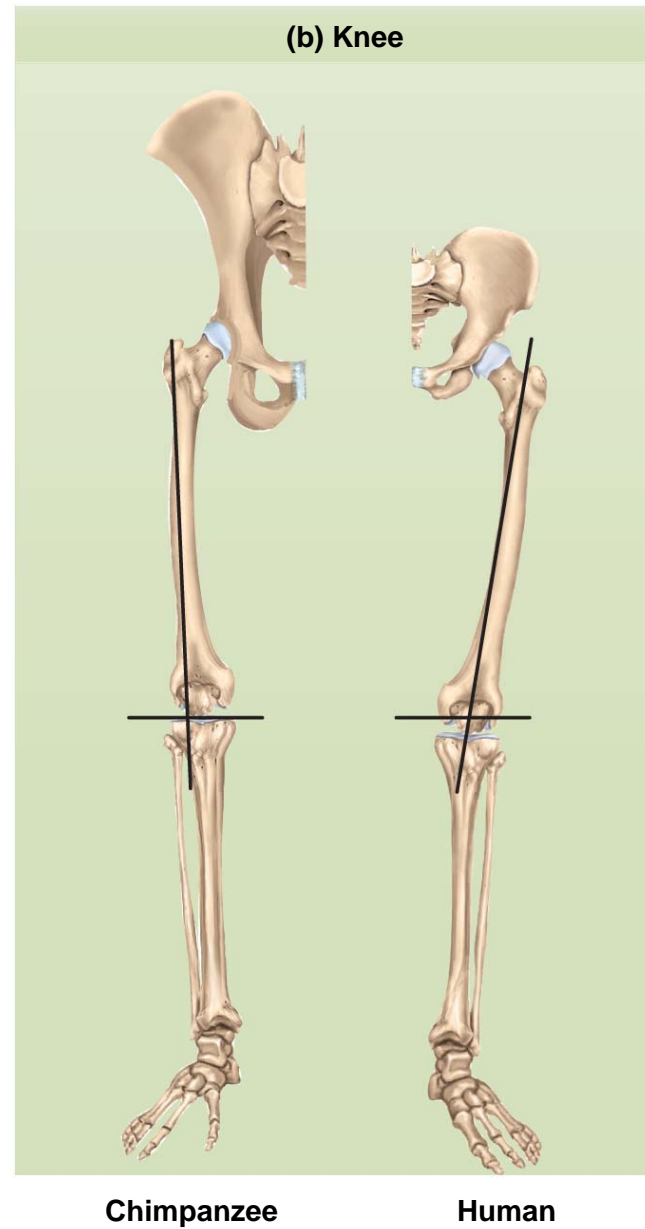
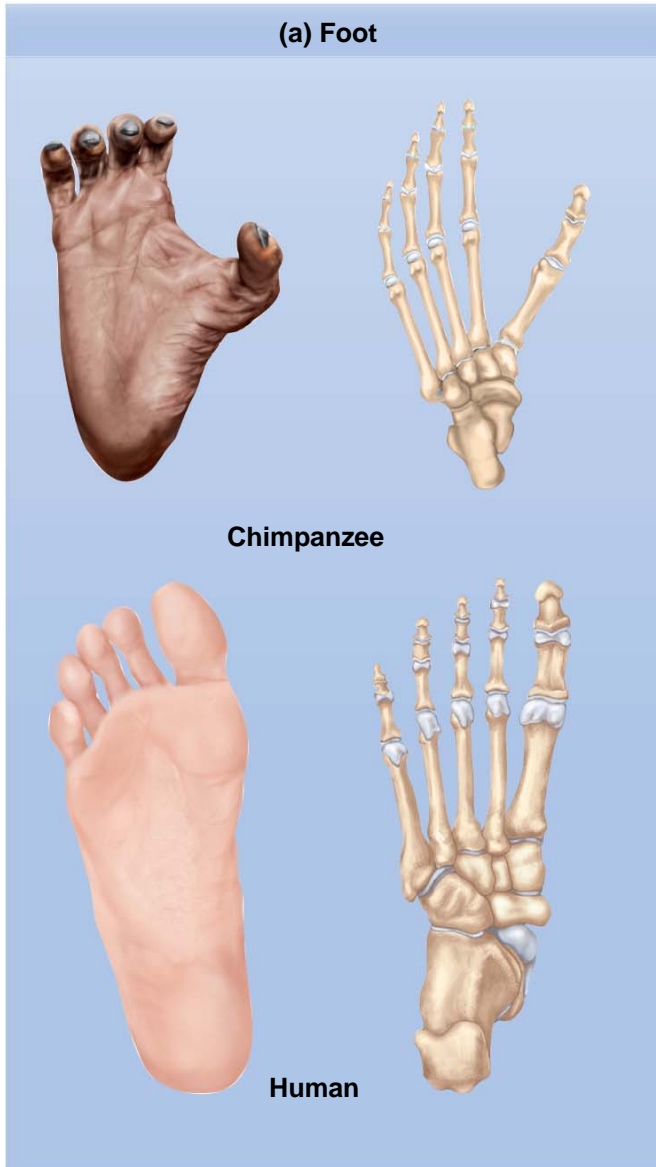
(a) Inferior (plantar) view

- arches held together by short, strong ligaments
- **pes planus** (flat feet) – excessive weight, repetitious stress, or congenital weakness

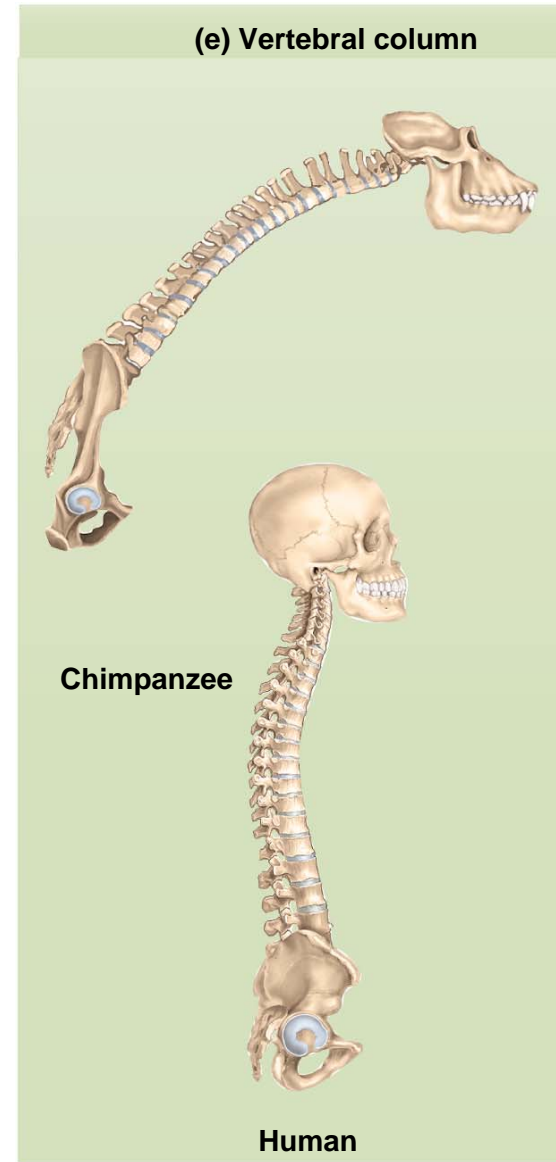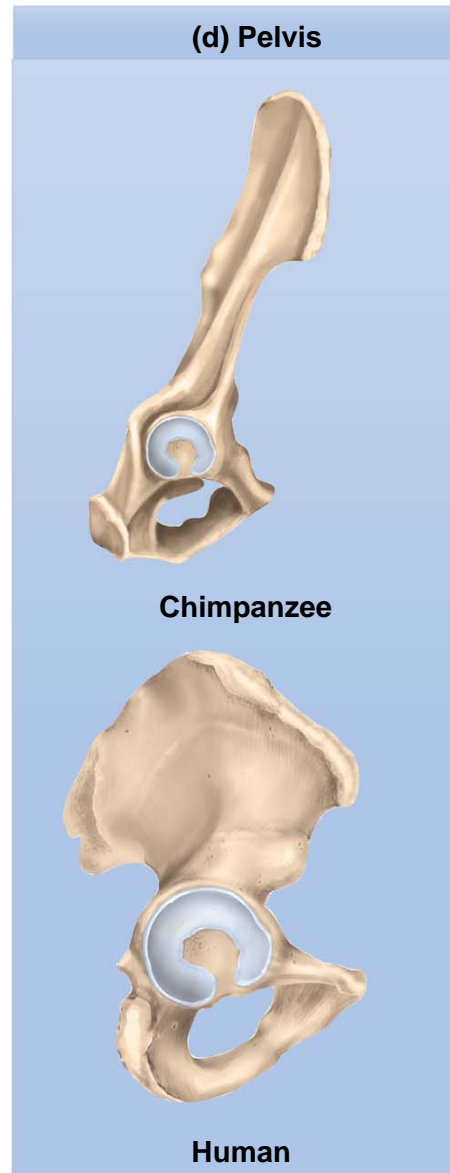
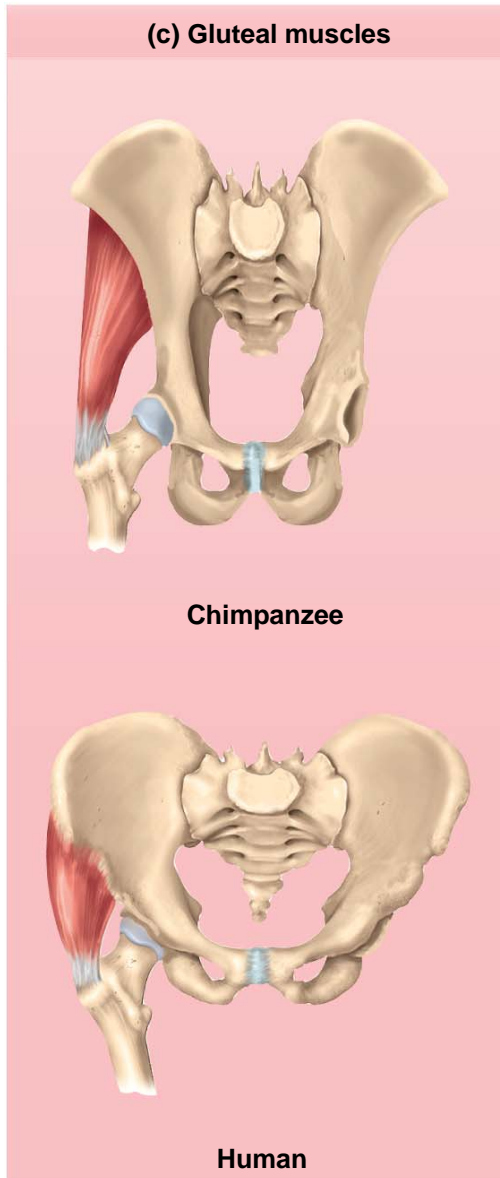
Skeletal Adaptations for Bipedalism

- humans are only animals habitually **bipedal** // 3.6 million year old human footprints indicate upright walking
- **Adaptations**
 - strong, springy foot arches
 - great toe not opposable
 - femurs angle inward so knees are closer together – erect posture requires less muscular effort
 - viscera supported in bowl-shaped pelvis
 - insertions of gluteal muscles differ from other primates

Bipedalism and Limb Adaptations



Bipedalism and Upright Stance



Bipedalism and Head Position

