Chapter 13

The Spinal Cord

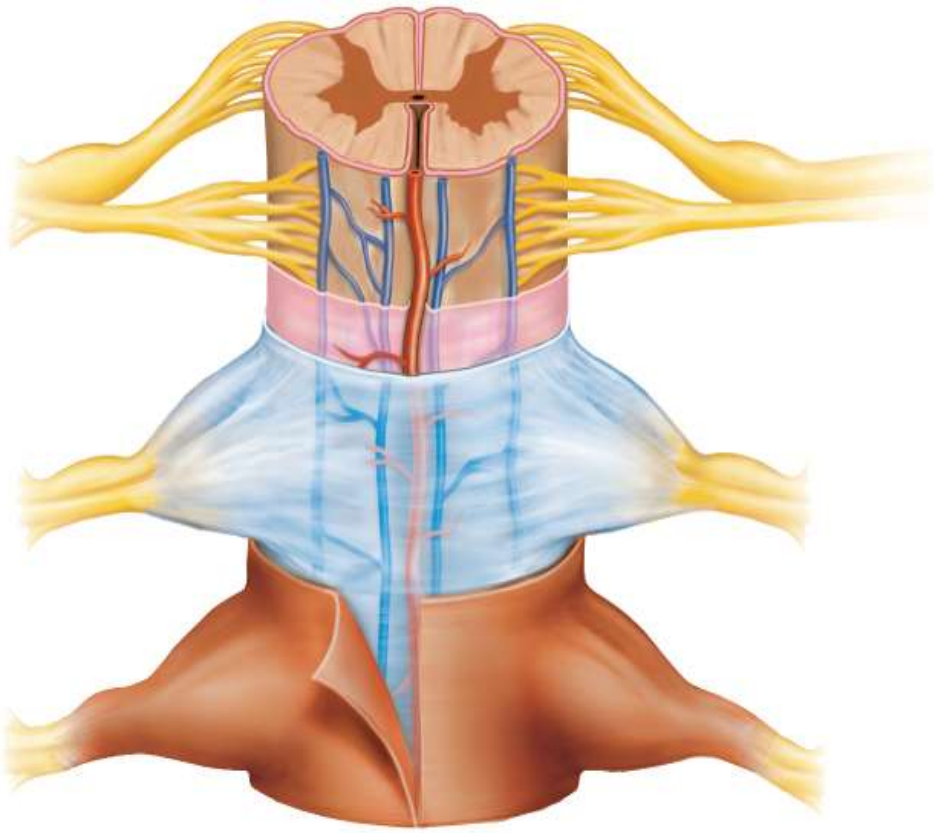

Functions of the Spinal Cord

- Conduction
  - bundles of fibers passing information up and down spinal cord, connecting different levels of the trunk with each other and with the brain

- Locomotion
  - walking involves repetitive, coordinated actions of several muscle groups
  - local neural circuits (central pattern generators) are pools of neurons providing control of flexors and extensors that cause alternating movements of the lower limbs

- Reflexes
  - involuntary, stereotyped responses to stimuli // e.g. withdrawal of hand from pain
  - involves spinal cord and peripheral nerves (i.e. brain finds out about the event after the event has already occured)

Overview of the spinal cord structure and function.

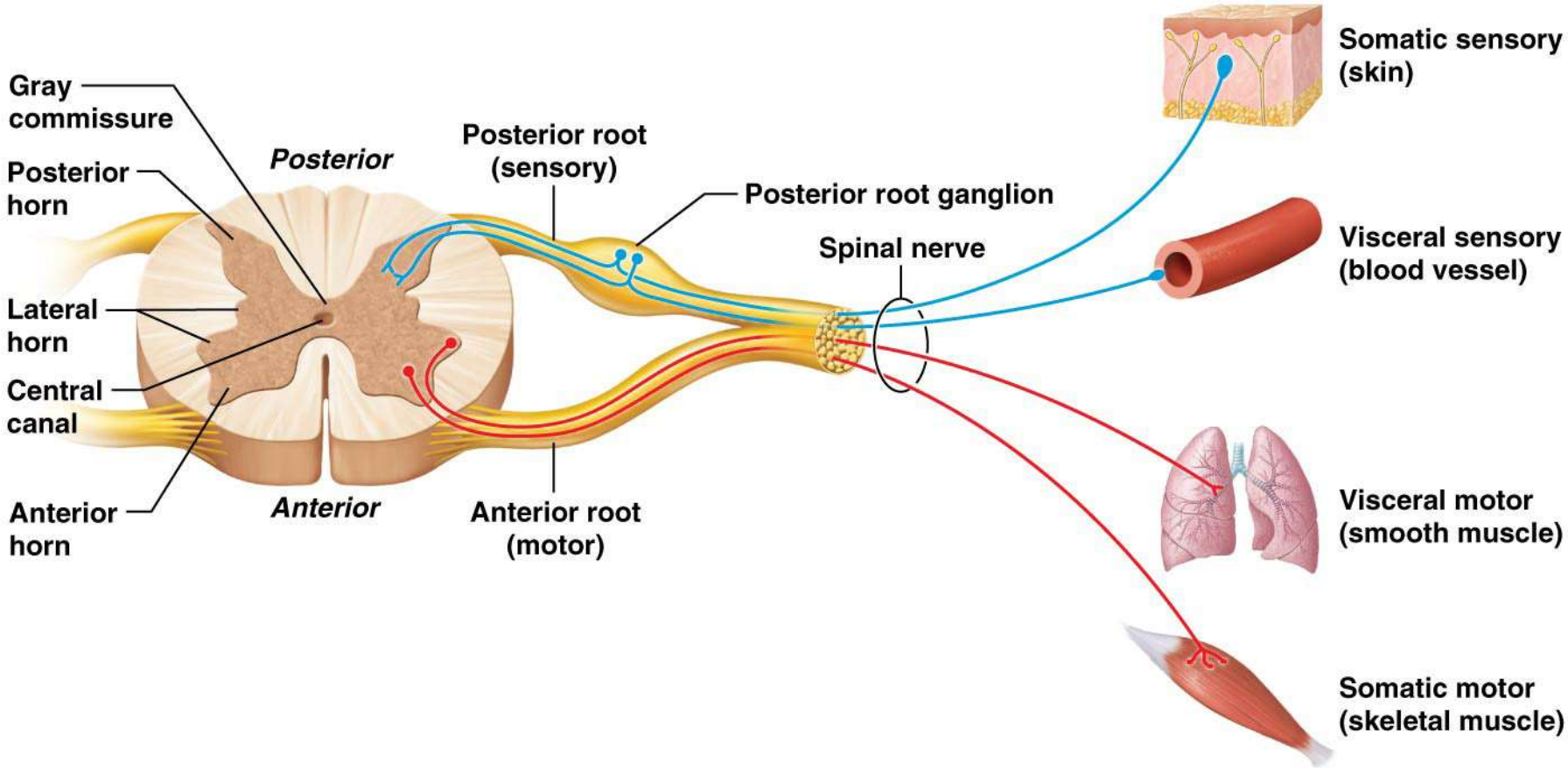

Surface Anatomy

- **Spinal cord** – cylinder of nervous tissue that starts at the brainstem at the foramen magnum of the skull
  - passes through the **vertebral foramin**
  - inferior margin **ends at L1** or a little beyond
  - averages 1.8 cm thick and 45 cm long
  - occupies the **upper two-thirds of the vertebral canal**

External structure of the spinal cord.

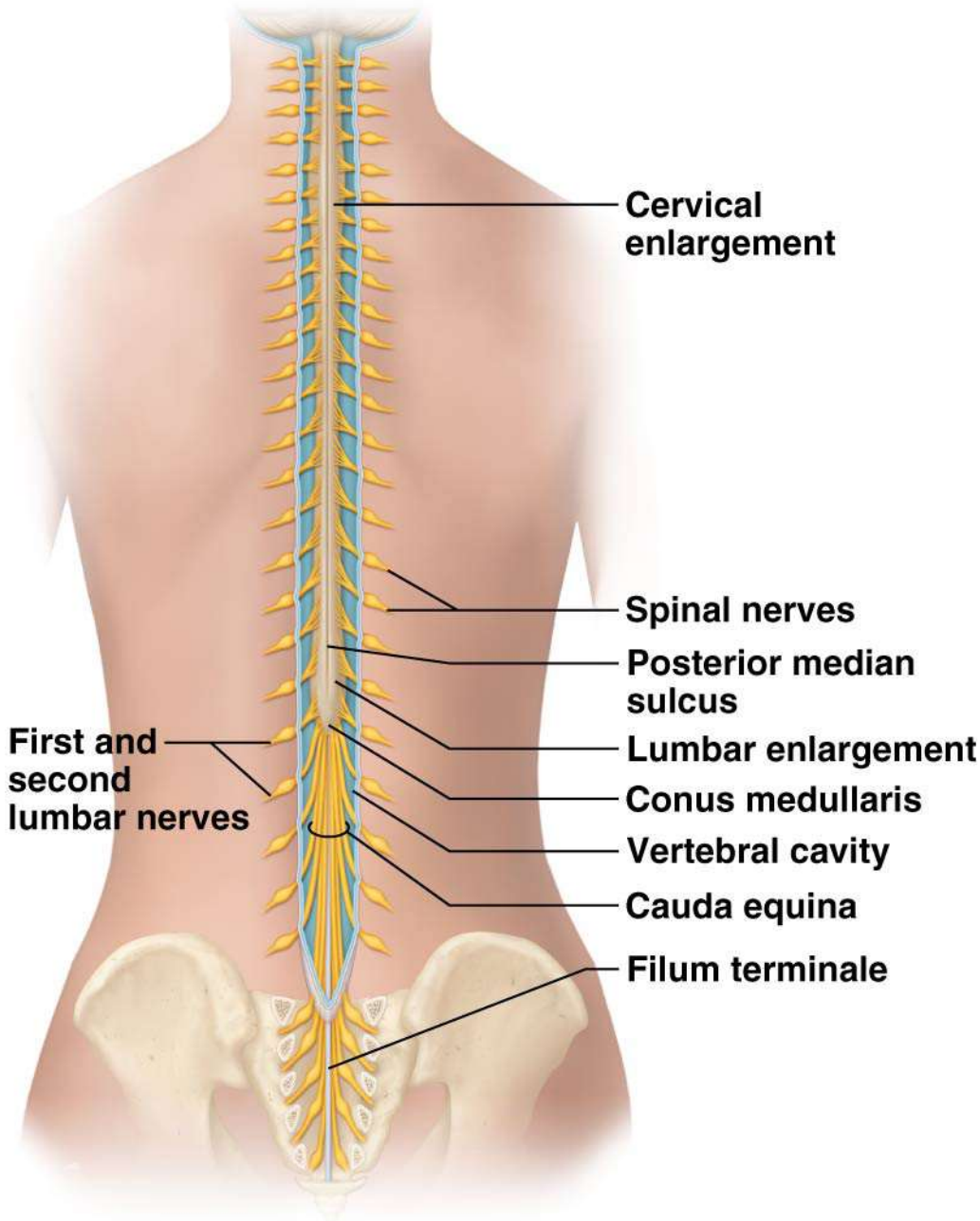

(a) Spinal cord, posterior view

Surface Anatomy

- Spinal cord gives rise to 31 pair of **spinal nerves**

  first pair passes between the skull and C1

  all other pass through intervertebral foramina

- Note: a segment in the spinal cord refers to part of the spinal cord which is supplied by each <u>pair of spinal nerves</u>

The Spinal Nerve and Vertebrae

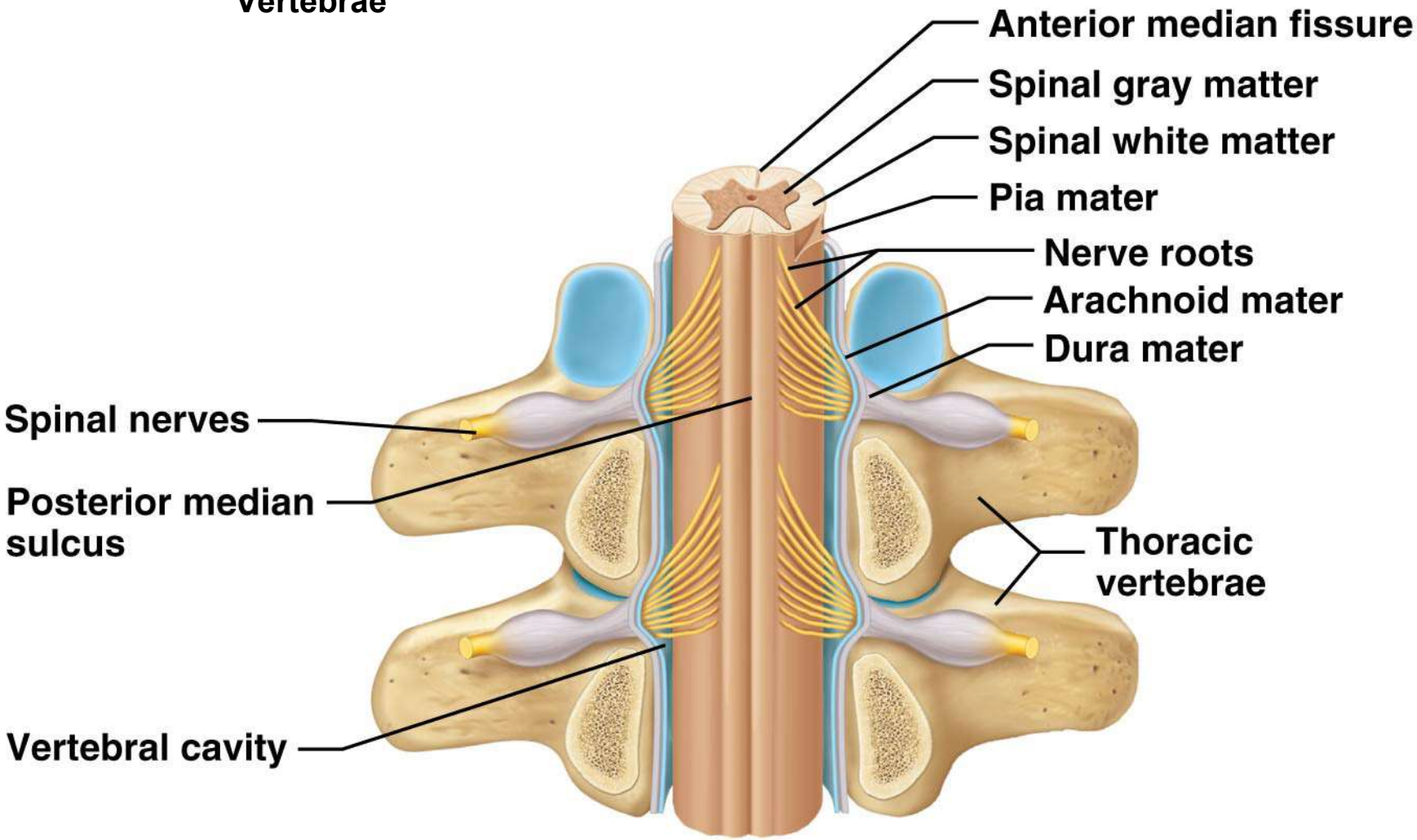

(b) Section of spinal cord and associated structures, posterior view

Spinal Nerve and Vertebrae

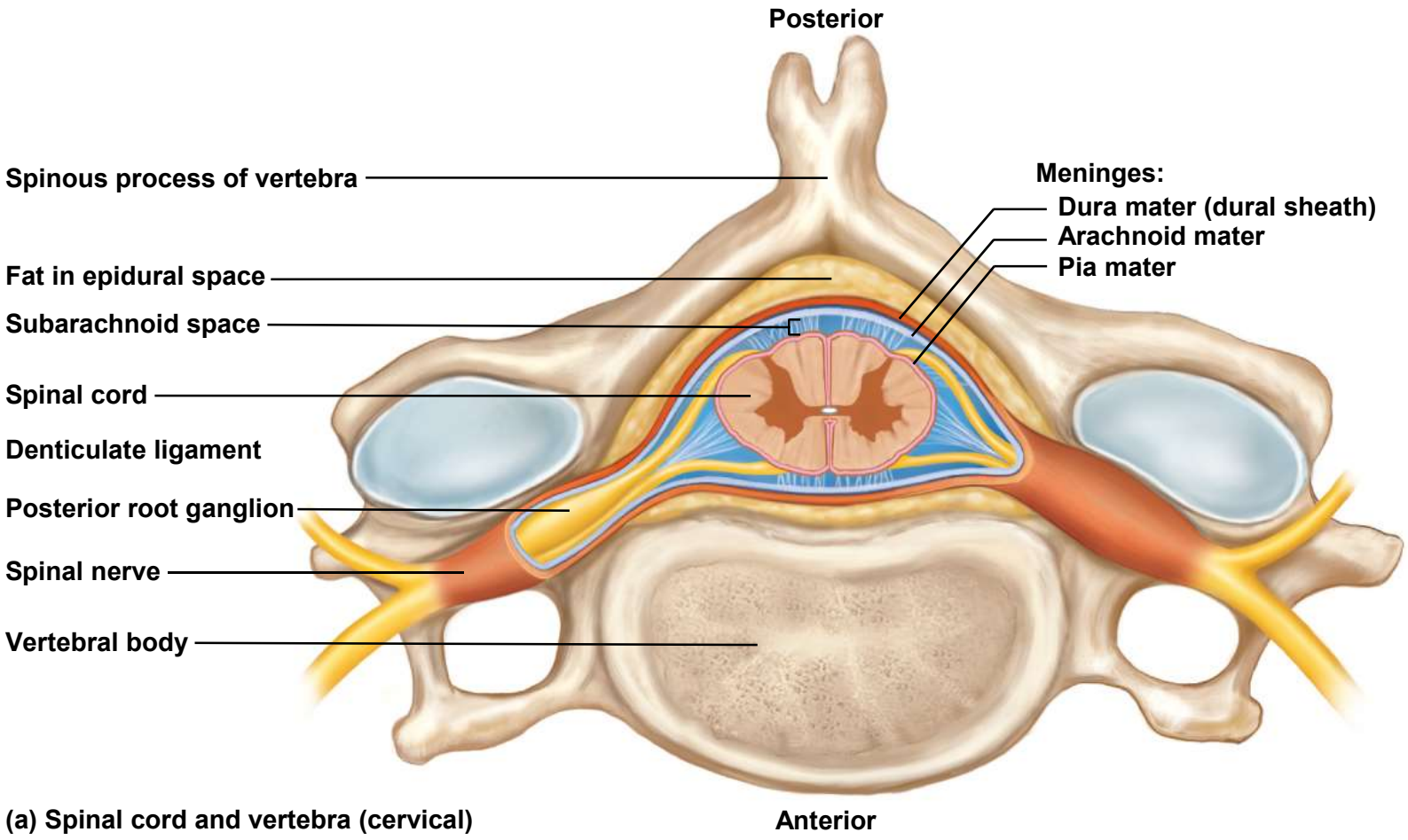

(a) Spinal cord and vertebra (cervical)

Spinal Nerves and Spinal Roots

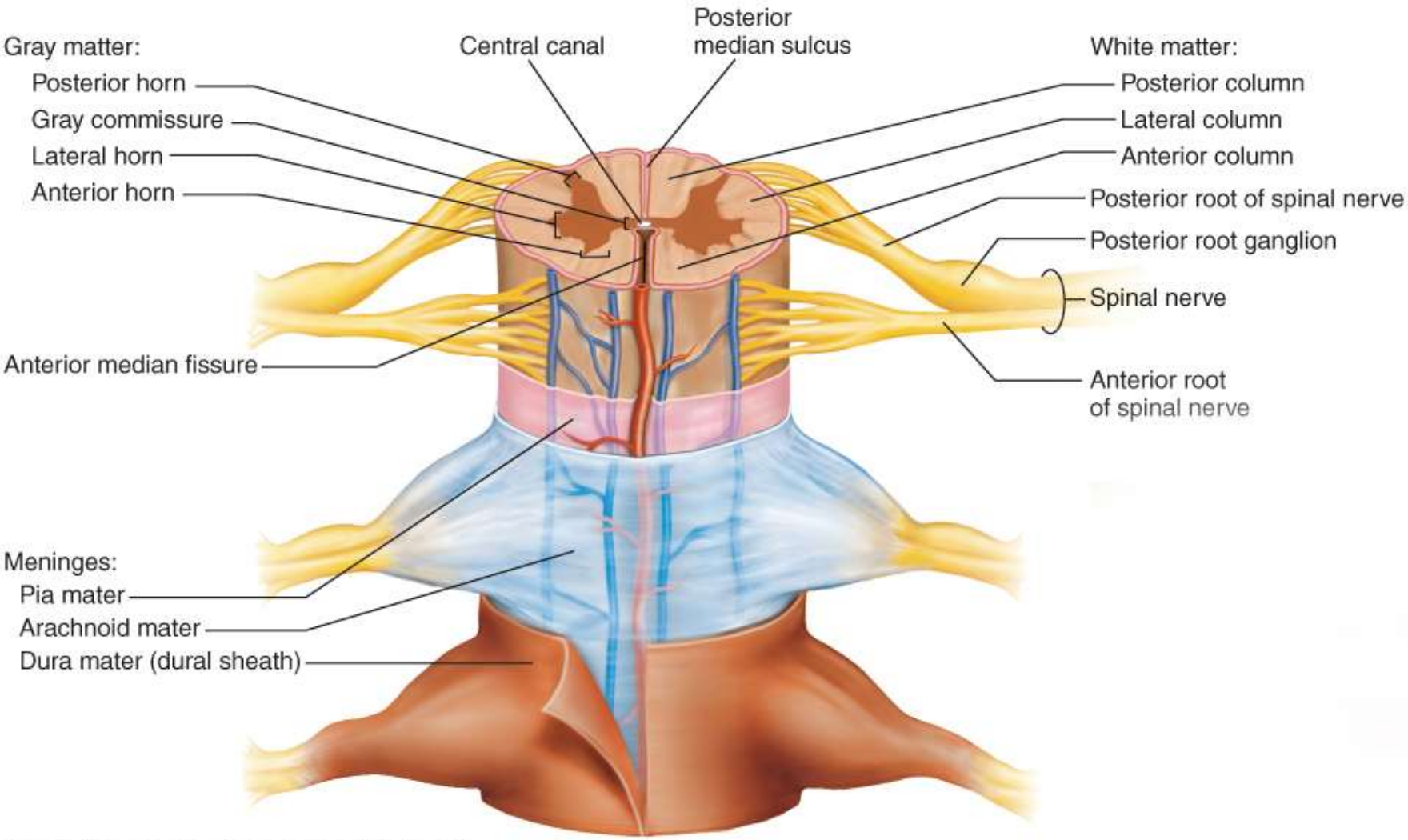

(b) Spinal cord and meninges (thoracic)

Connective Tissue Surrounding Spinal Nerve

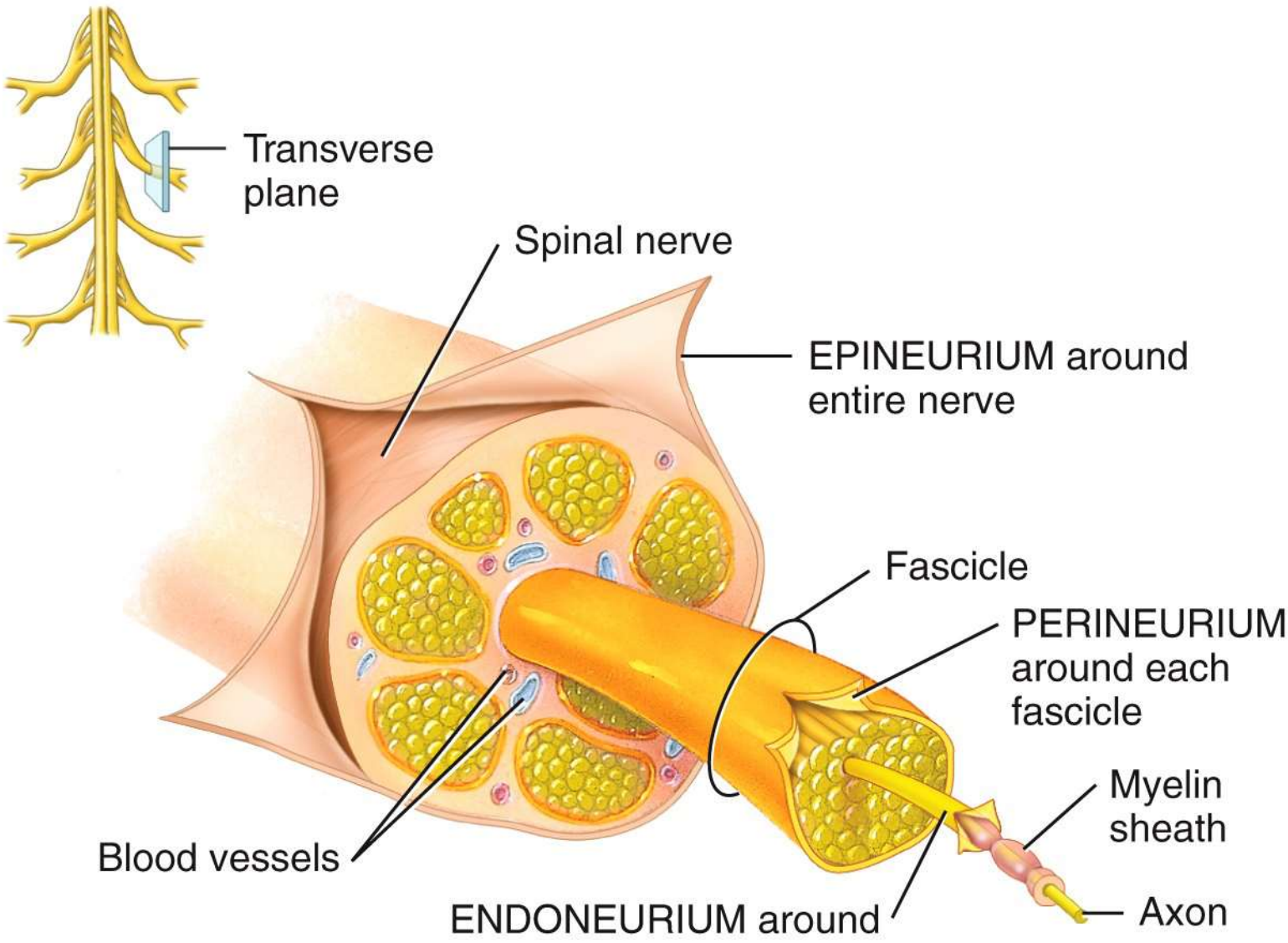

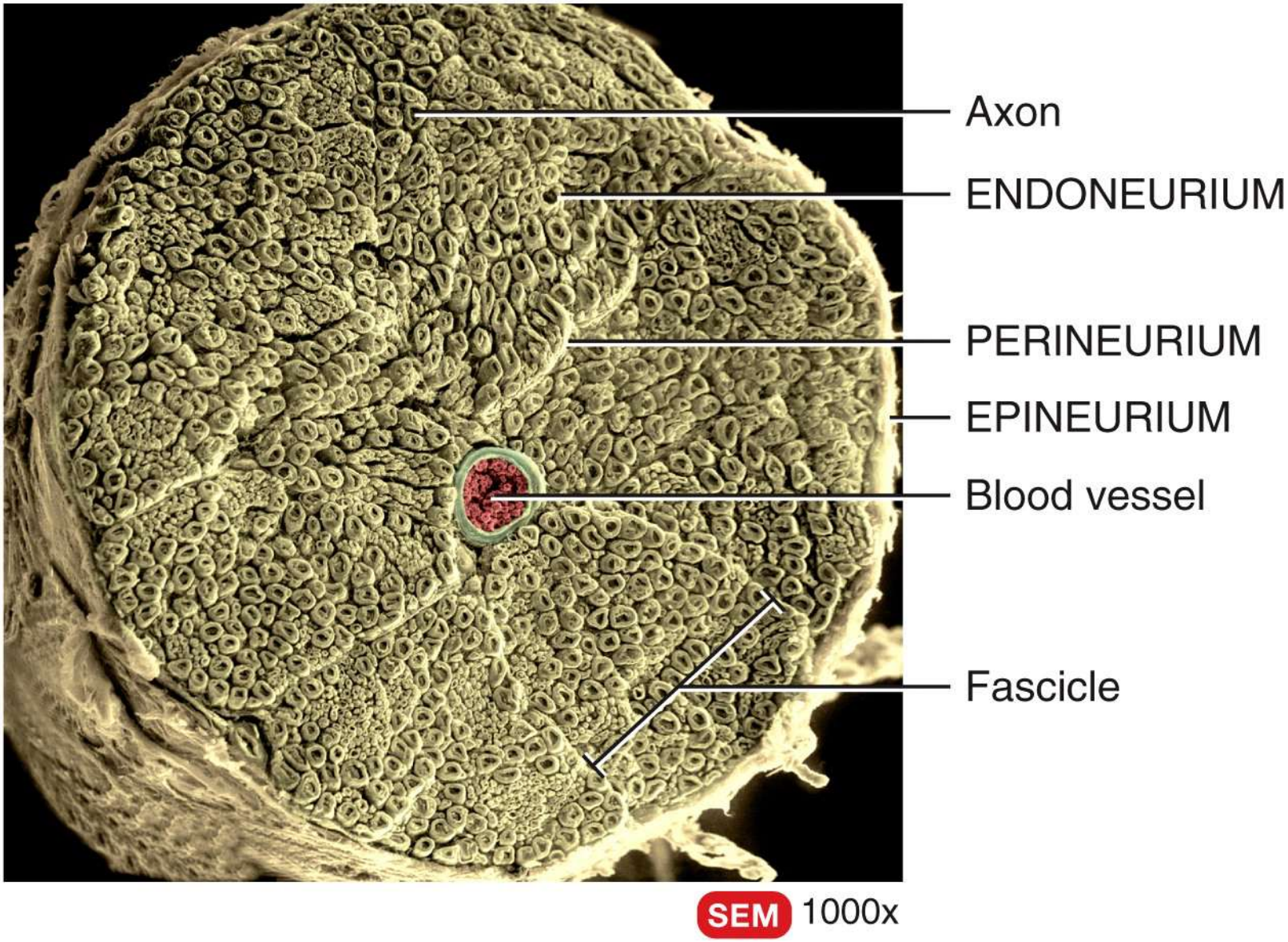

Thomas Deerinck, NCMIR/Photo Researchers, Inc.

(b) Transverse section of several nerve fascicles

Surface Anatomy

- Longitudinal grooves on anterior and posterior surface of spinal cord
  - anterior median fissure
  - posterior median sulcus
- Spinal cord divided into the cervical, thoracic, lumbar, and sacral regions
- Wwo areas of the cord are thicker than elsewhere
  - cervical enlargement – nerves to upper limb
  - lumbar enlargement – nerves to pelvic region and lower limbs

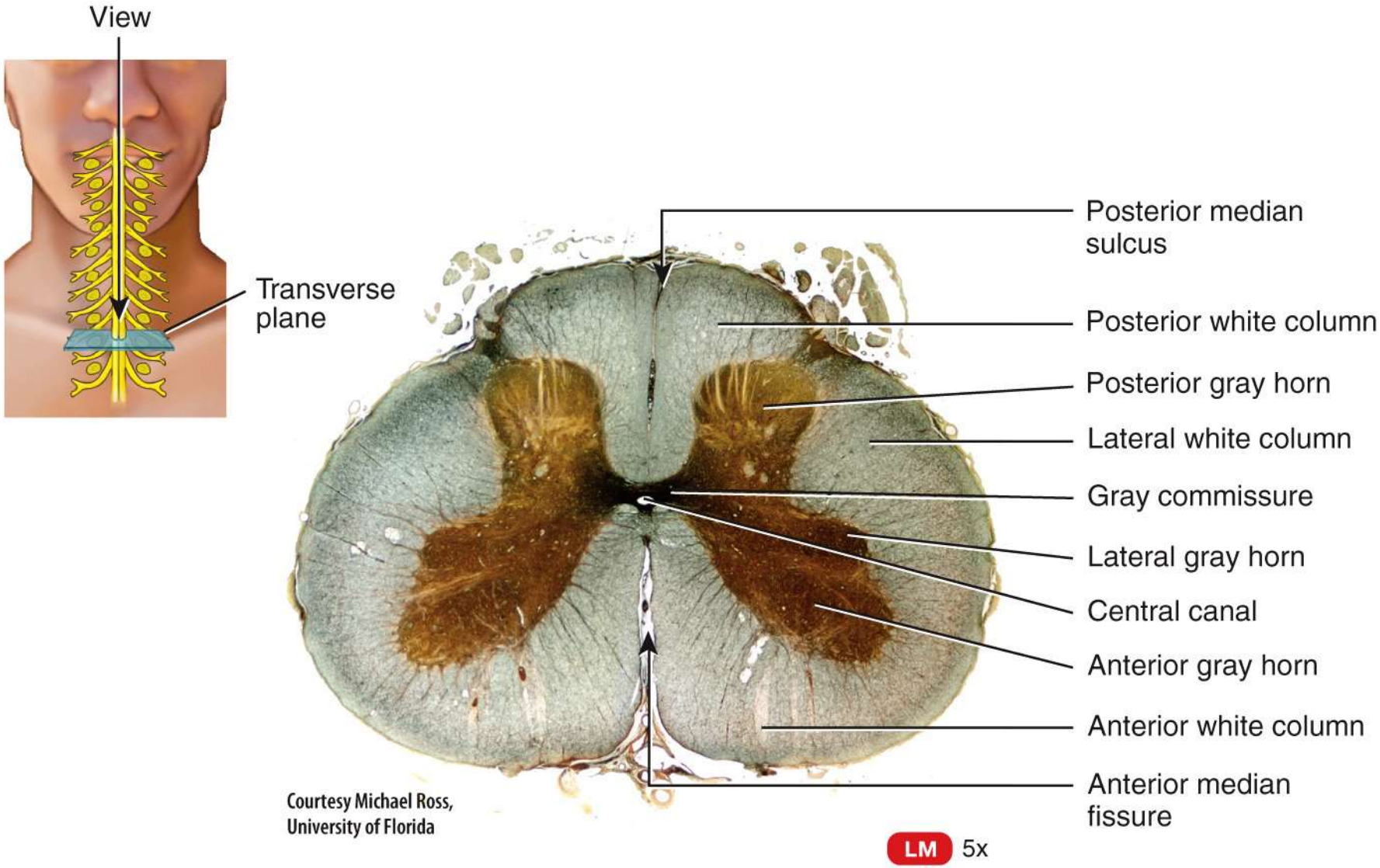

(b) Transverse section of lumbar spinal cord

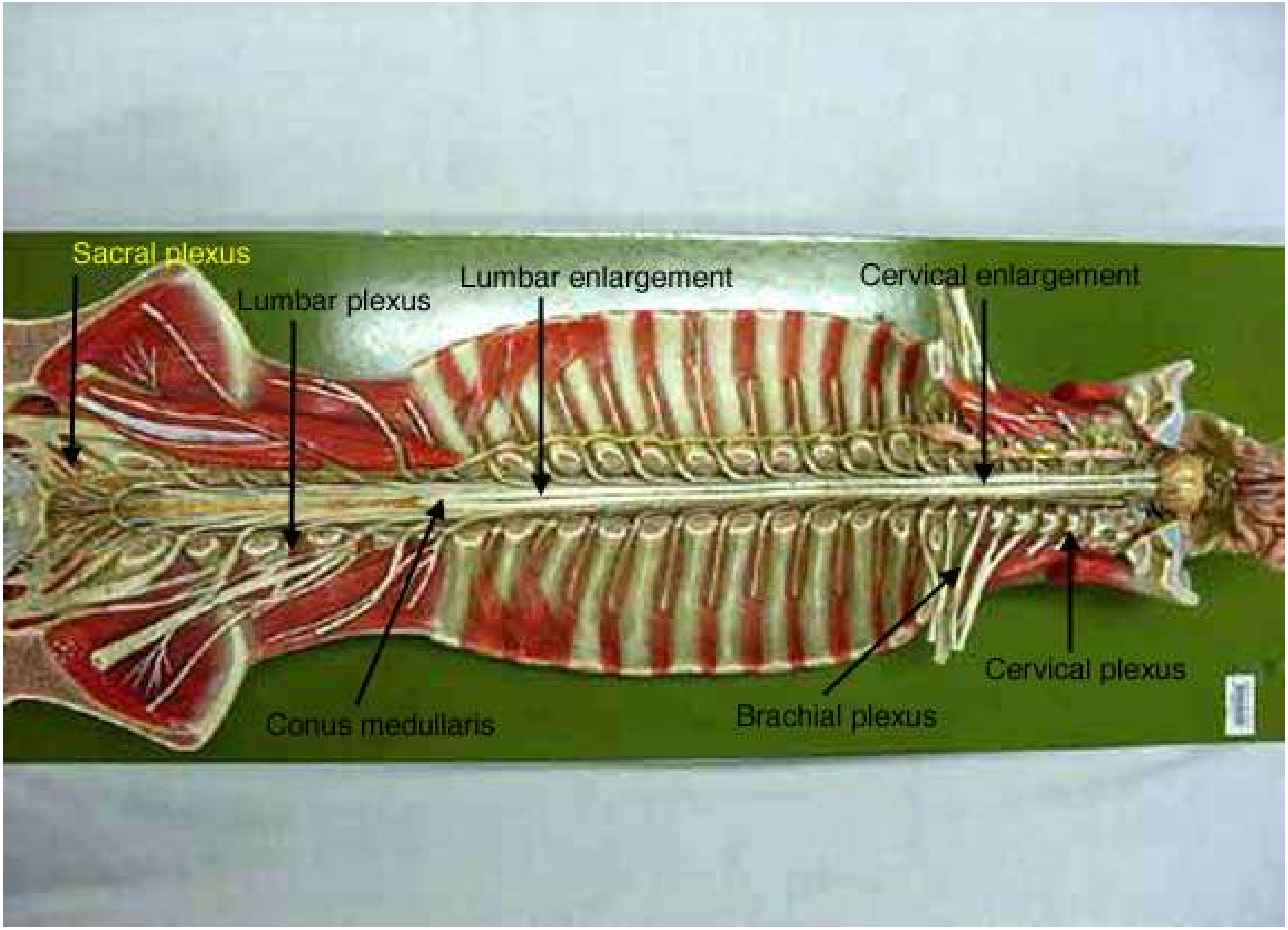
Sacral plexus
Lumbar plexus
Lumbar enlargement
Cervical enlargement
Cervical plexus
Brachial plexus
Conus medullaris

Surface Anatomy

medullary cone (conus medullaris) – cord tapers to a point inferior to lumbar enlargement

cauda equina – bundle of nerve roots that occupy the vertebral canal from L2 to S5

terminal filum – extension of pia matter from medullary cone which anchors spinal cord to inferiorly to coccyx

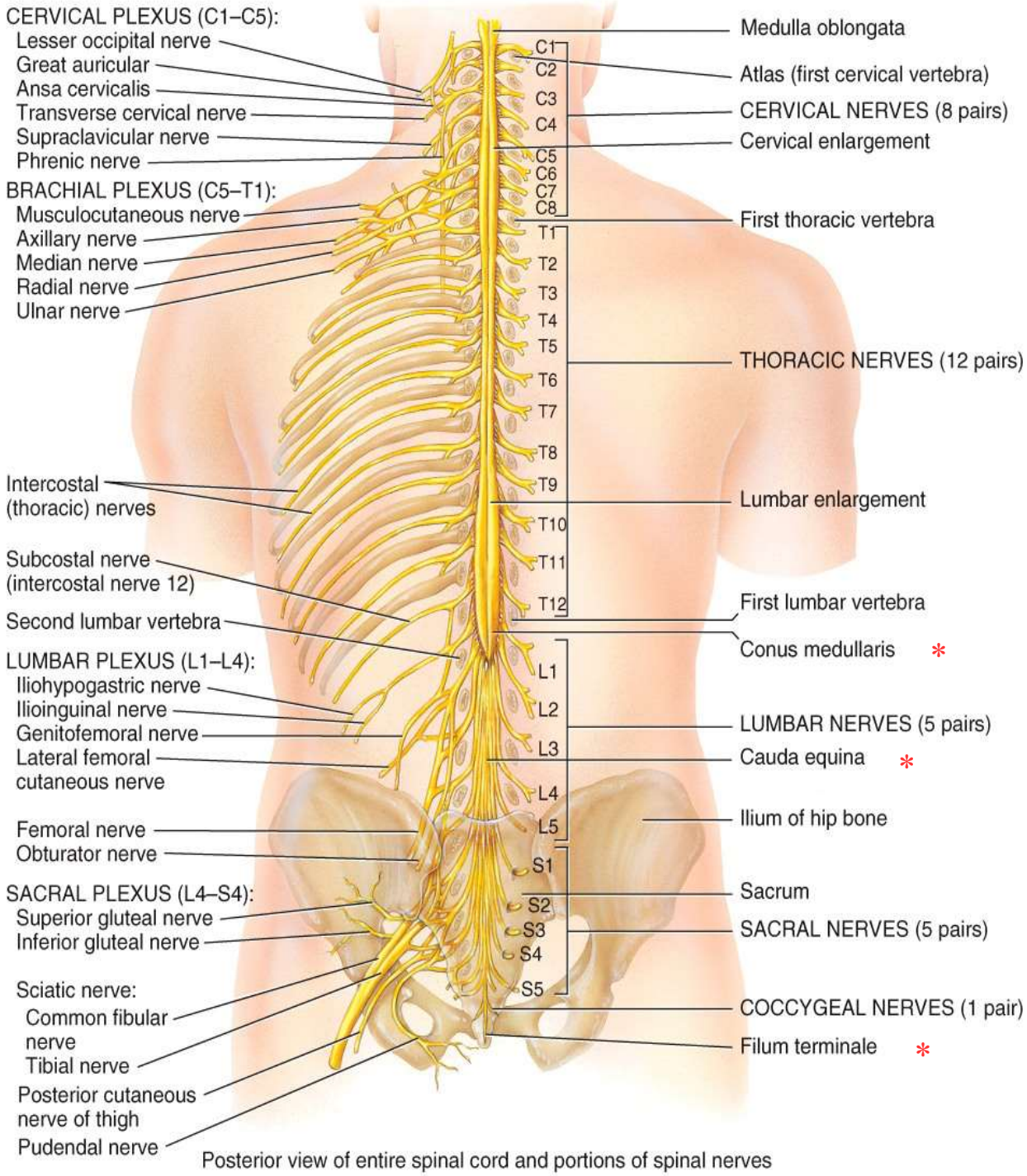

Posterior view of entire spinal cord and portions of spinal nerves

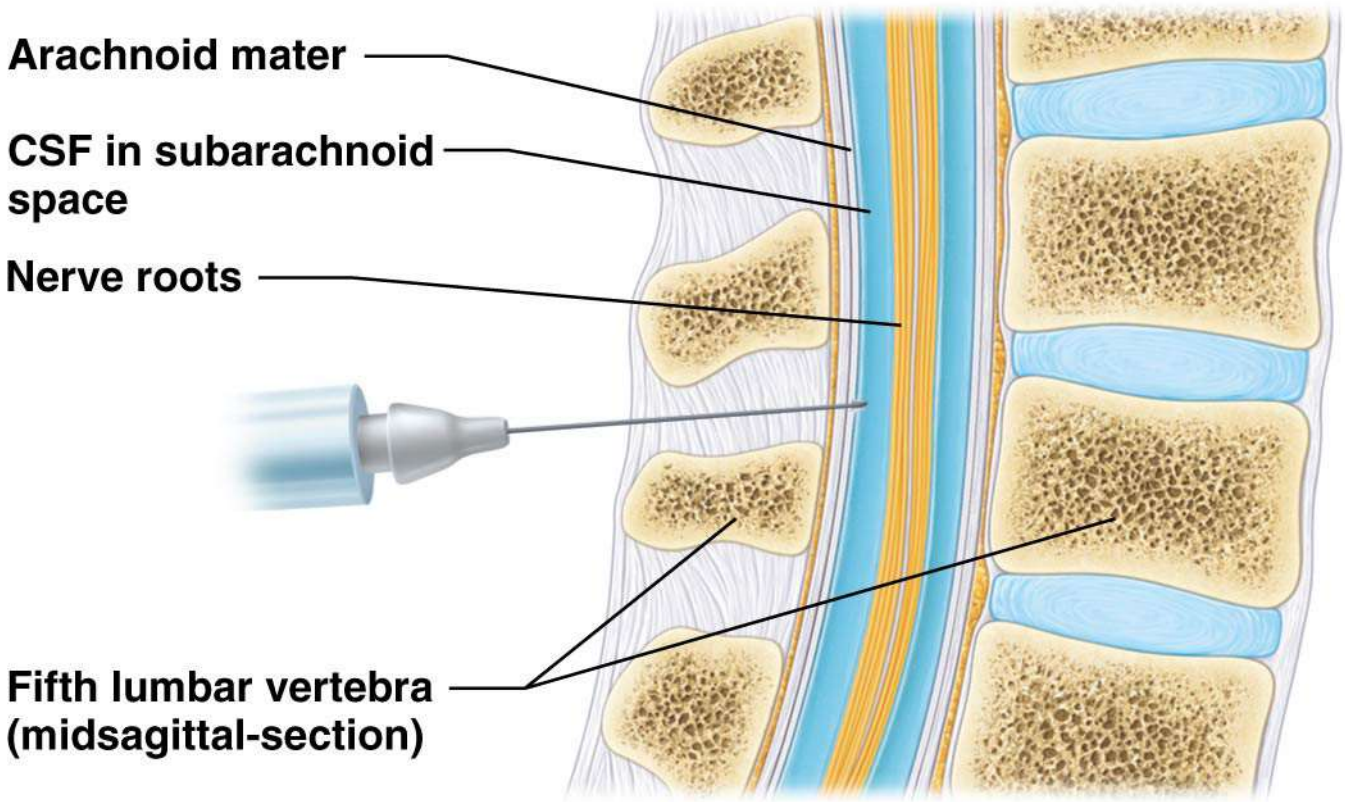
Arachnoid mater
CSF in subarachnoid space
Nerve roots
Fifth lumbar vertebra (midsagittal-section)

The Meninges of the Spinal Cord

- Three fibrous connective tissue membranes that enclose the brain and spinal cord
  - separate soft tissue of central nervous system from bones of cranium and vertebral canal
  - from superficial to deep
    - dura mater
    - arachnoid mater
    - pia mater

The Meninges of the Spinal Cord

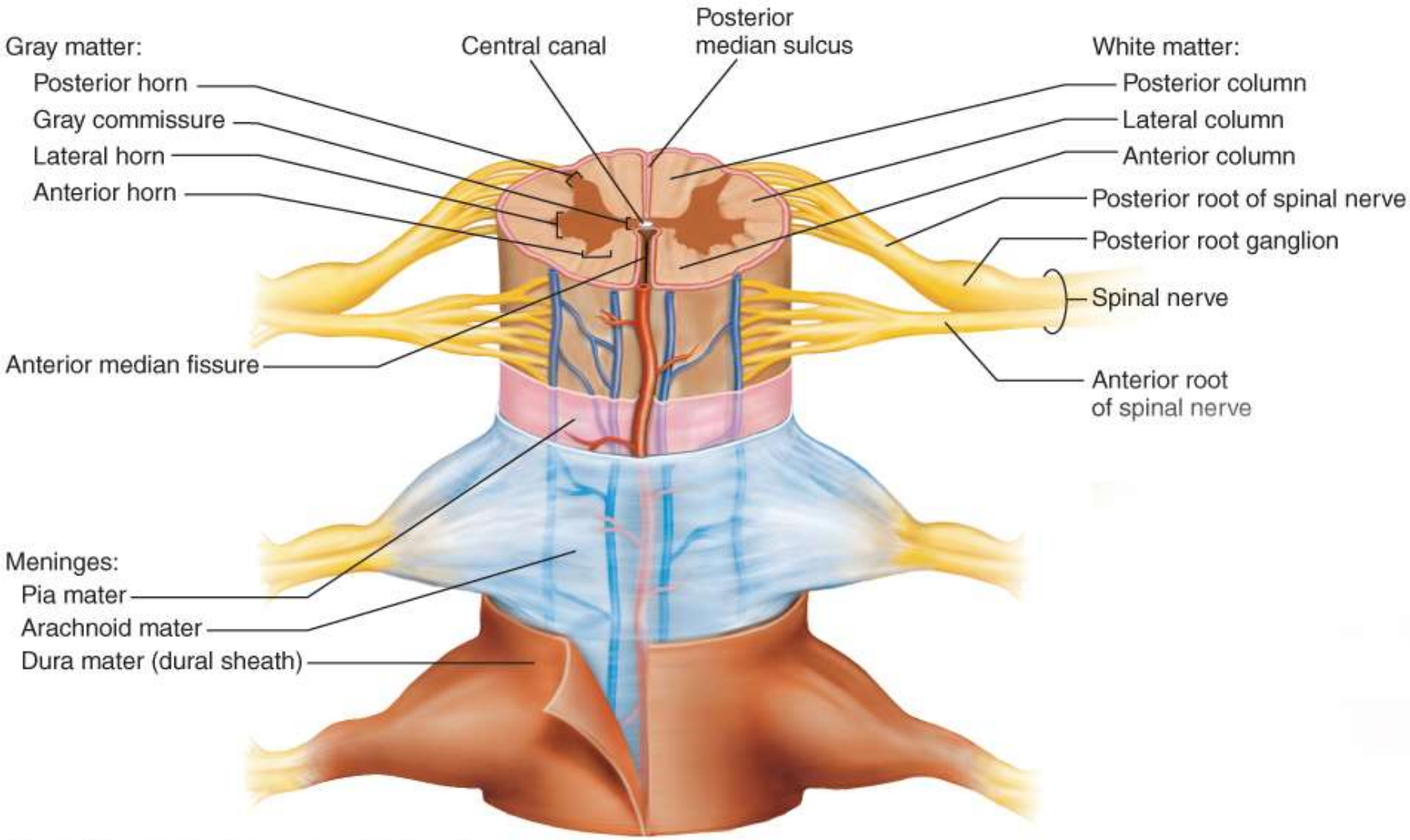

(b) Spinal cord and meninges (thoracic)

The Spinal Cord's Connective Tissue Cover

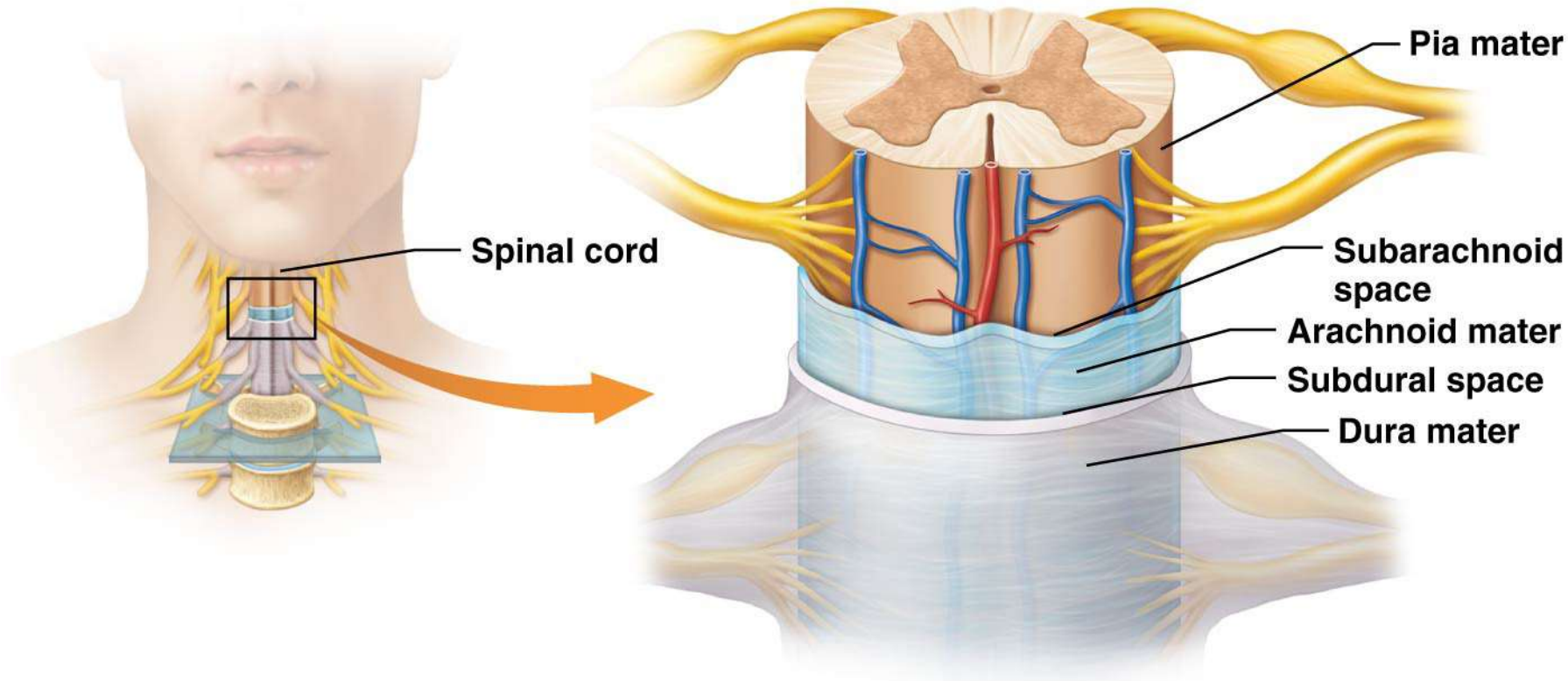

(a) Spinal meninges and spinal cord, anterior view

Dura Mater

Forms loose fitting sleeve around spinal cord // dura mater around brain is fused to periosteum

Dura mater is tough, collagenous membrane with an epidural space between dura mater and periosteum. This space is filled with adipocytes.

An epidural anesthesia is often injected into the epidural space during childbirth.

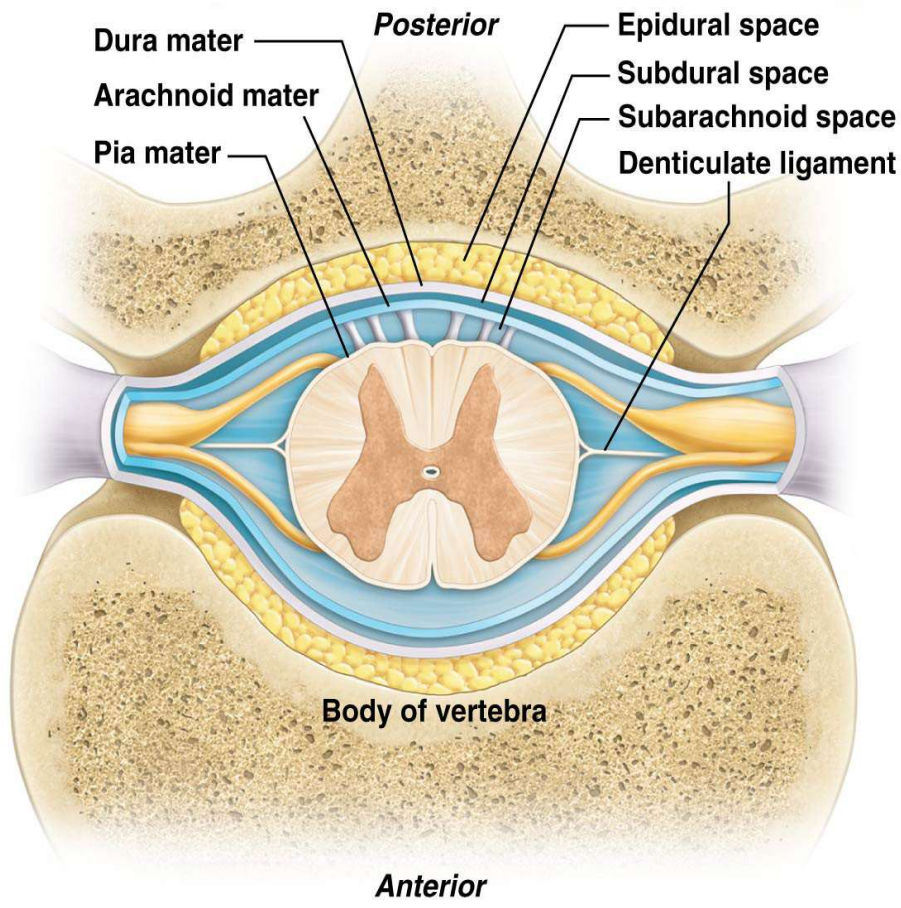

(b) Spinal meninges and spinal cord, transverse section

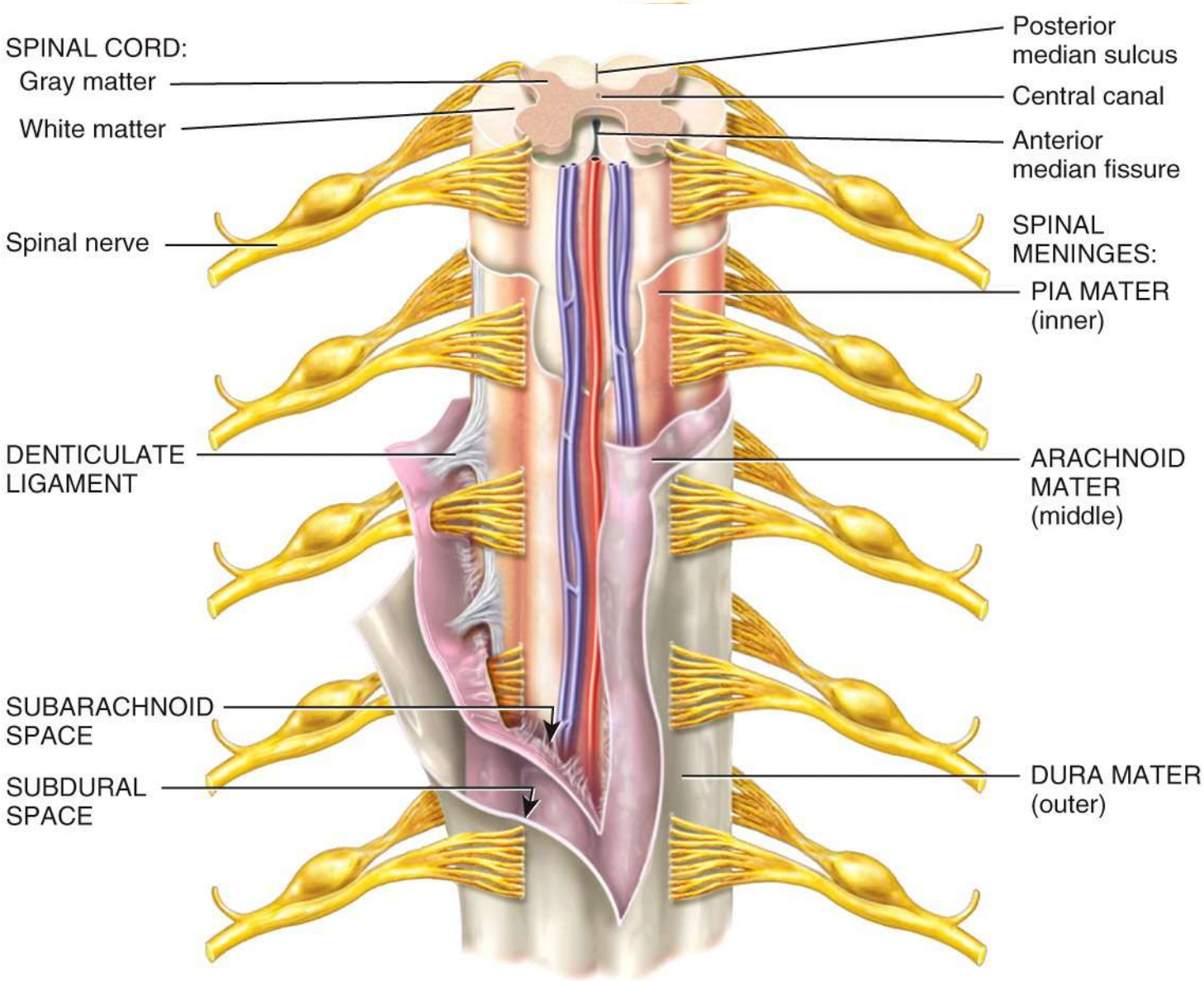

(a) Anterior view and transverse section through spinal cord

Arachnoid Mater

- arachnoid membrane - layer of simple squamous epithelium lining dura mater and a loose mesh of collagenous and elastic fibers spanning the gap between the arachnoid membrane and the pia mater

- subarachnoid space – gap between arachnoid membrane and the pia mater

  - filled with cerebrospinal fluid (CSF)

  - lumbar cistern – subarachnoid space inferior to medullary cone that contains cauda equina and CSF

Meninges of Vertebra and Spinal Cord

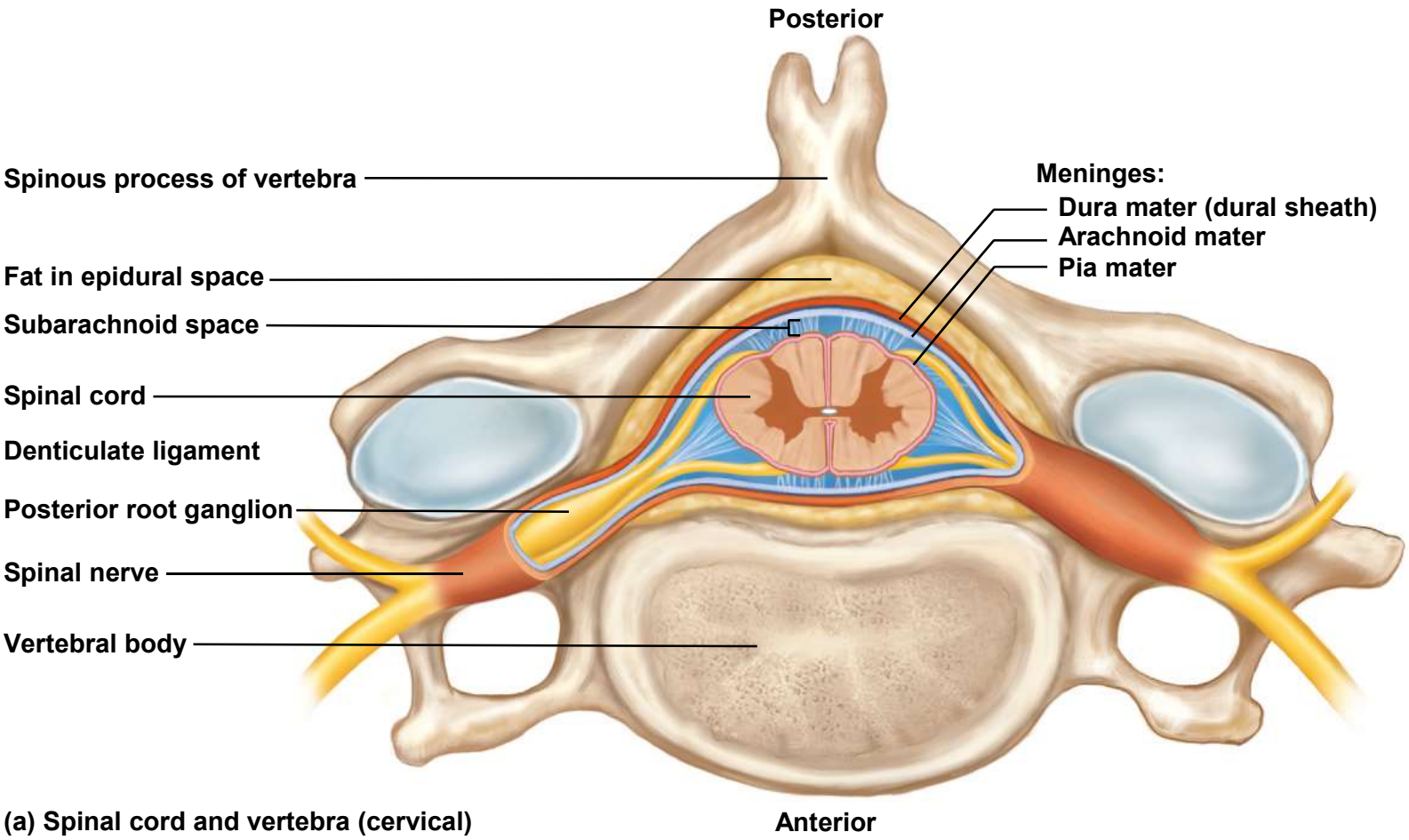

(a) Spinal cord and vertebra (cervical)

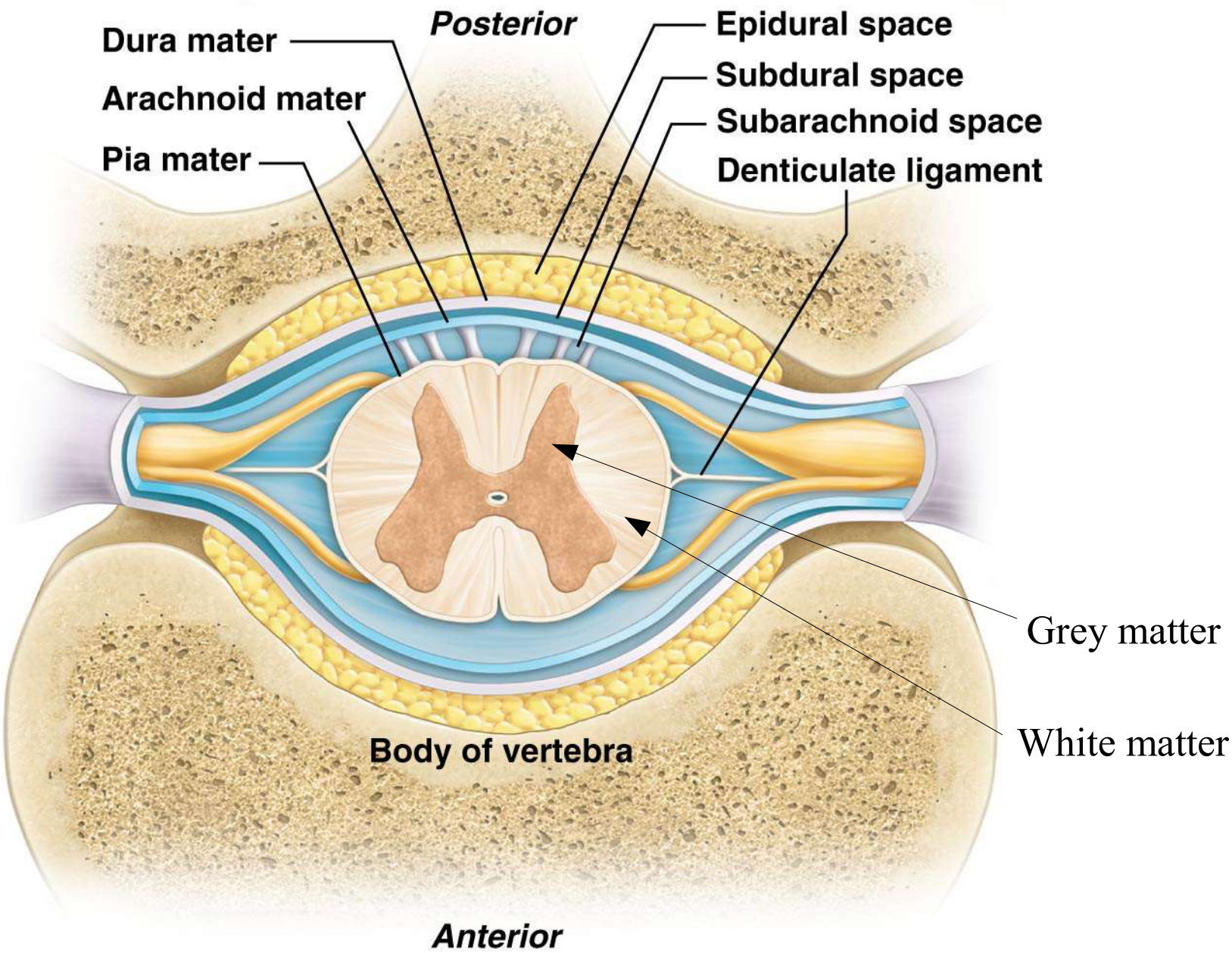

(b) Spinal meninges and spinal cord, transverse section

Pia Mater

- delicate, translucent membrane that follows the contours of the spinal cord
- terminal filum – fibrous strand of pia mater that extends beyond the medullary cone within the lumbar cistern
- coccygeal ligament – formed from fusion of terminal filum and dura mater // anchors the cord and meninges to vertebra Co1
- denticulate ligaments – pia mater extends through the arachnoid mater to the dura mater // anchors spinal cord to limit side to side movement

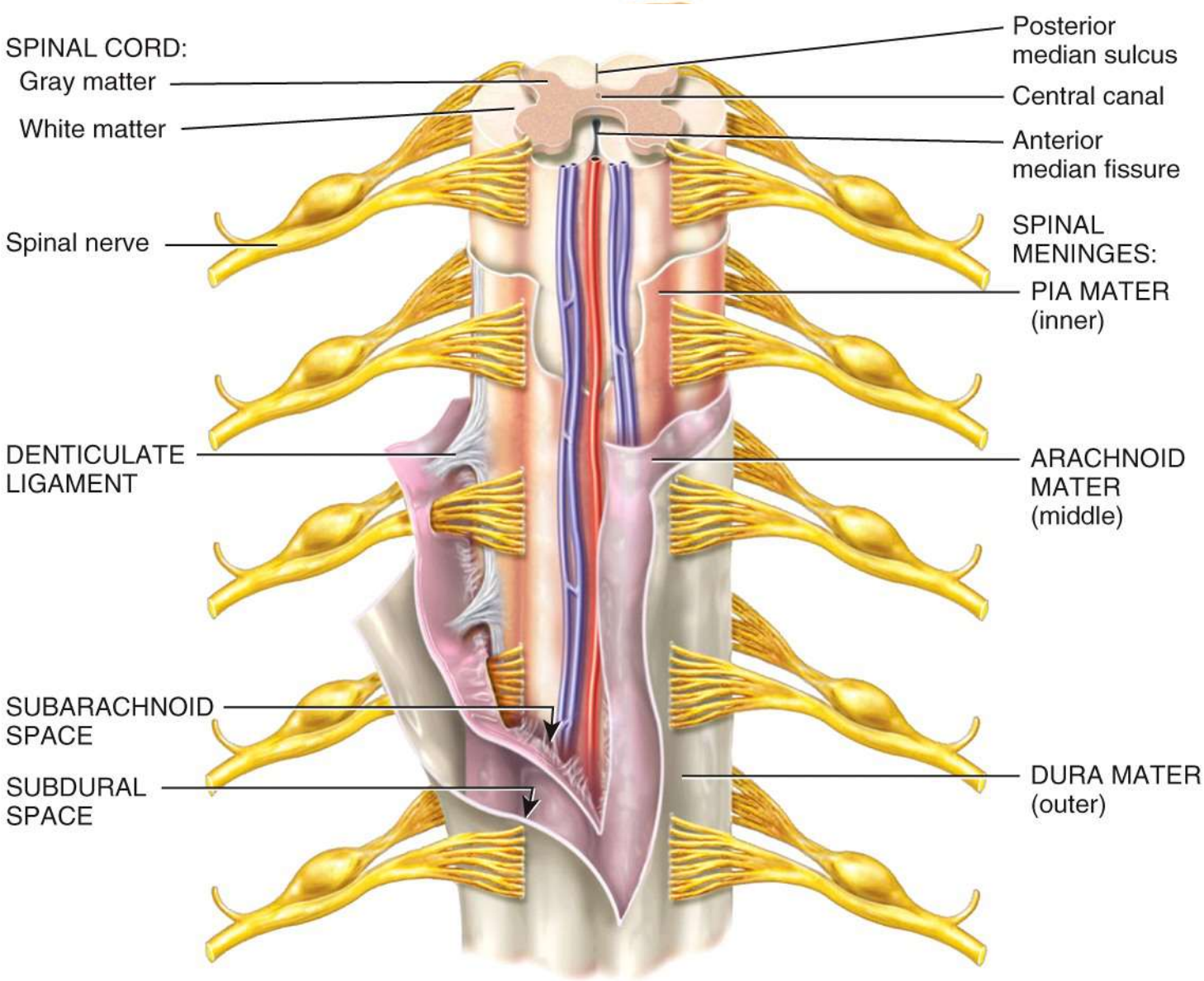

(a) Anterior view and transverse section through spinal cord

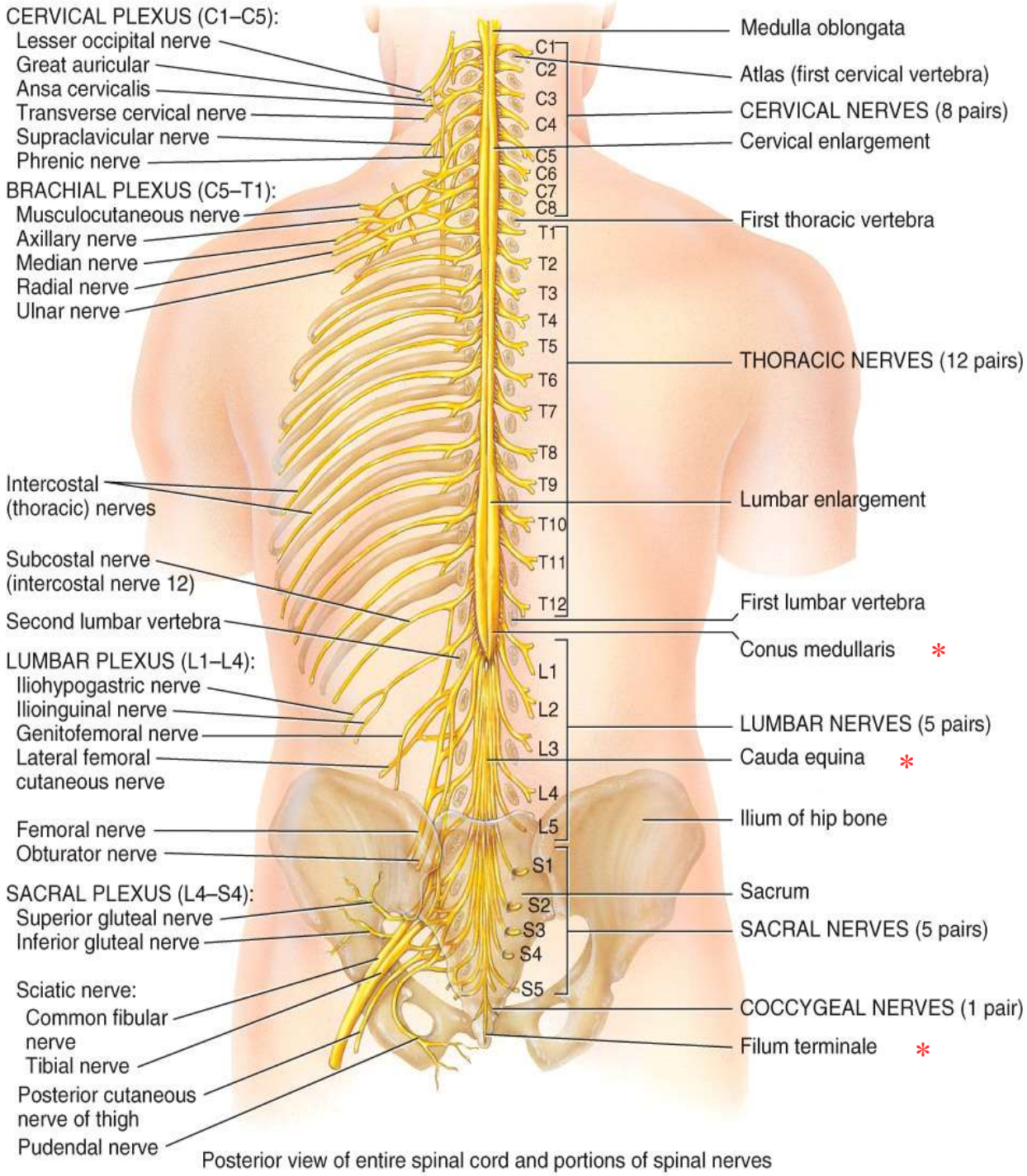

Posterior view of entire spinal cord and portions of spinal nerves

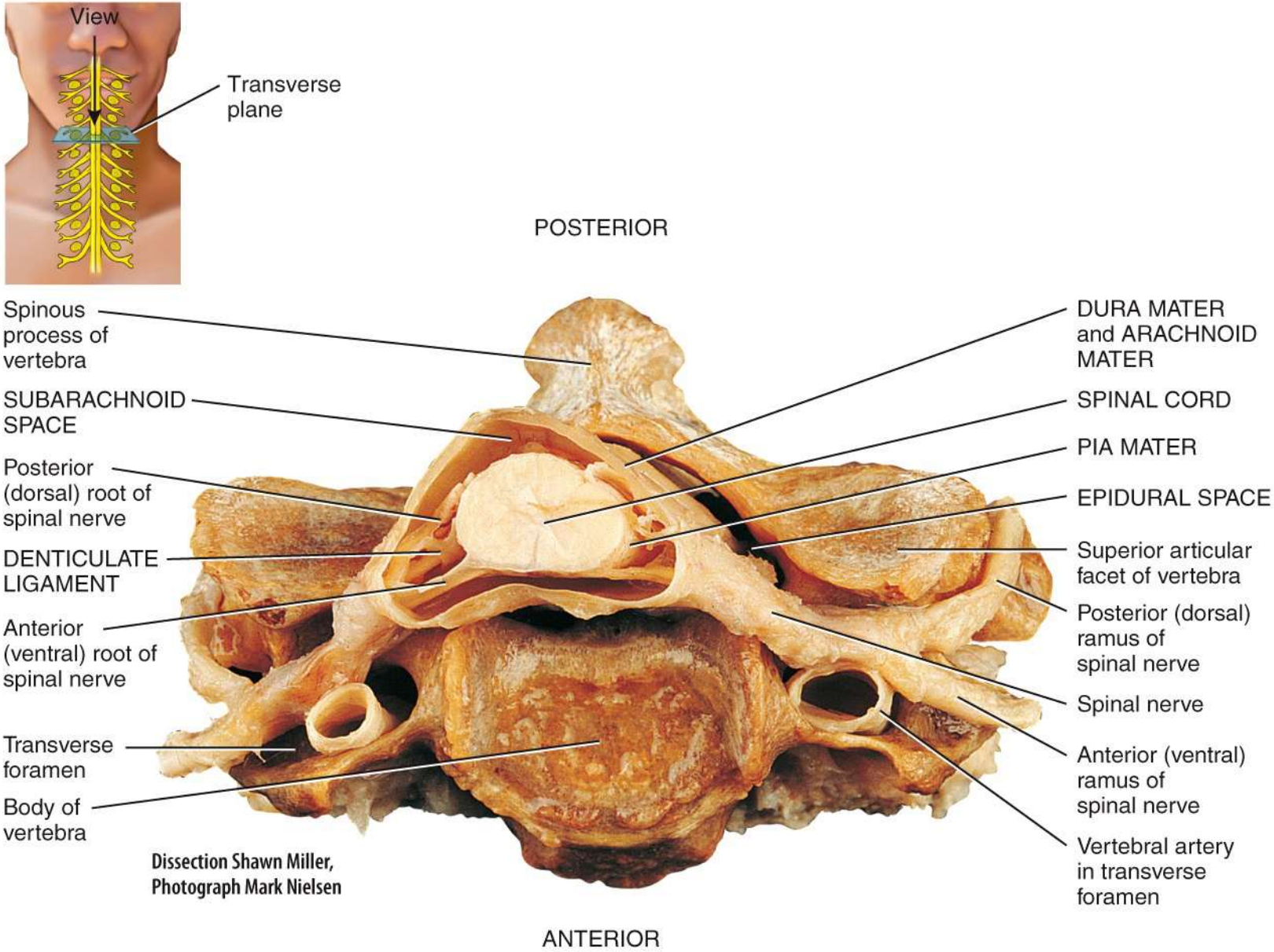

(b) Transverse section of the spinal cord within a cervical vertebra

Grey Matter and White Matter of Spinal Cord

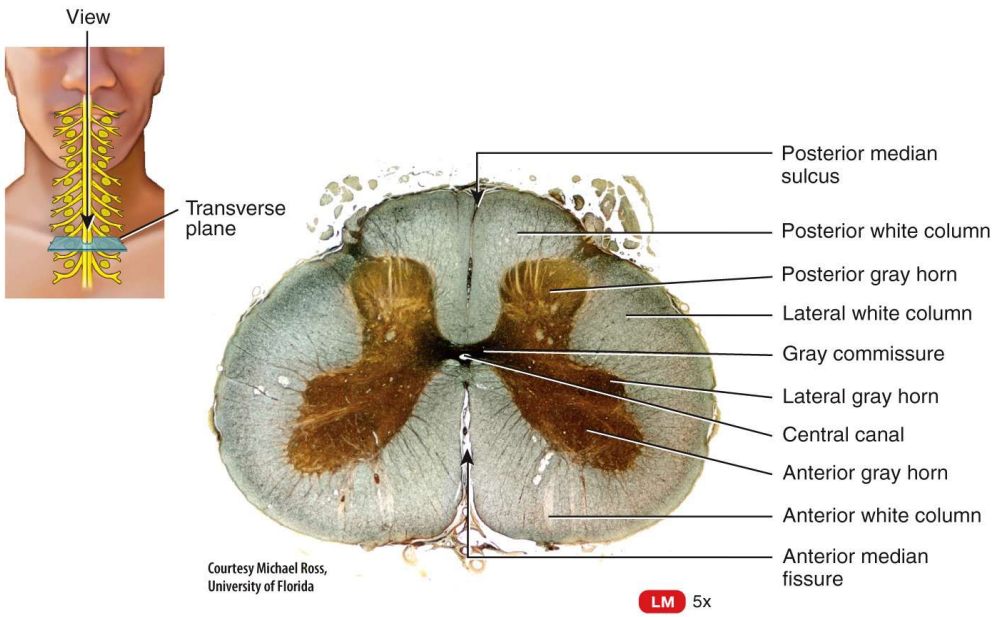

(b) Transverse section of lumbar spinal cord

- central area of gray matter shaped like a butterfly and surrounded by white matter in 3 columns // white areas = tracts

- gray matter - neuron cell bodies with little myelin // site of information processing – synaptic integration // grey matter = horns

- white matter – abundantly myelinated axons // carry signals from one part of the CNS to another

Spinal Cord Horns

Posterior, Anterior, and Lateral

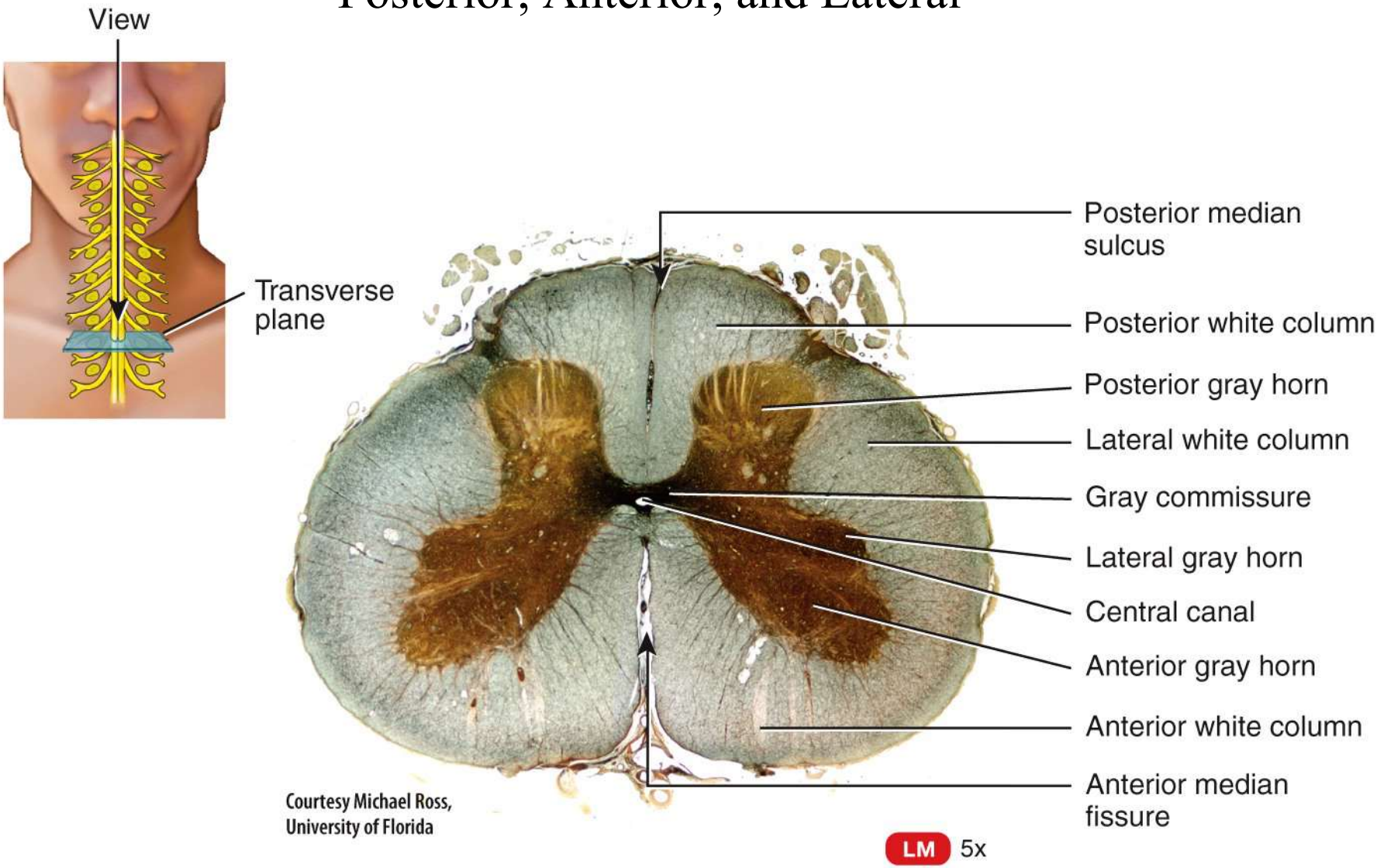

(b) Transverse section of lumbar spinal cord

Spinal Cord Horns

Posterior, Anterior, and Lateral

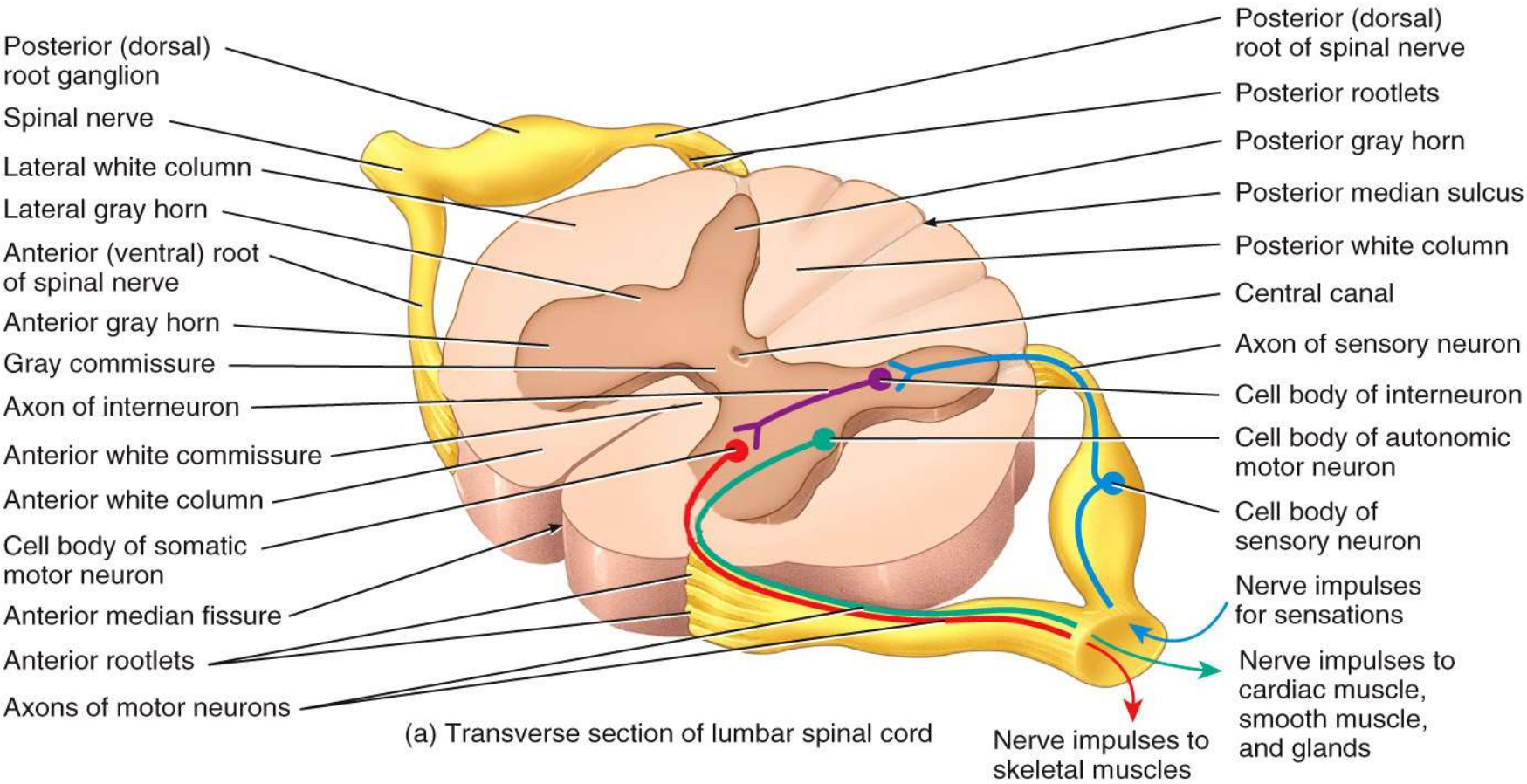

(a) Transverse section of lumbar spinal cord

Functions of the Spinal Cord Horns

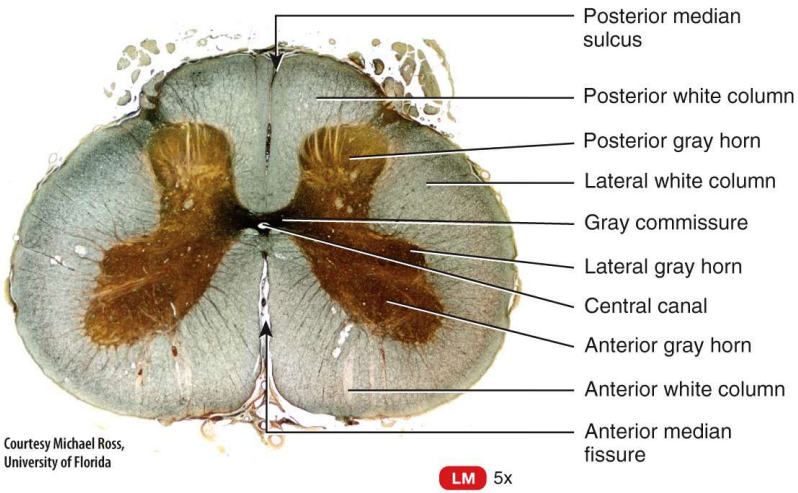

(b) Transverse section of lumbar spinal cord

- **Posterior grey horns / cell bodies and axons of interneurons + incoming sensory neurons form dorsal root ganglion**
- **Anterior grey horns / somatic motor nuclei to skeletal muscles**
- **Lateral grey horns / only in thoracic and upper lumbar / contain autonomic motor nuclei / regulate smooth muscle – cardiac muscle - glands**

Direction of Signal Through Horns

- pair of posterior (dorsal) horns // posterior (dorsal) root of spinal nerve carries only sensory fibers

- pair of thicker anterior (ventral) horns // anterior (ventral) root of spinal nerve carries only motor fibers

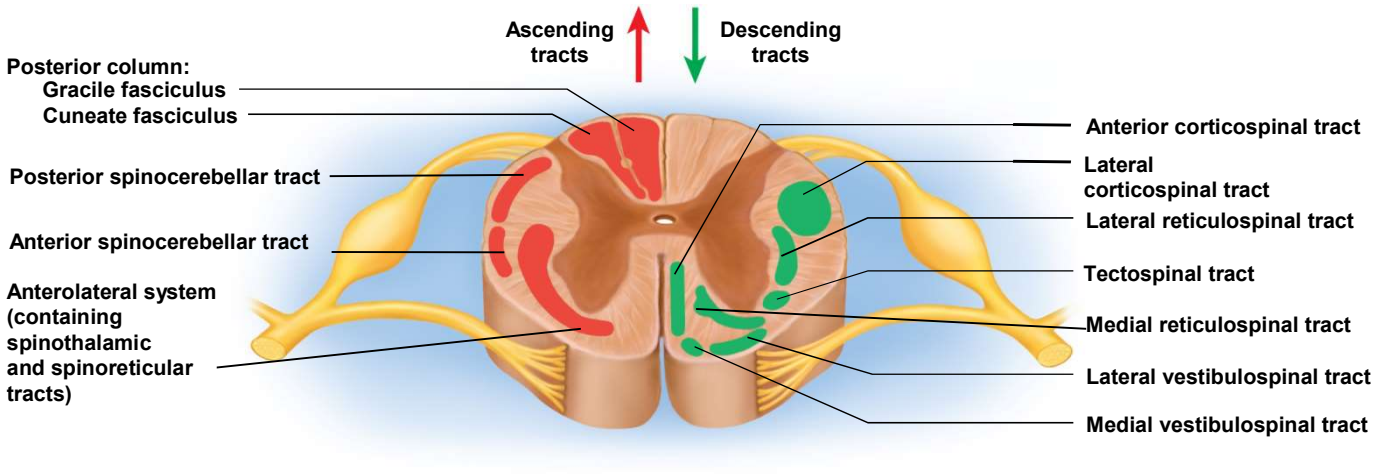

The Function of Commisure and Lateral Horn

- gray commissure connects right and left sides // punctured by a central canal lined with ependymal cells and filled with CSF

- lateral horn = visible from T2 through L1 // contains neurons of sympathetic nervous system

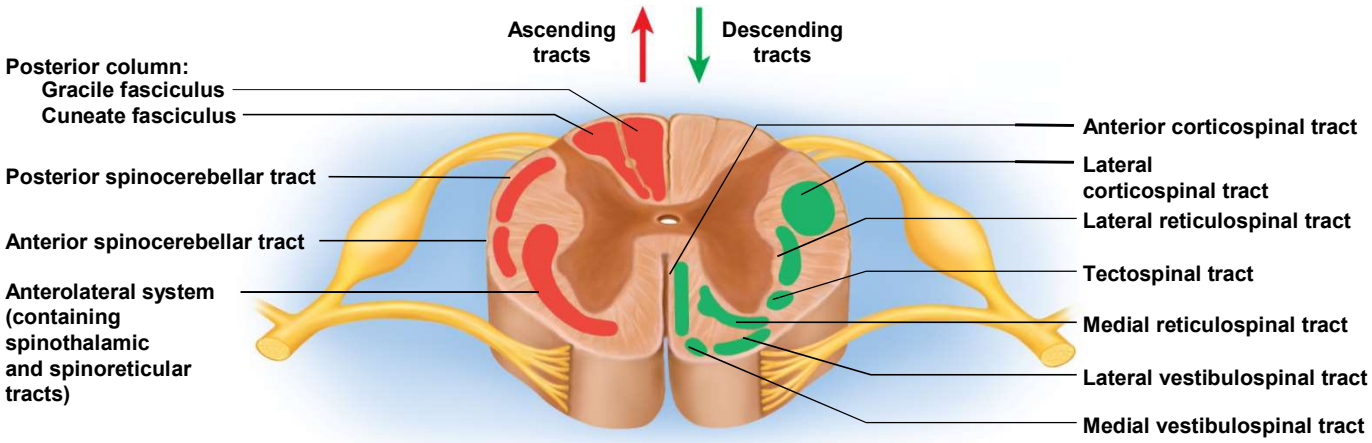

White Matter in the Spinal Cord

- White matter surrounds the gray matter in spinal cord
- White matter is bundles of axons that course up and down the cord (i.e. arranged in fasicles)
- Provide pathway of communication between CNS and PNS target tissues

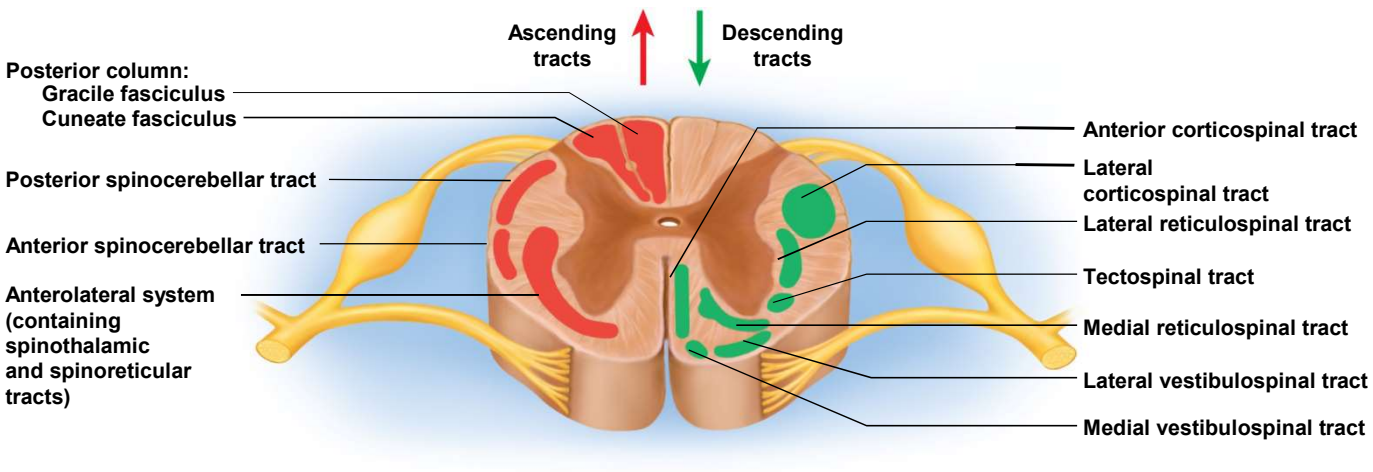

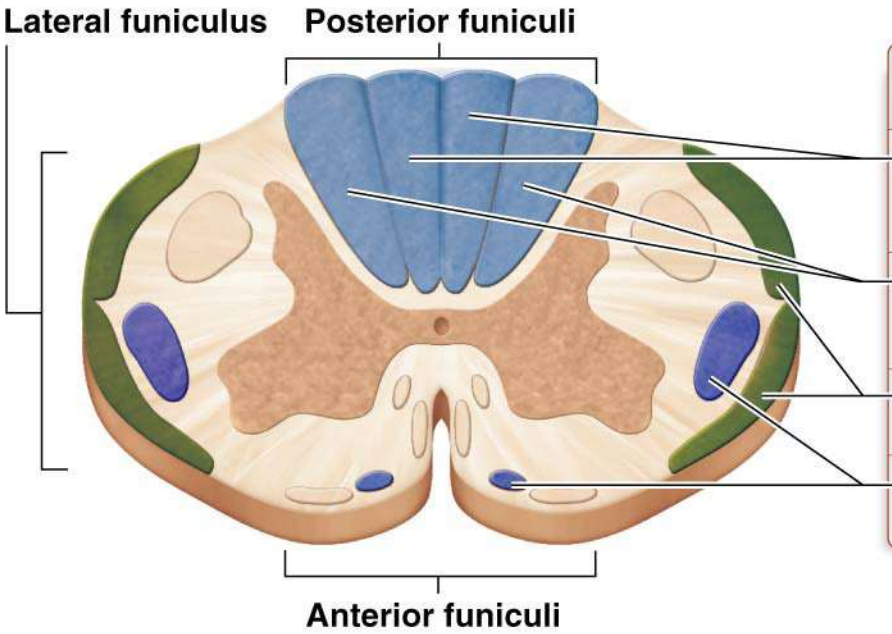

ASCENDING TRACT	FUNCTION
Posterior columns—fasciculus gracilis	• Carry somatosensory information including fine touch, vibration, and proprioception from the lower limbs
Posterior columns—fasciculus cuneatus	• Carry somatosensory information including fine touch, vibration, and proprioception from the trunk, neck, and upper limbs
Spinocerebellar tracts	• Carry proprioceptive information to the cerebellum
Anterolateral system—spinothalamic tracts	• Carry information about pain, temperature, and certain types of touch

(a) Ascending tracts (sensory)

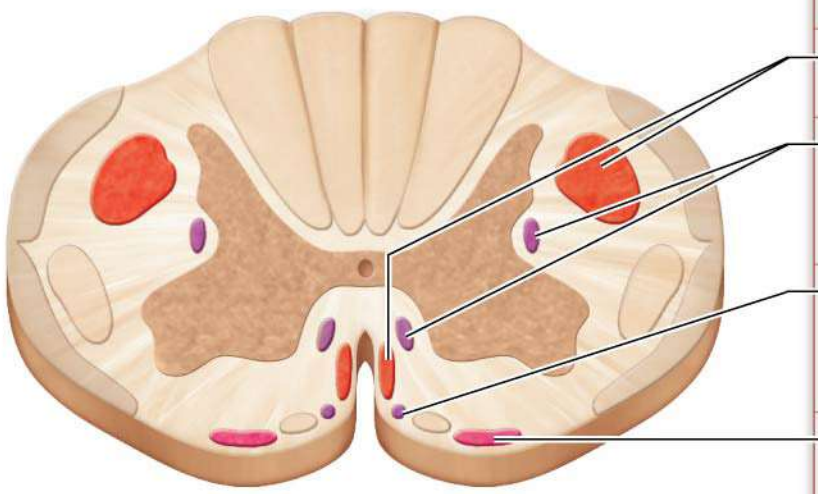

DESCENDING TRACT	FUNCTION
Corticospinal tracts	• Carry motor information from the motor areas of the cerebral cortex
Reticulospinal tracts	• Carry motor information from the brainstem • Important for the maintenance of posture and proper orientation of the limbs during movement
Tectospinal tract	• Carries motor information from the superior colliculus of the brainstem • Important for reflexive movement of the head and eyes
Vestibulospinal tract	• Carries motor information from vestibular nuclei in the brainstem • Important for the maintenance of posture and balance

(b) Descending tracts (motor)

White Matter in the Spinal Cord

- columns or funiculi – three pair of these white matter bundles
    - Posterior columns (dorsal)
    - Lateral columnsl
    - Anterior columns (ventral)
- tracts or fasciculi – subdivisions of each column

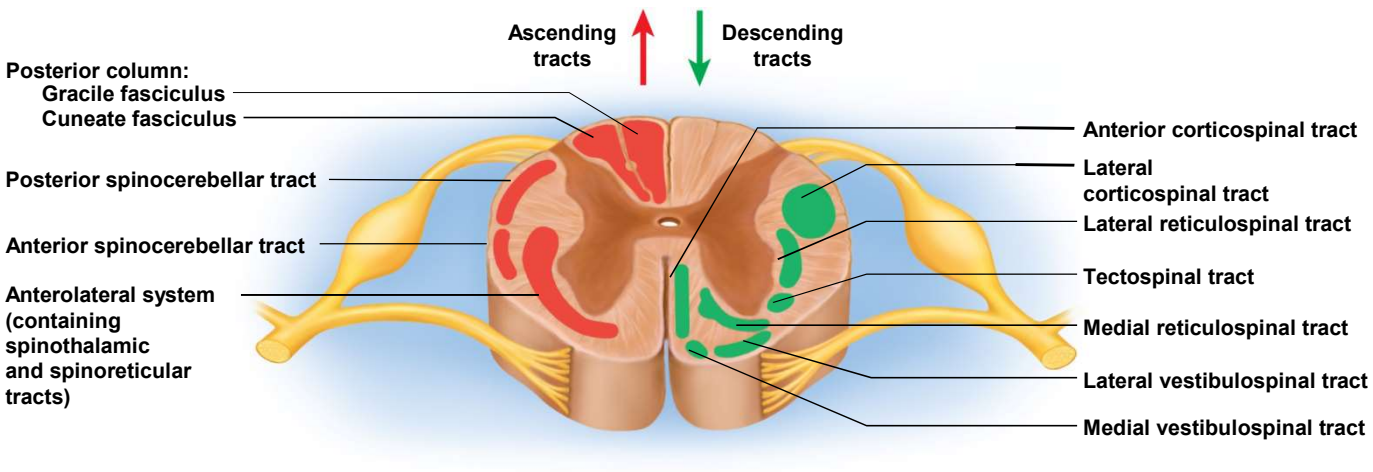

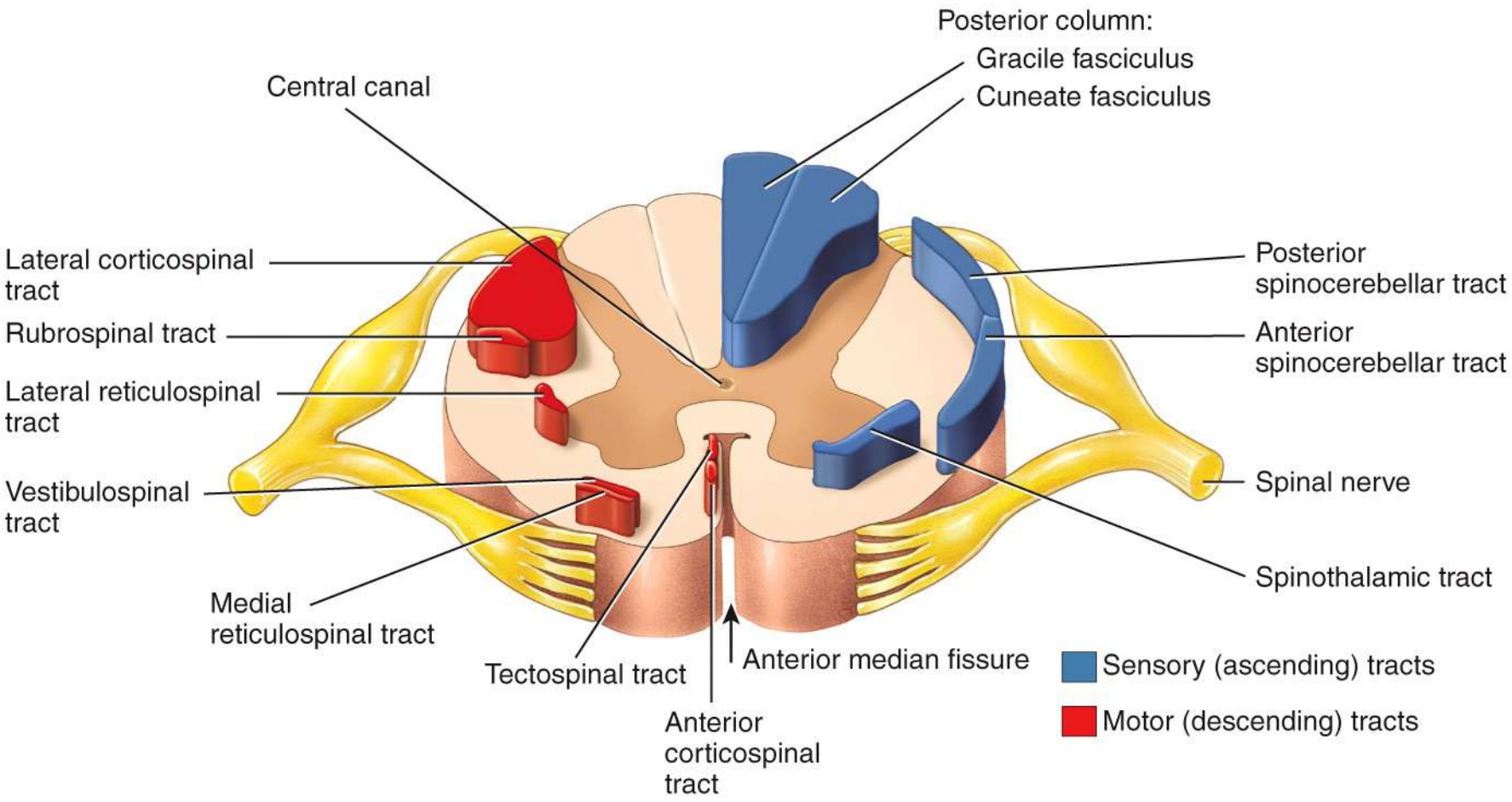
Posterior column:
Gracile fasciculus
Cuneate fasciculus
Central canal
Lateral corticospinal tract
Rubrospinal tract
Lateral reticulospinal tract
Vestibulospinal tract
Medial reticulospinal tract
Tectospinal tract
Anterior corticospinal tract
Anterior median fissure
Posterior spinocerebellar tract
Anterior spinocerebellar tract
Spinal nerve
Spinothalamic tract
Sensory (ascending) tracts
Motor (descending) tracts

Spinal Tracts

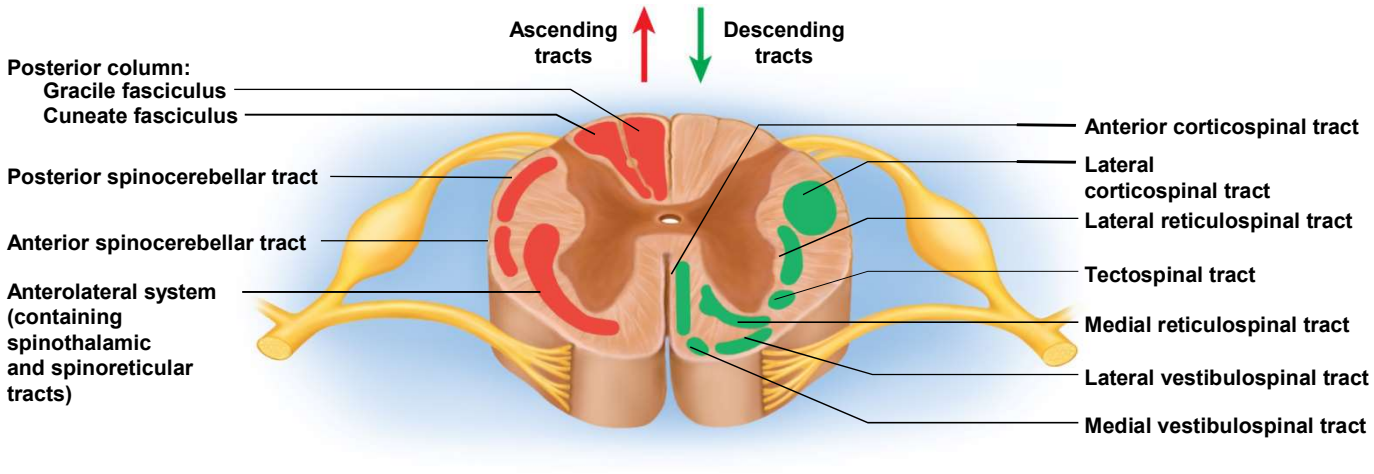

- ascending tracts – carry sensory information up the spinal cord

- descending tracts – carry motor information down the spinal cord // all nerve fibers in a given tract have a similar origin, destination, and function

- decussation – as the fibers pass up or down the brainstem and spinal cord they cross over from the left to the right side and vise versa

Spinal Tracts

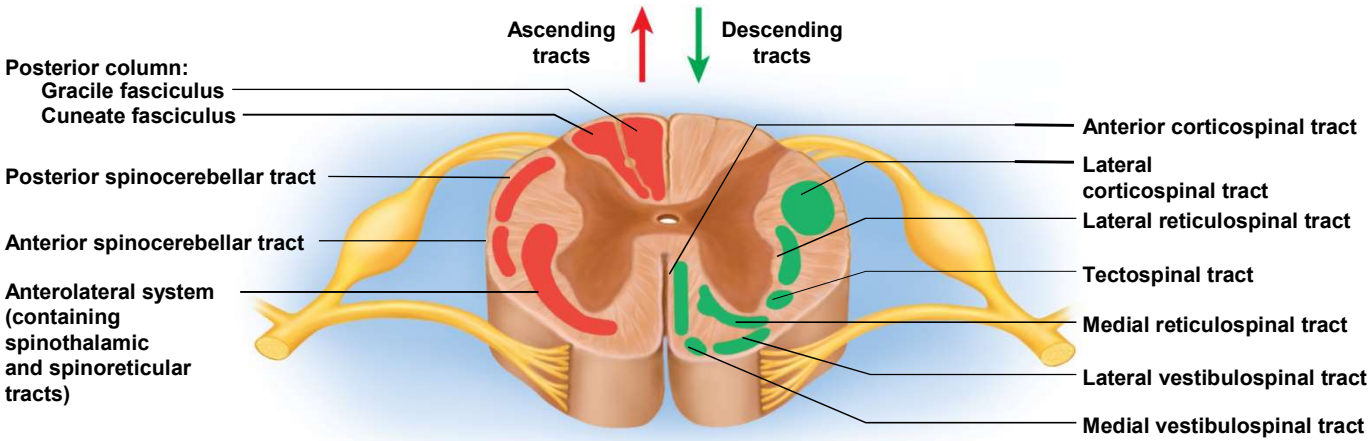

- contralateral – when the origin and destination of a tract are on opposite sides of the body

- ipsilateral – when the origin and destination of a tract are on the same side of the body // does not decussate

Ascending Tracts

- ascending tracts carry sensory signals up the spinal cord // sensory to the brain
- sensory signals travel across three neurons from origin in receptors to the destination in the sensory areas of the brain // typical pattern
  - first order neurons – detect stimulus and transmit signal to spinal cord or brainstem
  - second order neurons – continues to the thalamus at the upper end of the brainstem
  - third order neurons – carries the signal the rest of the way to the sensory region of the cerebral cortex

Major Ascending Tracts

- cuneate fasciculus (above T6)
- gracile fasciculus (below T6)
- spinothalamic tract
- spinoreticular tract
- spinocerebellar tracts - posterior and anterior

Cuneate Fasciculus

- originate at the level of T6 and above // upper limb and chest
- joins gracile fasciculus at T6
- occupies lateral portion of the posterior column // forces gracile fasciculus medially
- these are somatosensory (somesthetic) which are consious signals
- carries signals for vibration, visceral pain, deep and discriminative touch, and proprioception from lower limbs and lower trunk
- fibers end in the cuneate nucleus on the ipsilateral side of the medulla oblongata
- proprioception = non-visual sense of the position and movements of the body / conscious

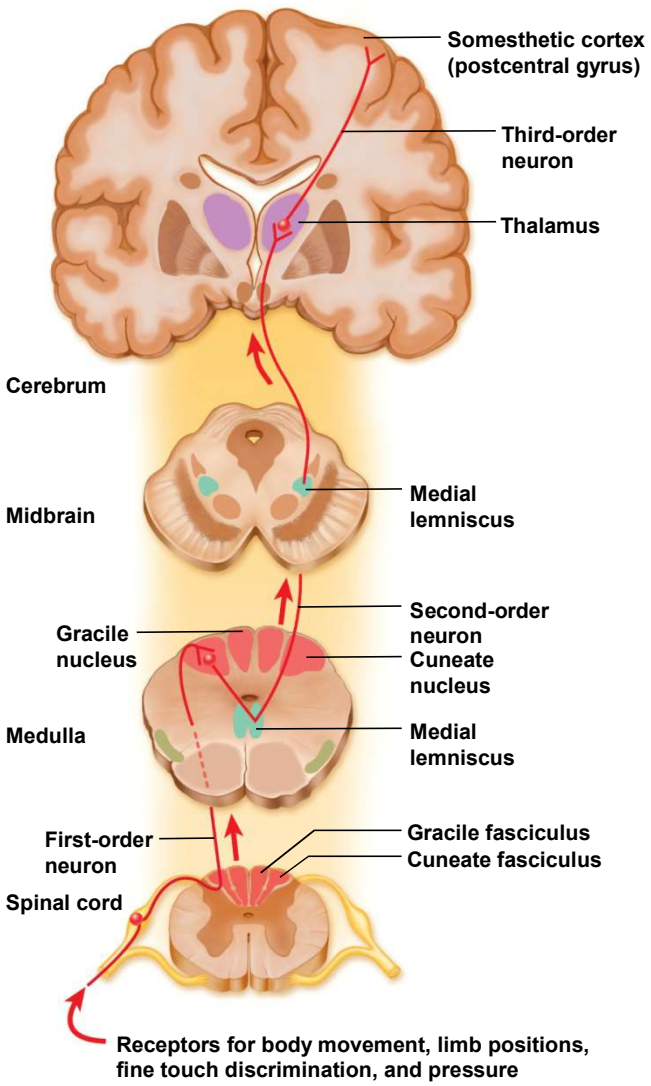

Gracile Fasciculus

- carries signals from midthoracic and lower parts of the body
- below T6, it composes the entire posterior column // at T6 joins cuneate fasciculus
- consists of first-order nerve fibers that travel up the ipsilateral side of the spinal cord
- terminates at the gracile nucleus of the medulla oblongata
- carries signals for vibration, visceral pain, deep and discriminative touch, and proprioception from lower limbs and lower trunk
- proprioception – non-visual sense of the position and movements of the body / conscious

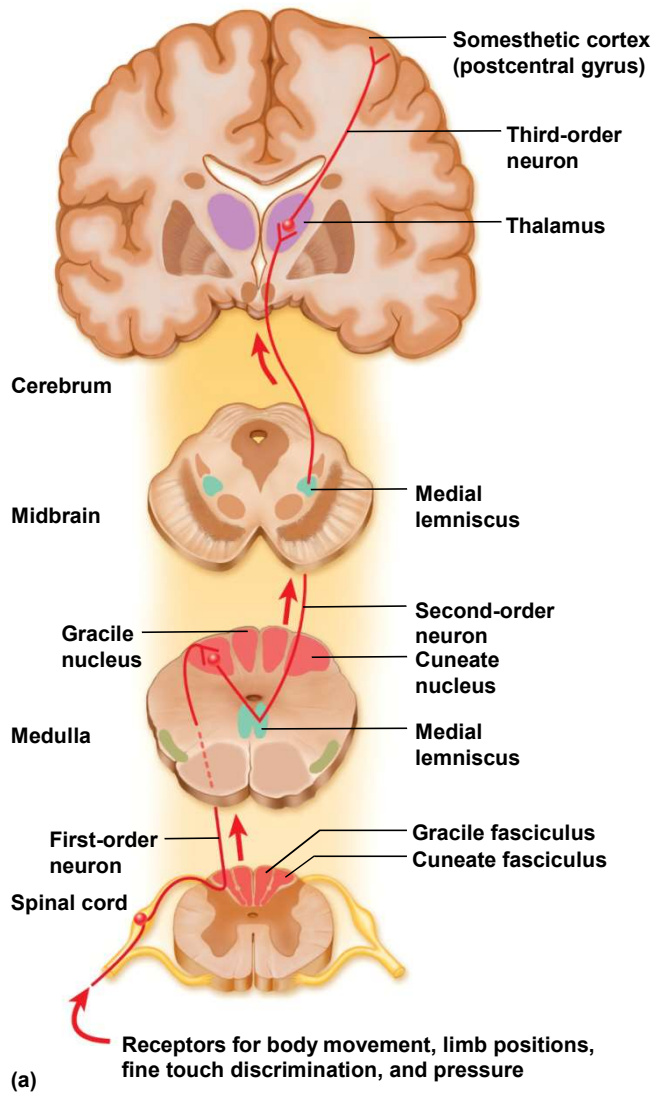

Medial Lemniscus

- medial lemniscus // formed from the second-order neurons of gracile and cuneate systems that decussate in the medulla
  - tracts of these nerve fibers lead the rest of the way to the thalamus
  - third-order neurons go from thalamus to cerebral cortex
  - carry signals to contralateral cerebral hemisphere

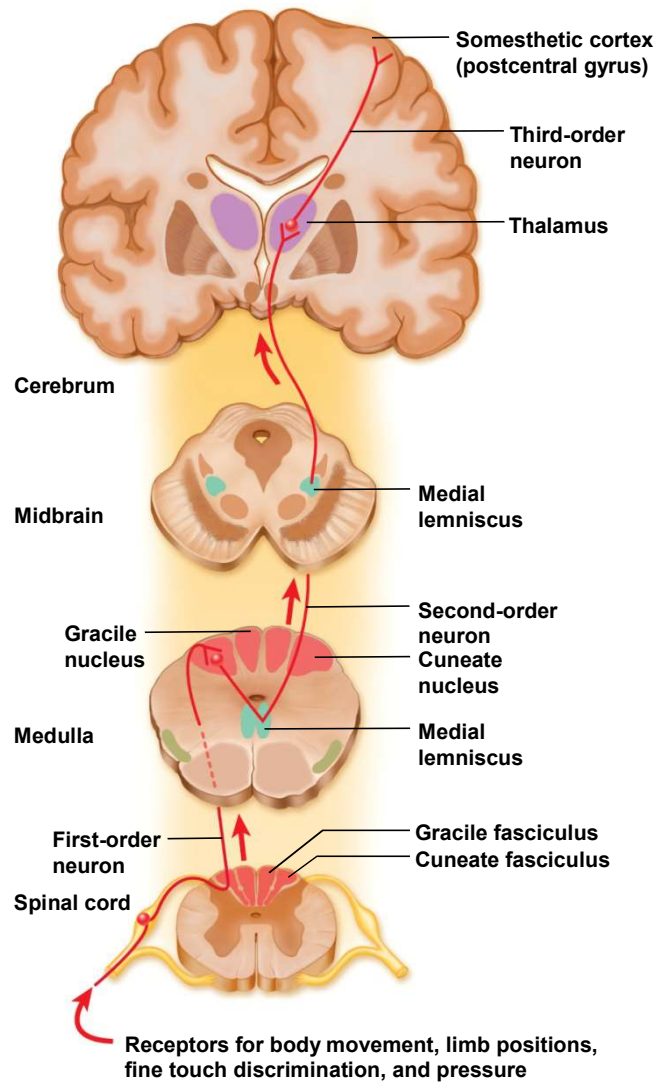

Spinothalamic Pathway

- one of the smaller tracts of the anterolateral system /// passes up the anterior and lateral columns of the spinal cord
- carry signals for pain, pressure, temperature, light touch, tickle, and itch
- first-order neurons end in posterior horn of spinal cord
- synapse with second-order neurons which decussate to other side of spinal cord and form the ascending spinothalamic tract that goes to the thalamus
- third-order neurons continue from there to cerebral cortex
- sends signals to the contralateral cerebral hemisphere
- these are also conscious signals

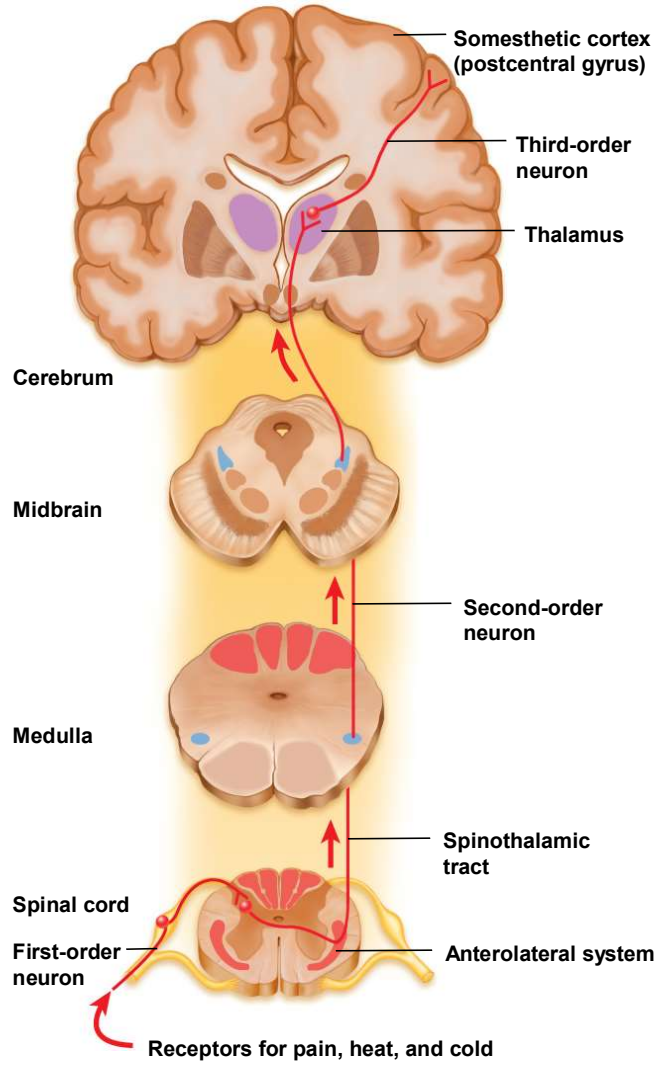

(b)

Spinoreticular Tract

- travel up the anterolateral system
- carries pain signals resulting from tissue injury
- first-order neurons enter posterior horn and immediately synapse with second-order neurons
- decussate to opposite anterolateral system
  - ascends the cord // end in reticular formation – loosely organized core of gray matter in the medulla and pons
- *third-order neurons* continue from the pons to the thalamus
- *fourth-order neurons* complete the path to the cerebral cortex (Note: exception to the rule!)

Spinocerebellar Tracts

- travel through lateral column
- carry proprioceptive signals from limbs and trunk to the cerebellum
- first-order neurons originate in the muscles and tendons // end in posterior horn of the spinal cord
- second-order nerves ascend spinocerebellar tracts and end in cerebellum
  - fibers of the posterior tract travel up the ipsilateral side of the spinal cord
  - fibers of the anterior tract cross over and travel up the contralateral side // cross back in the brainstem to enter the ipsilateral side of the cerebellum
- provide cerebellum with feedback needed to coordinate muscle actions // **subconscious knowledge** of muscle's actual performance

Descending Tracts

- Carry motor signals down the brainstem and spinal cord // direct and indirect motor pathways (pyramidal and extrapyramidal)

- Involves two neurons

  - upper motor neuron // originate in cerebral cortex or brainstem // terminates on a lower motor neuron

  - lower motor neuron // originate in brainstem or spinal cord // the upper motor neuron synapse on LMN that leads the rest of the way to the muscle or other target organ

Descending Tracts

- Carry motor signals down the brainstem and spinal cord // direct and indirect motor pathways (pyramidal and extrapyramidal)
- Direct pathways (consist of upper and lower motor neurons)
  - Corticospinal = upper motor neuron / synapse with anterior horn neurons = lower motor neuron
  - Corticobulbar = upper motor neuron / synapse with cranial nerves = lower motor neuron / innervate skeletal muscles in head and neck
- Indirect pathways
  - Involved in the involuntary responses to skeletal muscles / visual, equilibrium, posture
  - Tectospinal / vestibulospinal / rubriospinal / reticularspinal tracts

Descending Direct Pathways

Pathways = Axon Tracts

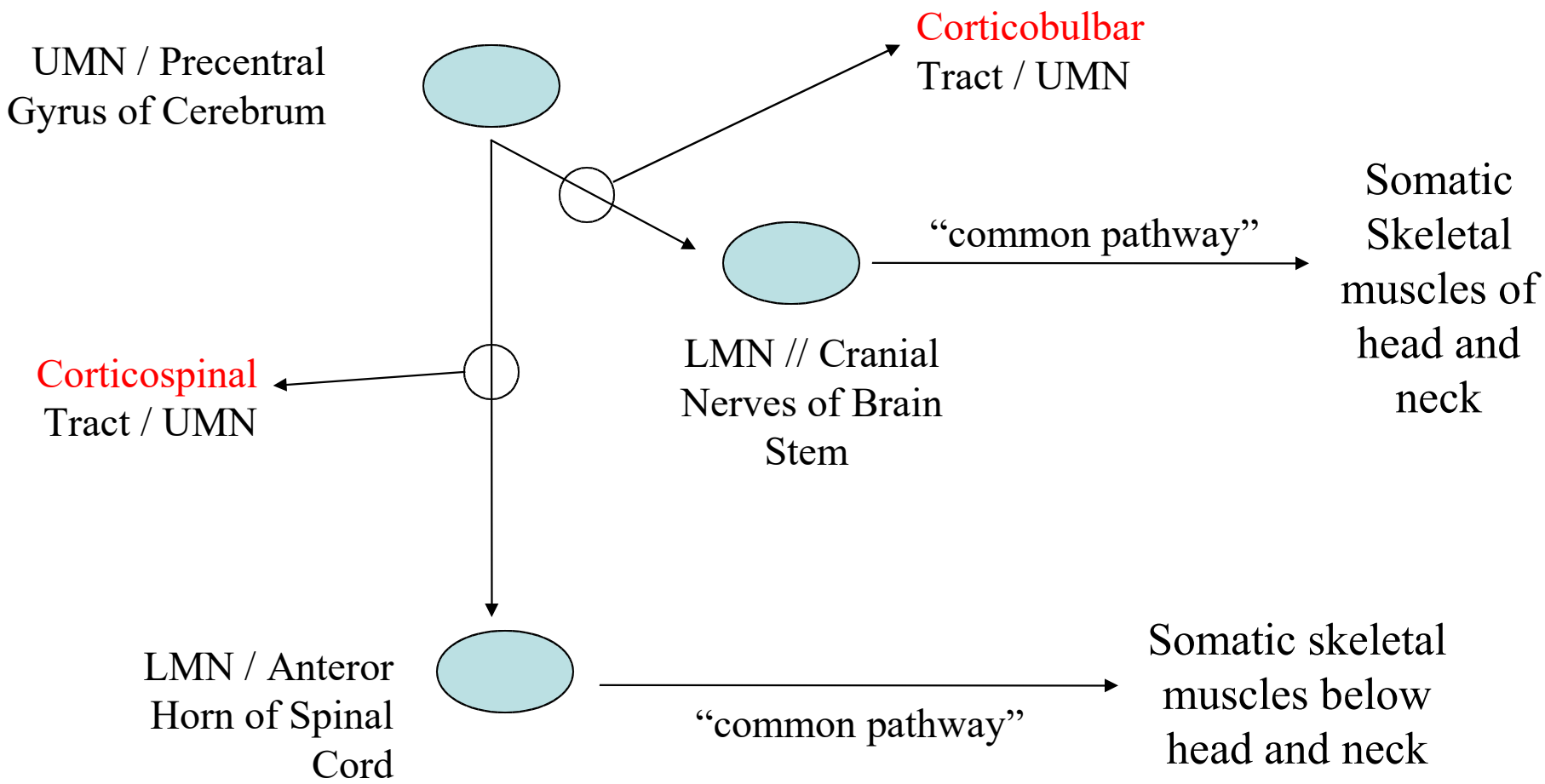

Corticospinal Tracts

- from cerebral cortex for precise, finely coordinated limb movements
- pyramids – ridges on anterior surface of the medulla oblongata formed from fibers of this system
- decussate in lower medulla

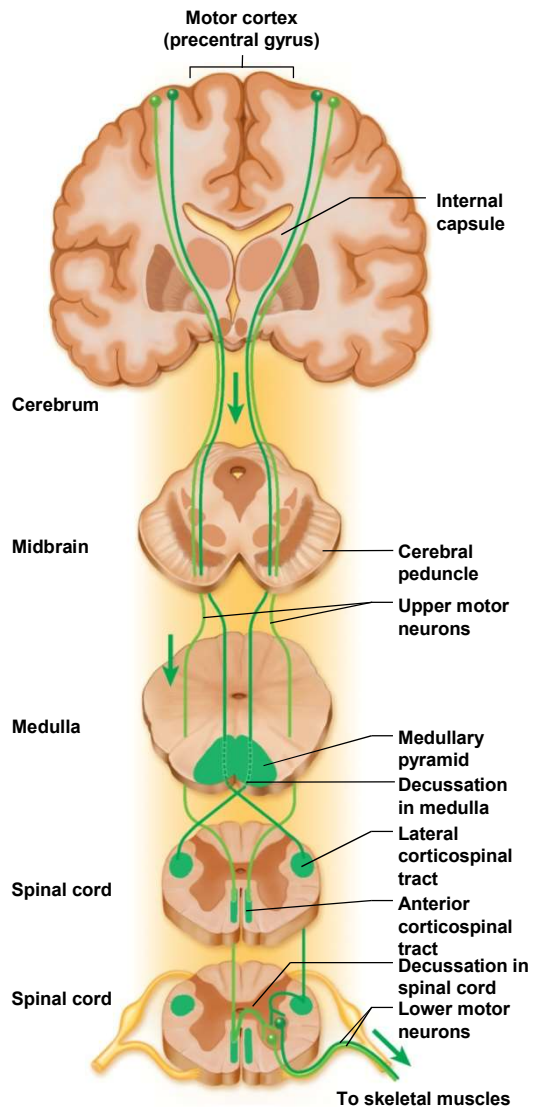

Corticospinal Tracts

- lateral corticospinal tract on contralateral side of spinal cord
- anterior (ventral) corticospinal tract on ipsilateral side of spinal cord
- two neuron pathway
  - upper motor neuron in cerebral cortex
  - lower motor neuron in spinal cord

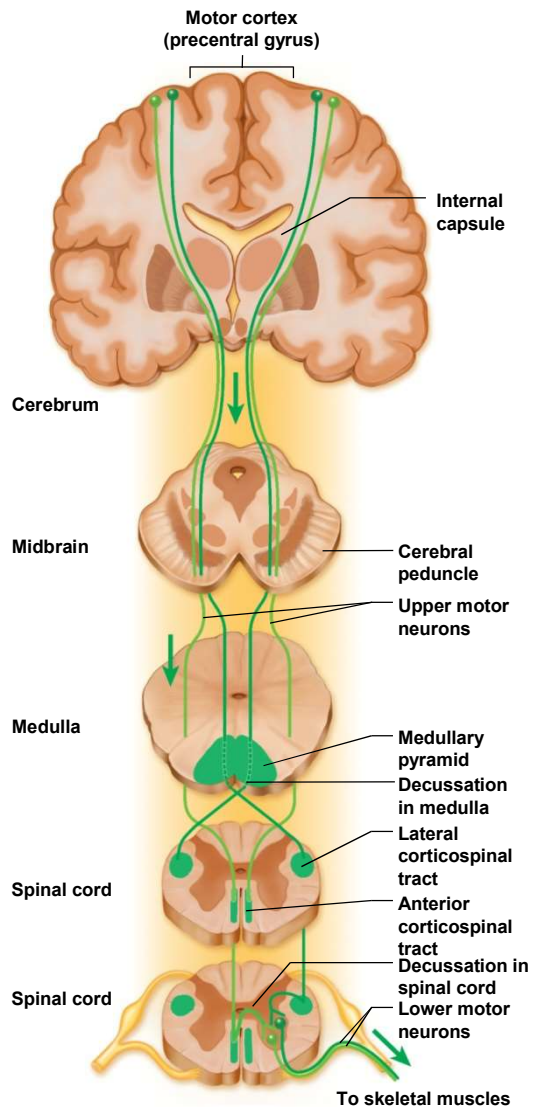

Descending Indirect Pathways

Pathways = Axon Tracts

UMN // **Nuclei in medulla oblongata**

1. tectospinal tract
2. vestibulospinal tract
3. rubriospinal tract
4. reticularspinal tract

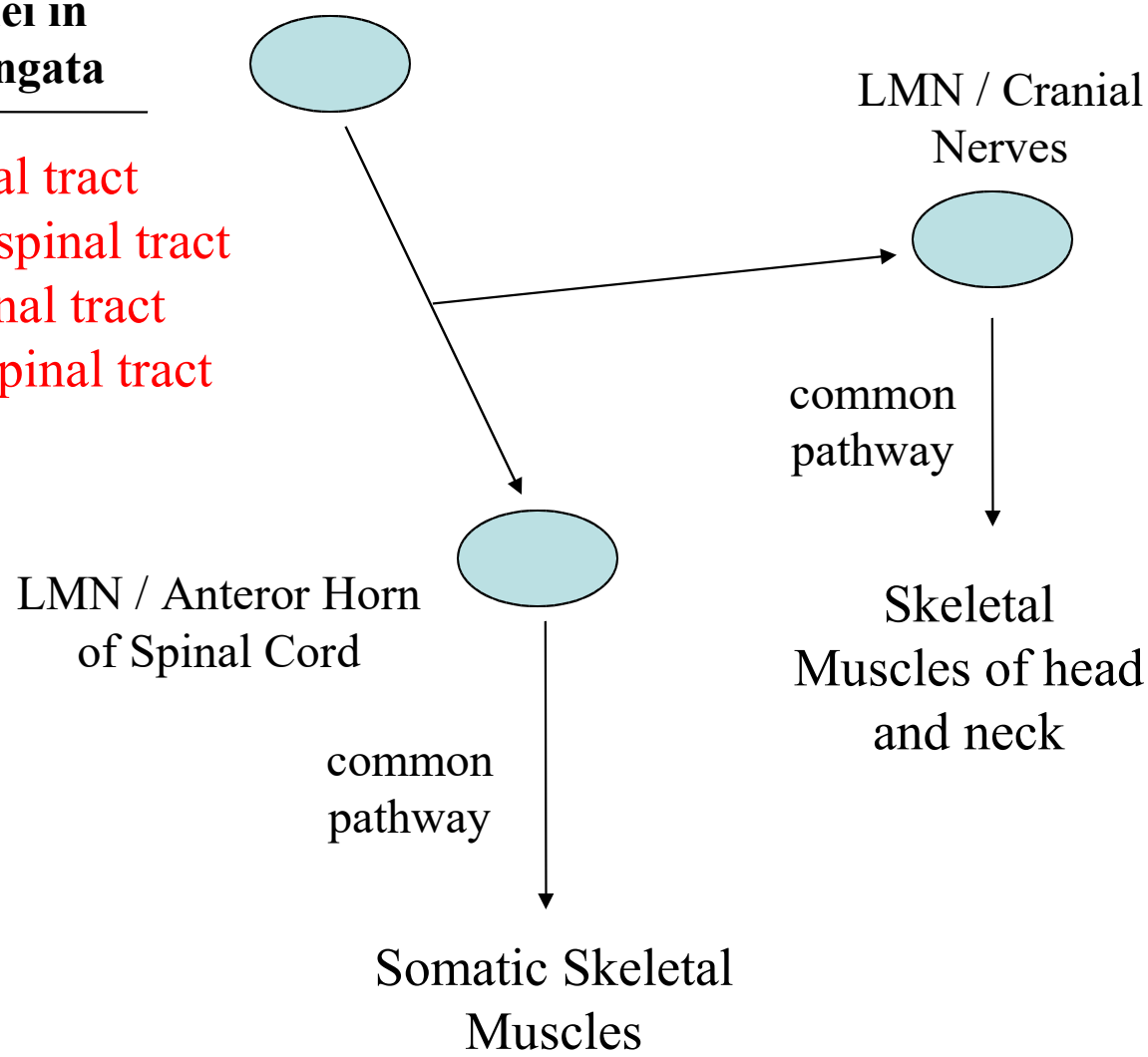

Indirect Motor Tracts

- tectospinal tract – begins in midbrain region (tectum)
  - crosses to contralateral side of midbrain
  - reflex turning of head in response to sights and sounds

- lateral and medial reticulospinal tract
  - originate in the reticular formation of brainstem
  - controls muscles of upper and lower limbs // especially those for posture and balance
  - contain descending analgesic pathways // reduce the transmission of pain signals to brain

Indirect Motor Tracts

- **Lateral** and **medial** **vestibulospinal tract**
  - begins in brainstem **vestibular nuclei**
  - receives impulses form vestibular organs of balance from inner ear
  - controls extensor muscles of limbs for balance control
  - The tripping response!

Damage to Spinal Cord

- accidents damage the spinal cord of thousands of people every year
  - paraplegia - paralysis of lower limbs
  - quadriplegia – paralysis of all four limbs
  - hemiplegia – paralysis of one side of the body only
  - respiratory paralysis - loss of sensation or motor control
  - disorders of bladder, bowel and sexual function
- damage to spinal cord also occur from strokes or other brain injuries

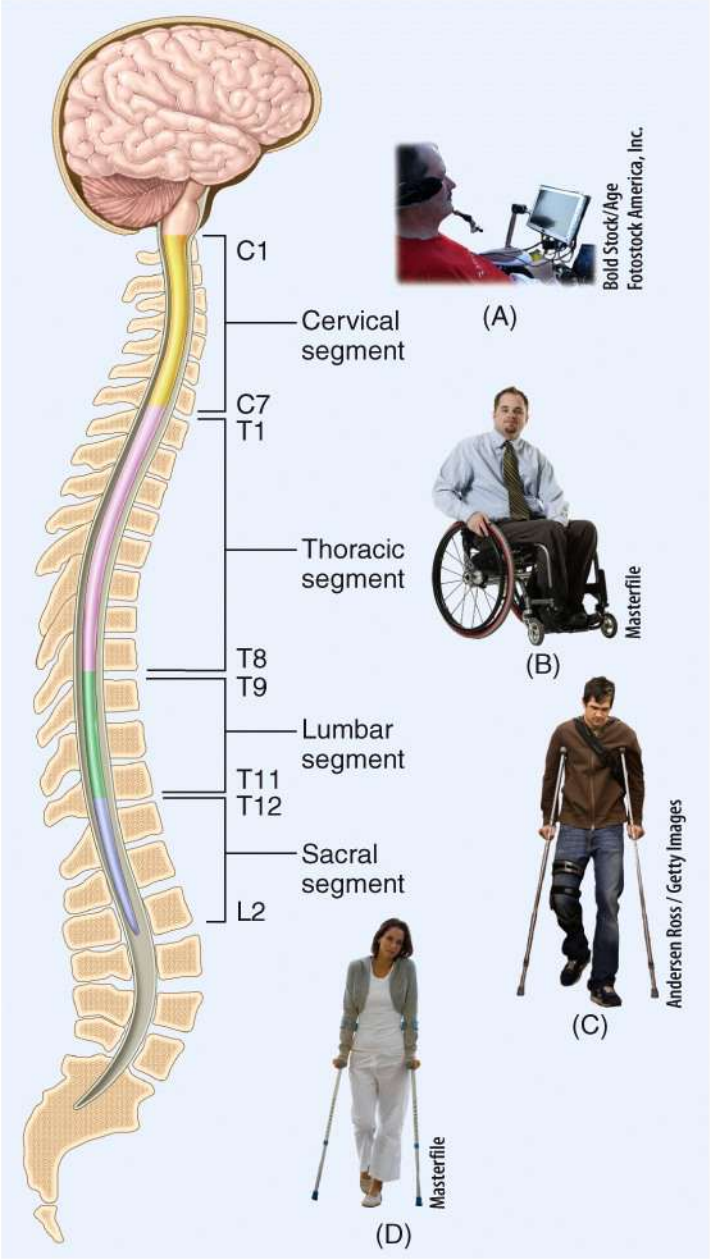
C1
Cervical segment
C7
T1
Thoracic segment
T8
T9
Lumbar segment
T11
T12
Sacral segment
L2
(A)
Bold Stock/Age Fotostock America, Inc.
(B)
Masterfile
(C)
Andersen Ross / Getty Images
(D)
Masterfile

Spina Bifida

- spina bifida – congenital defect in which one or more vertebrae fail to form a complete vertebral arch for enclosure of the spinal cord
  - in 1 baby out of 1000
  - common in lumbosacral region
  - spina bifida occulta and spina bifida cystica
- folic acid (a B vitamin) as part of a healthy diet for all women of childbearing age reduces risk
  - defect occurs during the first four weeks of development, so folic acid supplementation must begin 3 months before conception

Bi-Directional Pathways of Action Potentials Between the PNS, Spinal Cord, and Brain

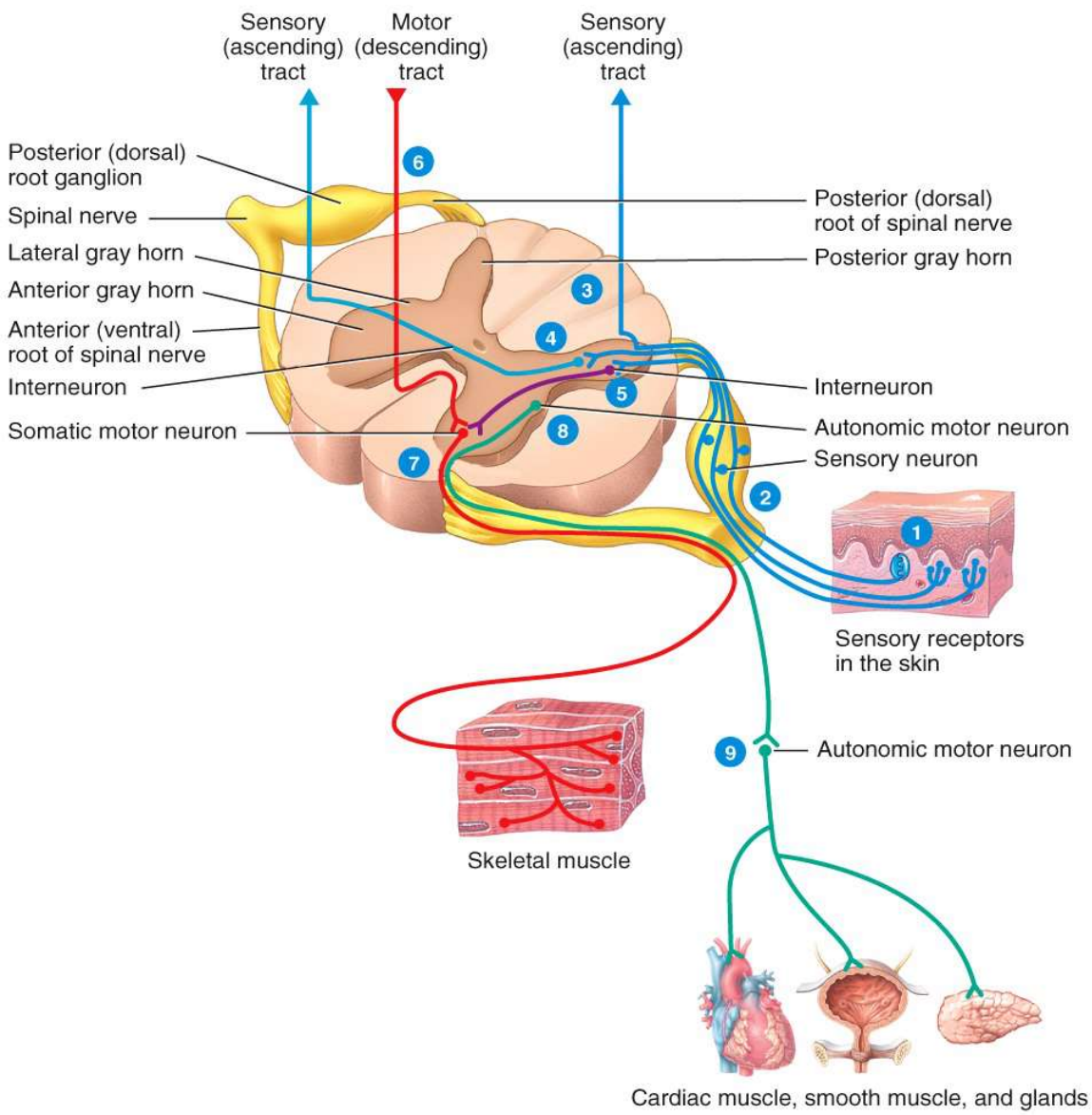

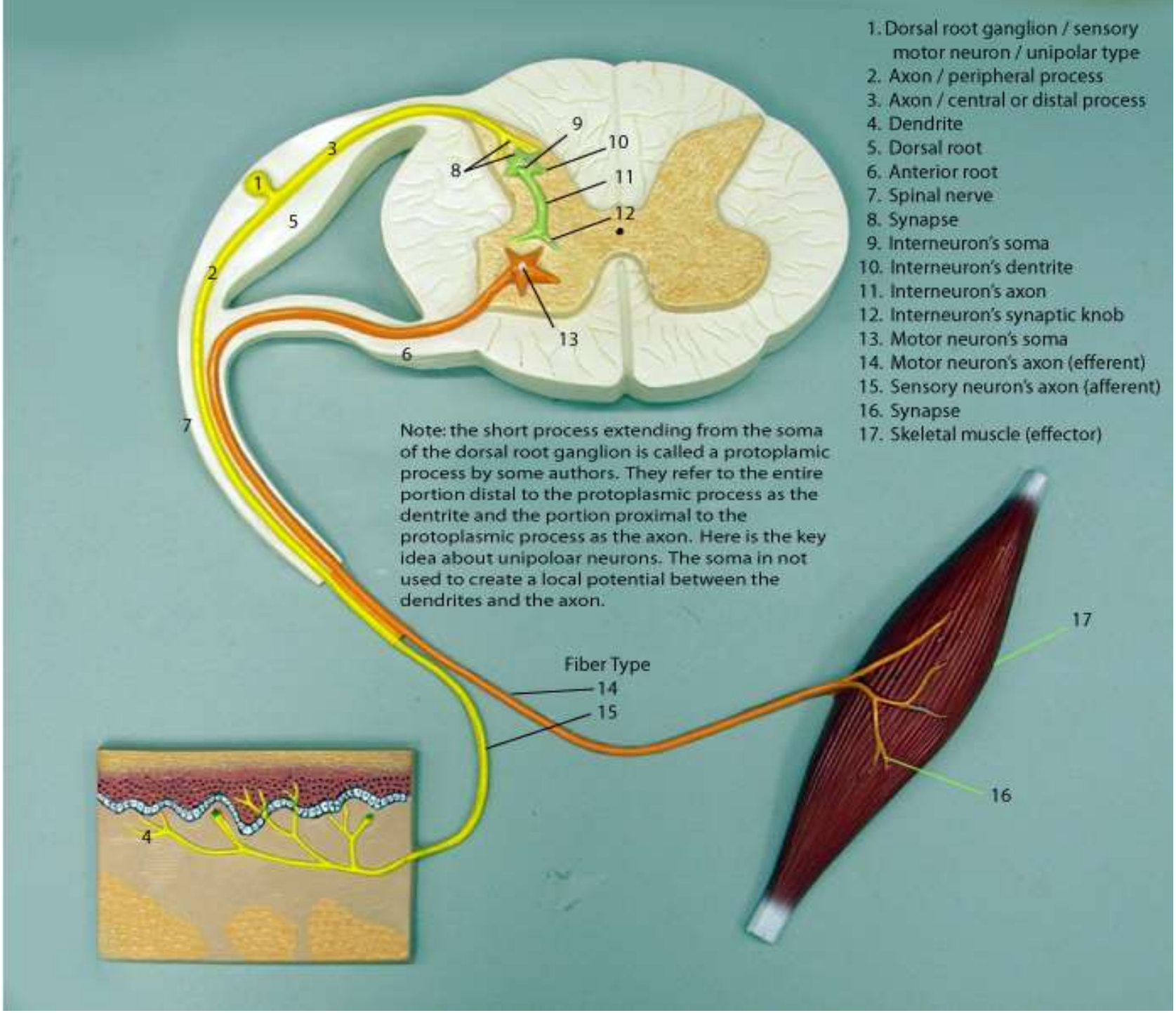
1. Dorsal root ganglion / sensory motor neuron / unipolar type
2. Axon / peripheral process
3. Axon / central or distal process
4. Dendrite
5. Dorsal root
6. Anterior root
7. Spinal nerve
8. Synapse
9. Interneuron's soma
10. Interneuron's dentrite
11. Interneuron's axon
12. Interneuron's synaptic knob
13. Motor neuron's soma
14. Motor neuron's axon (efferent)
15. Sensory neuron's axon (afferent)
16. Synapse
17. Skeletal muscle (effector)
Note: the short process extending from the soma of the dorsal root ganglion is called a protoplamic process by some authors. They refer to the entire portion distal to the protoplasmic process as the dentrite and the portion proximal to the protoplasmic process as the axon. Here is the key idea about unipoloar neurons. The soma in not used to create a local potential between the dendrites and the axon.
Fiber Type
14
15
16
17

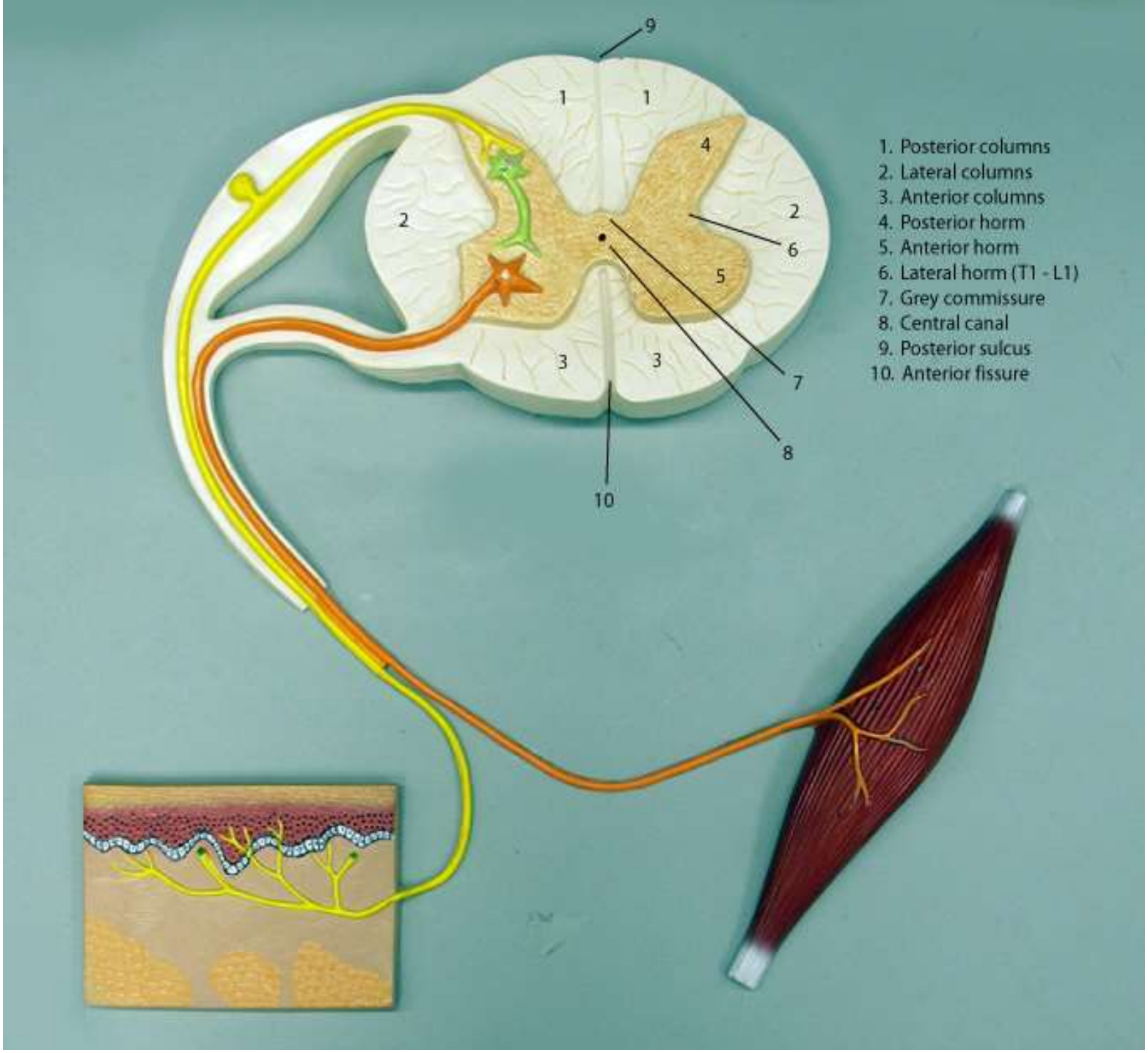
1. Posterior columns
2. Lateral columns
3. Anterior columns
4. Posterior horm
5. Anterior horm
6. Lateral horm (T1 - L1)
7. Grey commissure
8. Central canal
9. Posterior sulcus
10. Anterior fissure

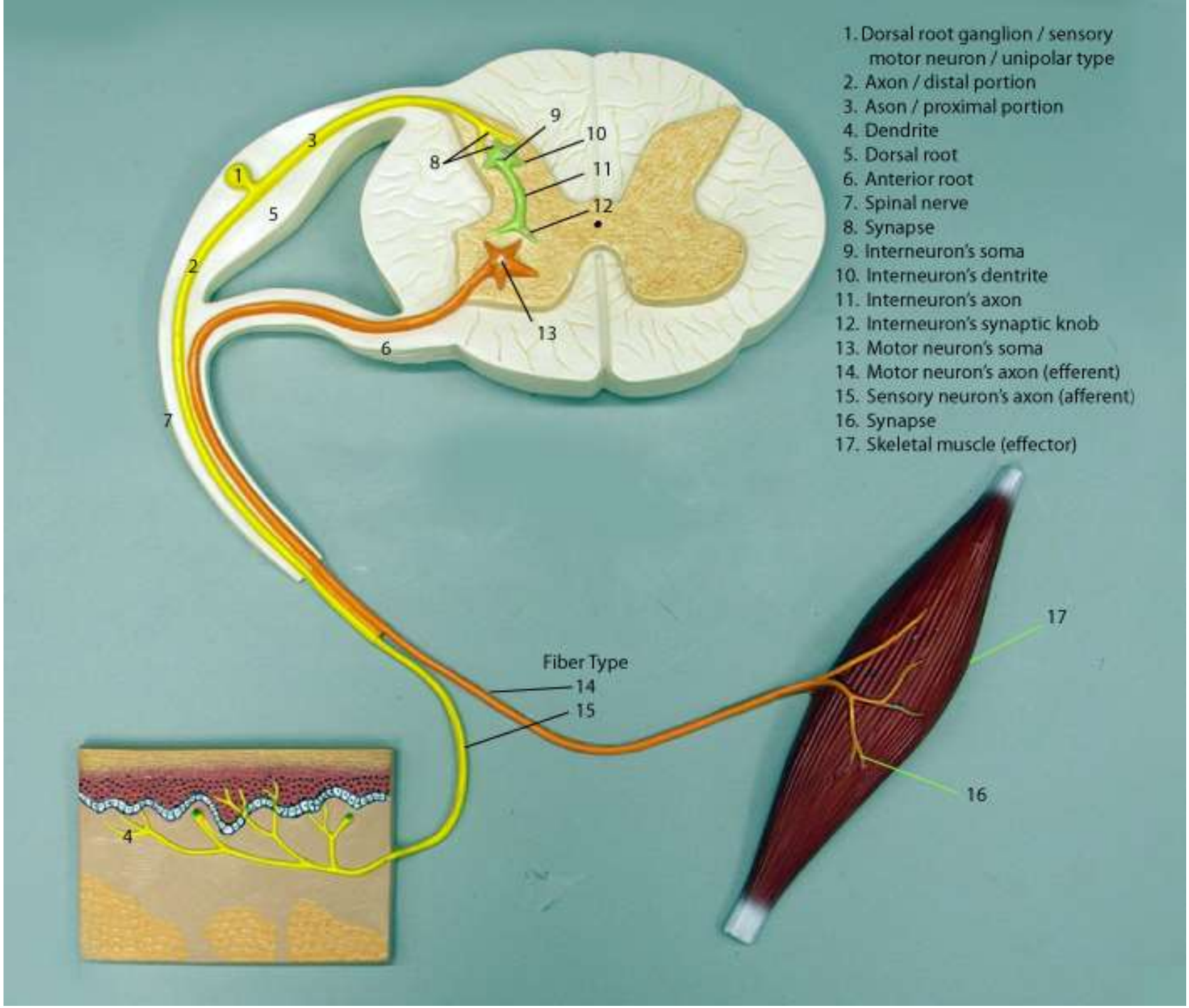
1. Dorsal root ganglion / sensory motor neuron / unipolar type
2. Axon / distal portion
3. Ason / proximal portion
4. Dendrite
5. Dorsal root
6. Anterior root
7. Spinal nerve
8. Synapse
9. Interneuron's soma
10. Interneuron's dentrite
11. Interneuron's axon
12. Interneuron's synaptic knob
13. Motor neuron's soma
14. Motor neuron's axon (efferent)
15. Sensory neuron's axon (afferent)
16. Synapse
17. Skeletal muscle (effector)
Fiber Type
14
15
16
17