Introduction to the Digestive System (C24)

Metabolism and Nutrition (C25)

(Learning Objectives - Part A)

Learning Objectives for Chapters 24 & 25

(Learning Objectives 1 – 9)

1. Discuss the functions of the digestive system
2. Define and compare mechanical and chemical digestion
3. List each of the components parts of the alimentary canal from mouth to anus. Identify accessory structures that open into the gastrointestinal tract.
4. Explain the division, sphincters, layers, and glands of the stomach.
5. Discuss the functions of the stomach and explain the process of emptying of the stomach.
6. Discuss the size and divisions of the small and large intestines.
7. Discuss the functions of the liver, gall bladder, and the pancreas.
8. State the composition and functions of bile.
9. Describe the problem caused by the obstruction of the opening of the pancreatic duct in the duodenum.
10. Outline the digestive sequence for carbohydrates, fats, and proteins. Include the enzymes, hormones, anatomical structures, and end products of macromolecules end products.
11. Describe the hormonal control of digestion, stating the source and functin of the following digestive hormones: gastrin, secretin, CCK, and gastric inhibitory peptide.
12. Describe the different types of gastrointestinal movements, such as peristalsis and segmentation, characteristic of the digestive system.
13. State the function of villi in the lining of the small intestine.
14. State the functions of the small intestine and colon.

A Brief Introduction to the Anatomy of the Digestive System

(Before Starting Learning Objectives)

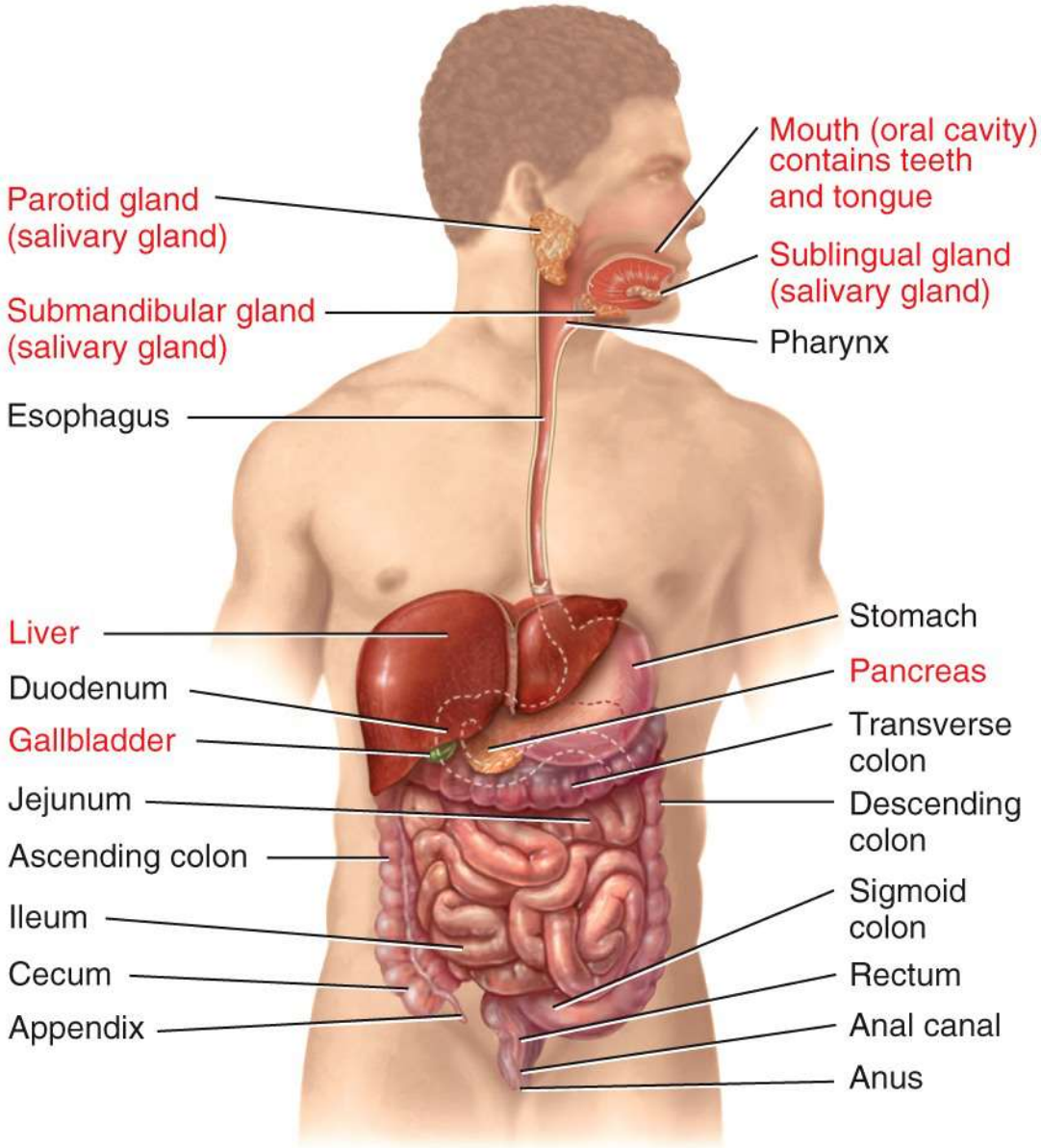

(a) Right lateral view of head and neck and anterior view of trunk

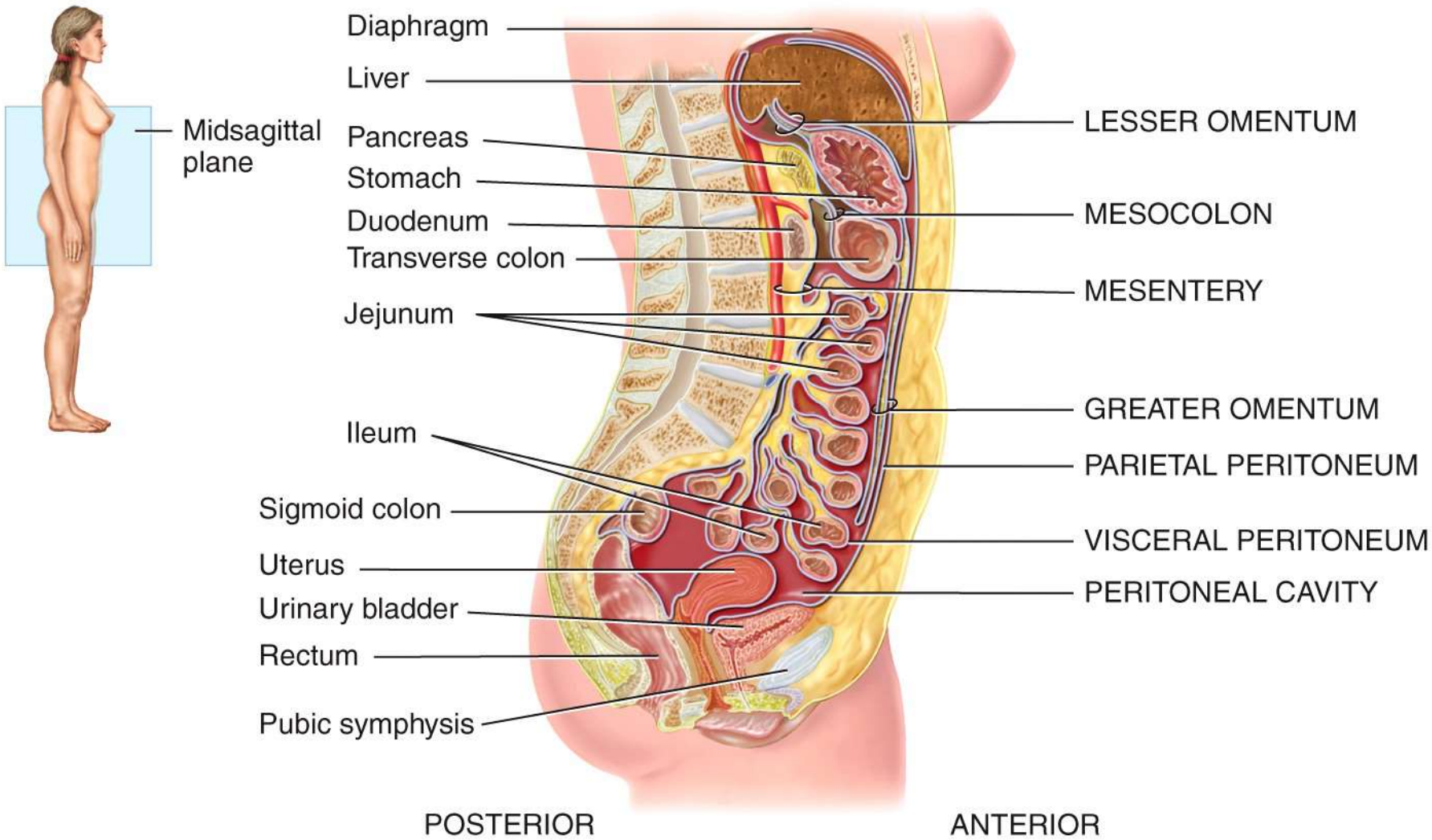

(a) Midsagittal section showing the peritoneal folds

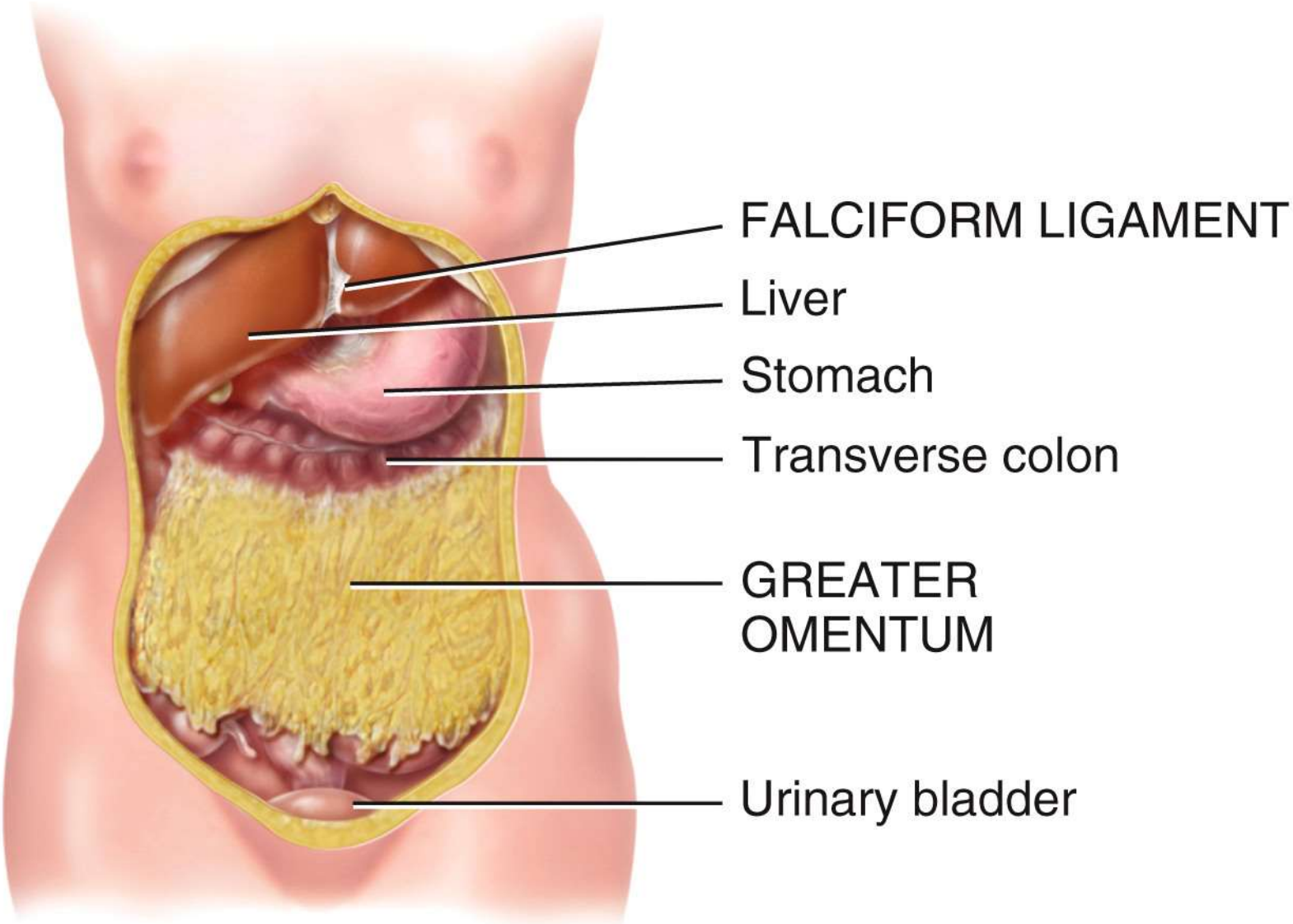

(b) Anterior view

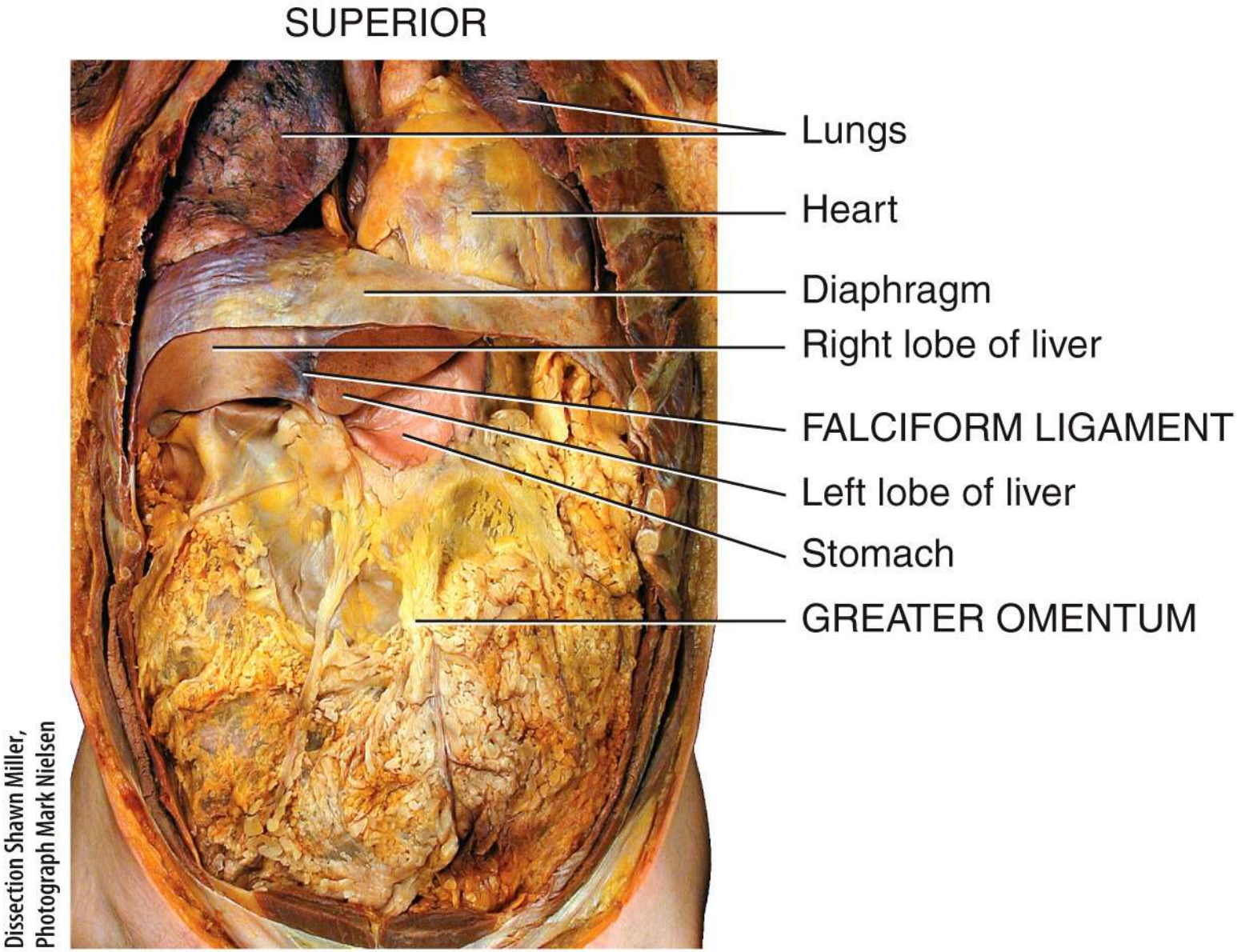

(e) Anterior view

The Classic Beer Belly!

This greater omentum contains approximately
10 gallons of adipose tissue!

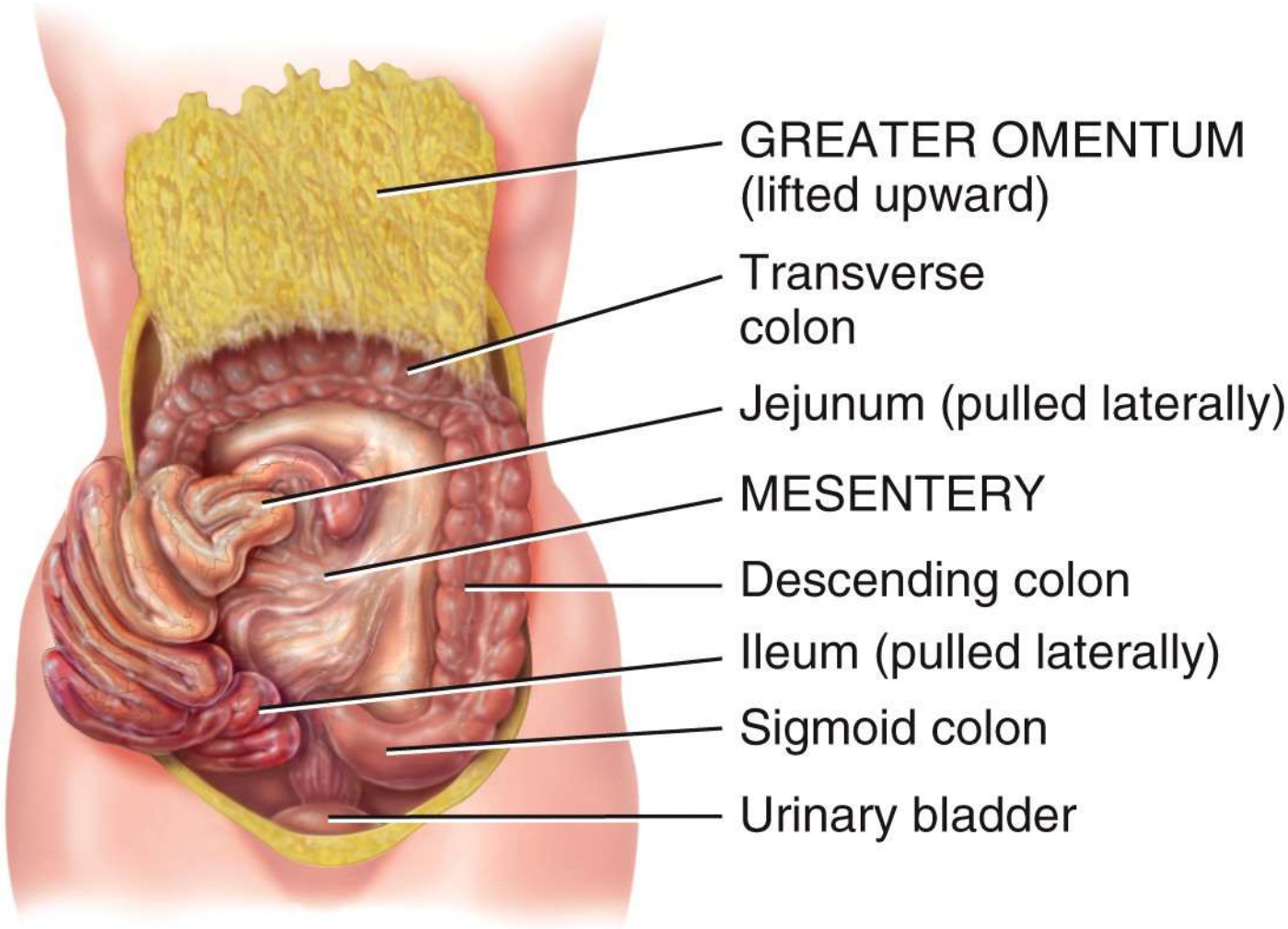

(d) Anterior view (greater omentum lifted and small intestine moved to right side)

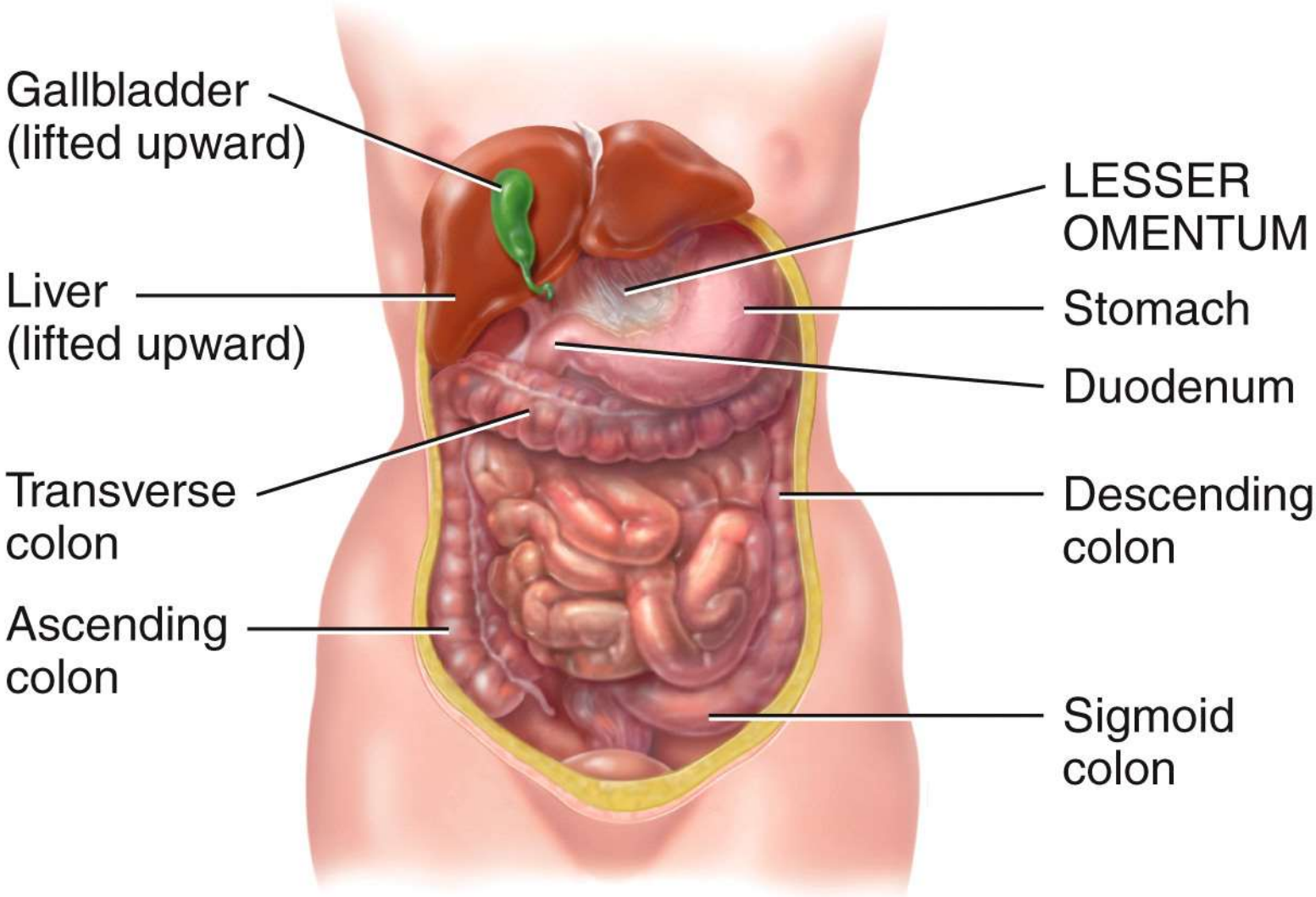

(c) Lesser omentum, anterior view
(liver and gallbladder lifted)

Learning Objective #1

Discuss the functions of the digestive system.

Digestive System Functions

- The organ system that processes food, extracts nutrients from it, and eliminates the residue

- **Five functions**
  - **ingestion** - selective intake of food
  - **digestion** – mechanical and chemical breakdown of food into a form usable by the body
  - **absorption** - uptake of nutrient molecules into the epithelial cells of the digestive tract and then into the blood and/or lymph (crossing mucosa)
  - **compaction** - absorbing water and consolidating the indigestible residue into feces
  - **regulation** - coordinate reflexes within and between the intestine and other organs (including brain)
  - **defecation** - elimination of feces

The Digestive System

- Most **nutrients** we eat cannot be used in their existing form
  - first food must be physically broken down into smaller "chucks", then.....
  - macromolecules (polymers) broken down into smaller molecules (monomer).
  - digestion does not break apart molecles into individual atoms
- The digestive system is essentially a **"disassembly line"**
  - break down nutrients into a form that can be used by the body
  - nutrients must be *absorb across the mucosa, then distributed to the cells and tissues of the body*

Learning Objective #2

Define and compare mechanical and chemical digestion

Two Types of Digestion

- Mechanical digestion
  - the physical breakdown of food into smaller particles
  - cutting and grinding action of the teeth
  - churning action of stomach and small intestines
  - exposes more food surface to the action of digestive enzymes

Two Types of Digestion

- Chemical digestion

  a series of hydrolysis reactions (ie break covalent bonds) to turn dietary macromolecules into their monomers

  carried out by **digestive enzymes** produced by salivary glands, stomach, pancreas and small intestine

  results:

  polysaccharides into **monosaccharides**

  proteins into **amino acids**

  fats into **monoglycerides and fatty acids**

  nucleic acids into nucleotides

Note: Some nutrients are present in a usable form in ingested food /// absorbed without being digested - vitamins, free amino acids, minerals, cholesterol, and water

Learning Objective #3

List, in sequence, each of the component parts of the alimentary canal from mouth to anus

Identify the accessory structures that are located within or open into the gastrointestinal tract.

General Anatomy of the Digestive System

- Digestive system has two anatomical divisions
- Digestive tract (alimentary canal)
  - 30 foot long muscular tube extending from mouth to anus
  - mouth, pharynx, esophagus, stomach, small intestine, and large intestine
  - gastrointestinal (GI) tract is the stomach and intestines
- Accessory organs
  - teeth, tongue, salivary glands, liver, gallbladder, and pancreas

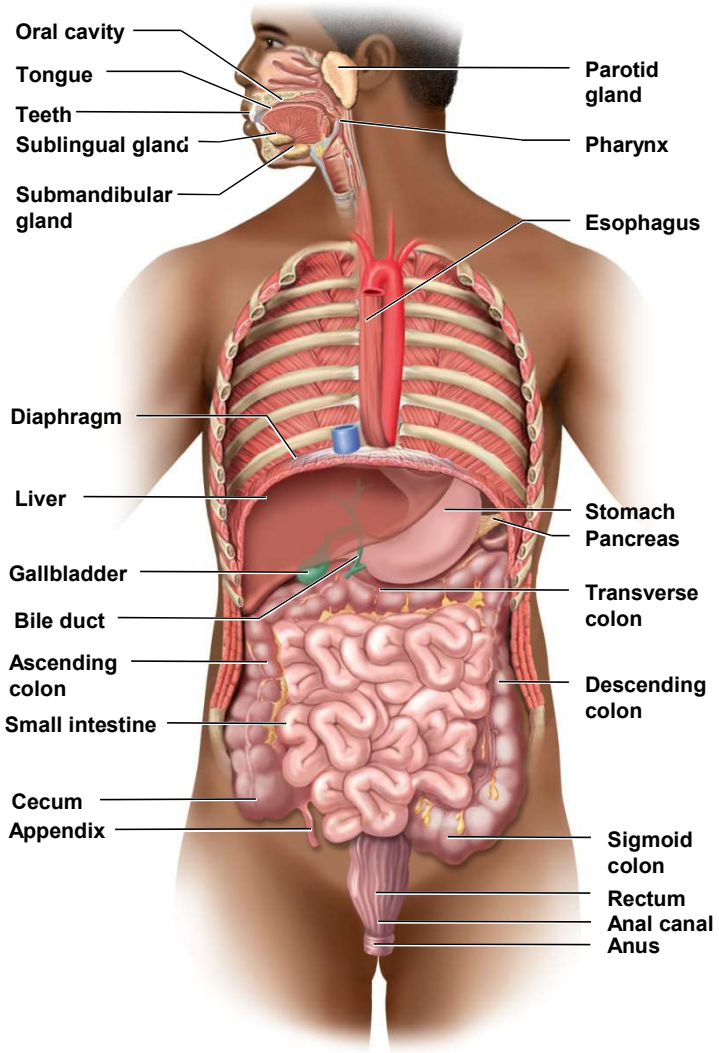

Mouth or Oral Cavity

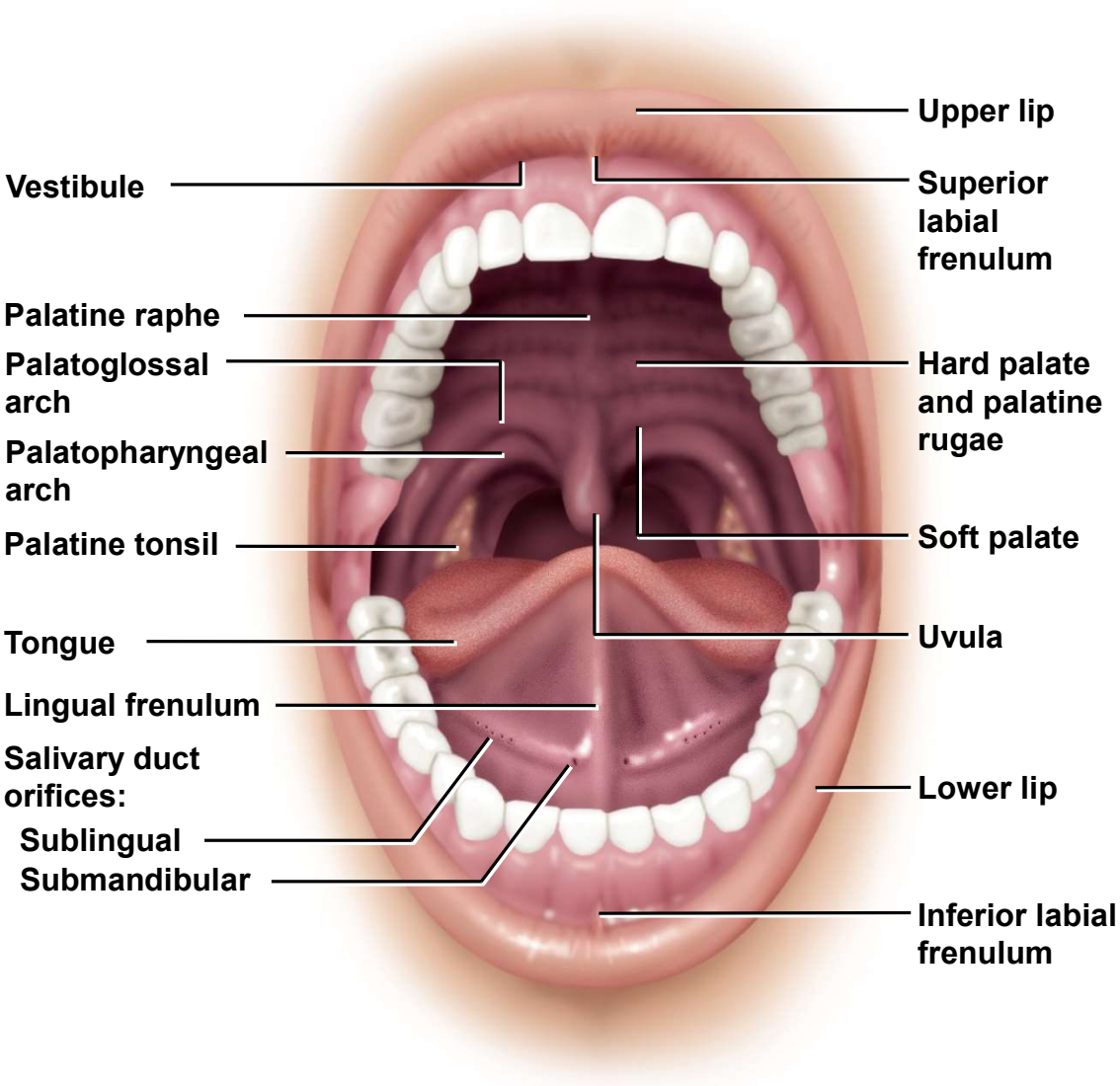

Tongue

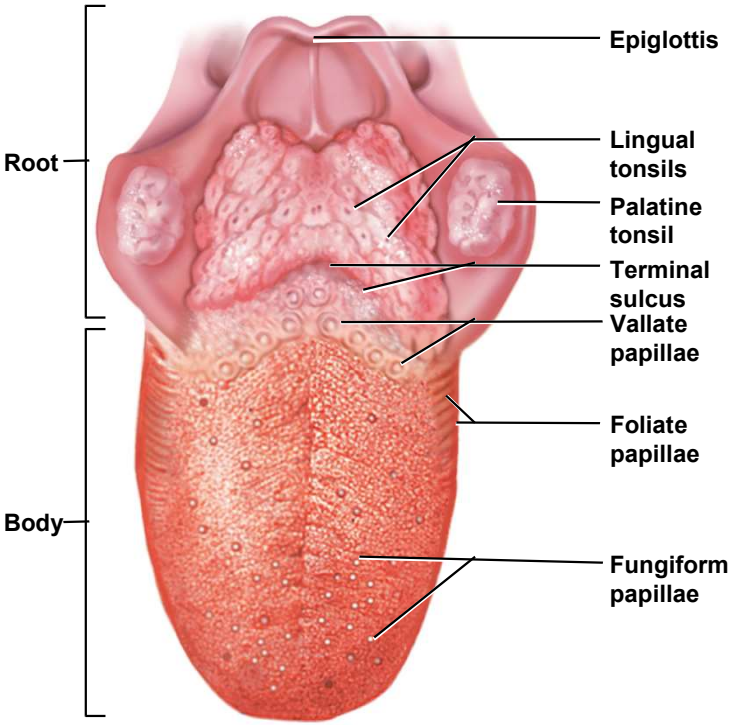

(a) Superior view

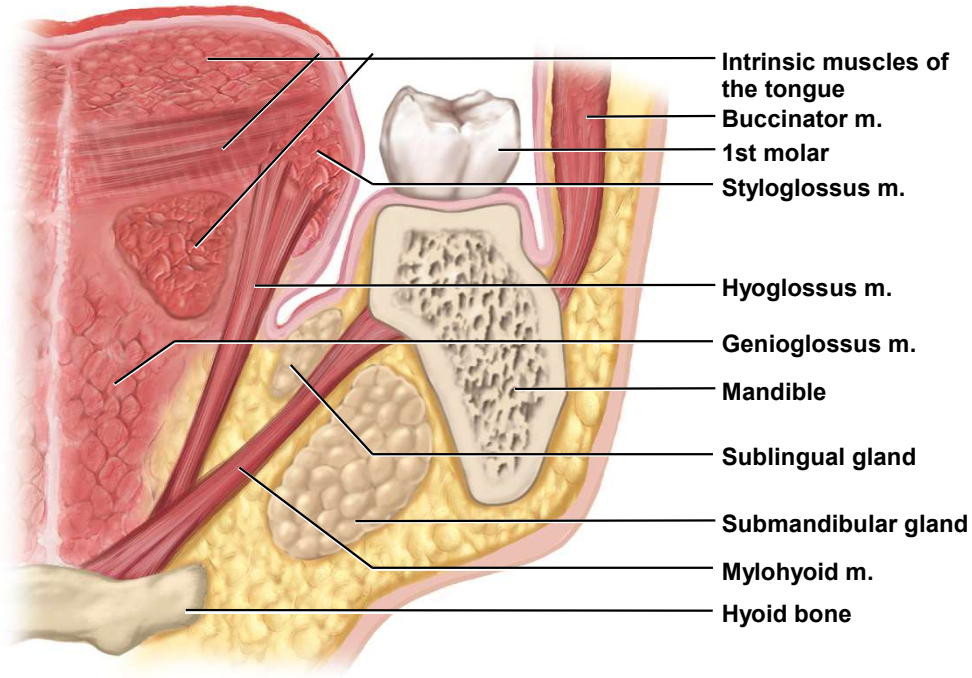

(b) Frontal section, anterior view

Salivary Glands

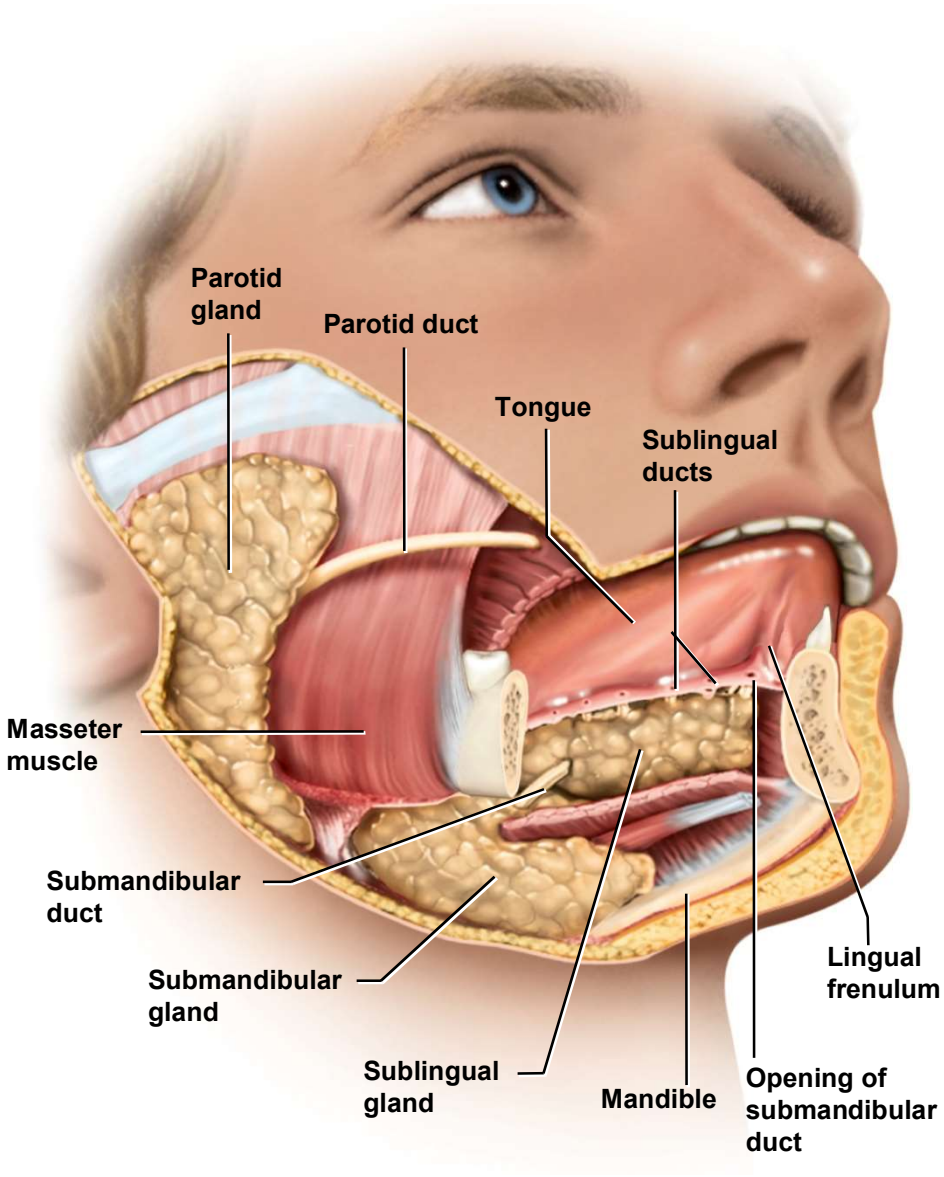

General Anatomy

- Digestive tract is a tubular structure
- Digestive tract is open to the environment at both ends
- Material in lumen of tube has not crossed a mucus membrane to enter the body tissues
  - nutrients in the GI lumen are outside of the body until they cross the mucosa of the absoptive cells and move into the body tissues
- Defecated food residue never crossed the mucosa

Sphincter Muscles of the GI Track

- Smooth muscle regulate passage of food (i.e. bolus / chyme / fecal matter) through the digestive system
  - Fascicles arranged in circular pattern around tubular structure = sphincter muscles /// constrict to close movement through tubular structure
  - Sphincter muscles are mostly smooth muscle however the “external anal sphincter” is a skeletal muscle
- List of sphincter muscles along alimentary canal
  - Upper esophageal sp. (physiologic)
  - Lower esophageal sp (cardiac)
  - Pyloric sp
  - Ileocecal valve (functional)
  - Internal anal sp
  - External anal sp (skeletal muscle)

Pharynx

- A muscular funnel that connects oral cavity to esophagus and allows entrance of air from nasal cavity to larynx
  - digestive and respiratory tracts intersect
- Pharyngeal constrictors (*superior, middle, and inferior*) - circular muscles that force food downward during swallowing
  - when not swallowing, the inferior constrictor remains contracted to exclude air from the esophagus
  - this constriction is considered to be the upper esophageal sphincter although it is not an anatomical feature
  - disappears at the time of death when the muscles relax, so it is a physiological sphincter, not an anatomical structure

Esophagus (1 of 2)

- A straight muscular tube 25-30 cm long
  - begins at level between C6 and the cricoid cartilage
  - extends from **pharynx** to **cardiac orifice** of stomach passing through **esophageal hiatus** in diaphragm
  - **lower esophageal sphincter** – food pauses at this point because of this constriction
    - prevents stomach contents from regurgitating into the esophagus
    - protects esophageal mucosa from erosive effect of the stomach acid
    - **heartburn** – burning sensation produced by acid reflux into the esophagus

Esophagus (2 of 2)

- **nonkeratinized stratified squamous epithelium**
- **esophageal glands** in submucosa secrete mucus
- deeply folded into longitudinal ridges when empty
- skeletal muscle in upper one-third, mixture in middle one-third, and only smooth muscle in the bottom one-third
- meets stomach at level of T7
- covered with **adventitia**

X-ray: Swallowing in Esophagus

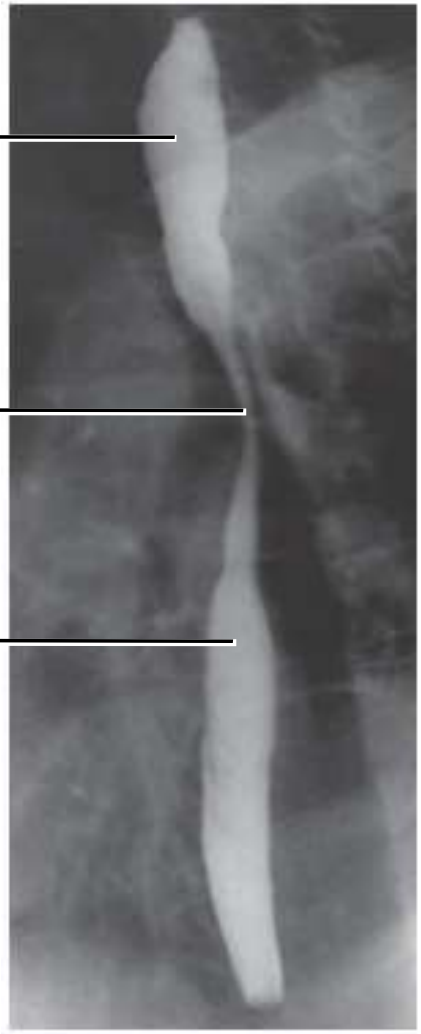

Gross Anatomy of Stomach

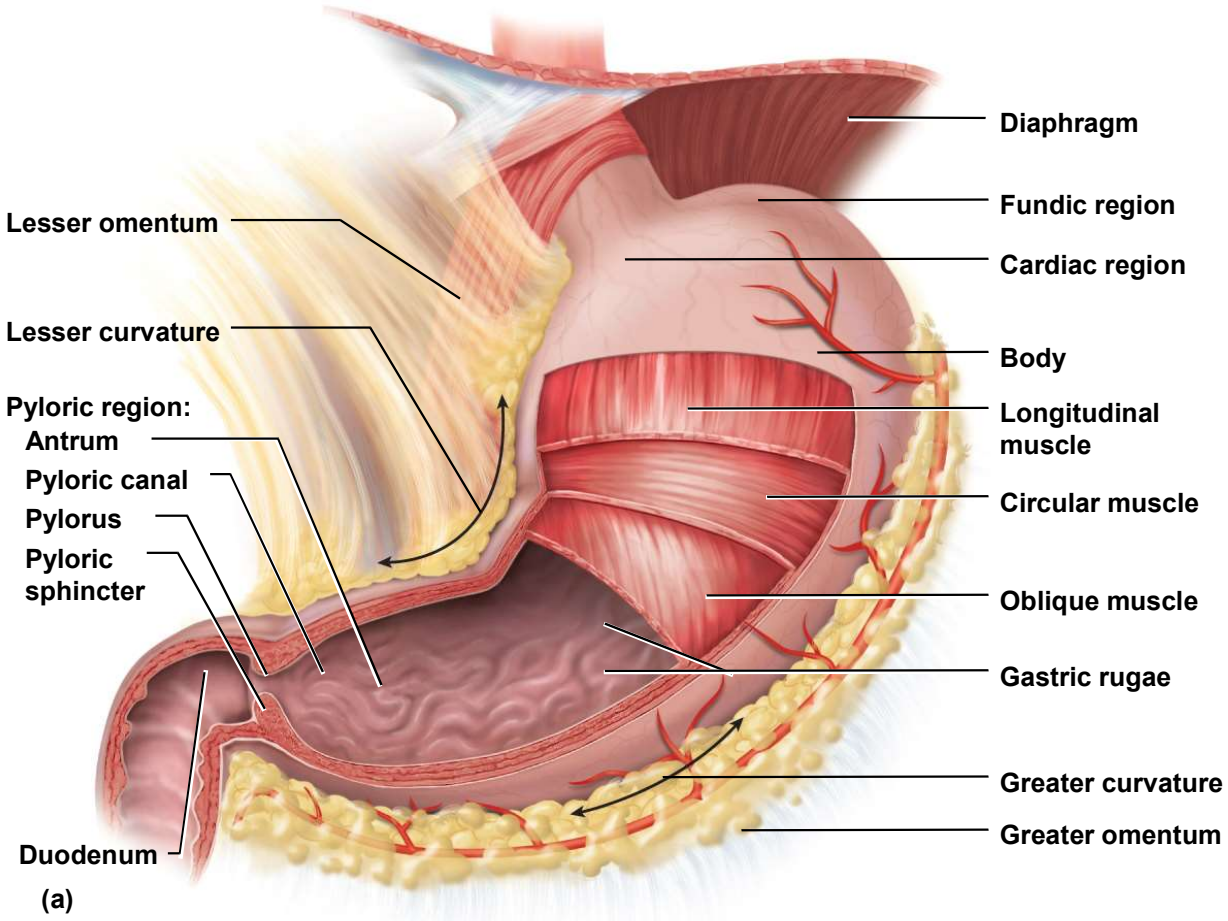

- Note: bulge of fundus, narrowing of pyloric region, thickness of pyloric sphincter, and greater and lesser curvatures

Small Intestine

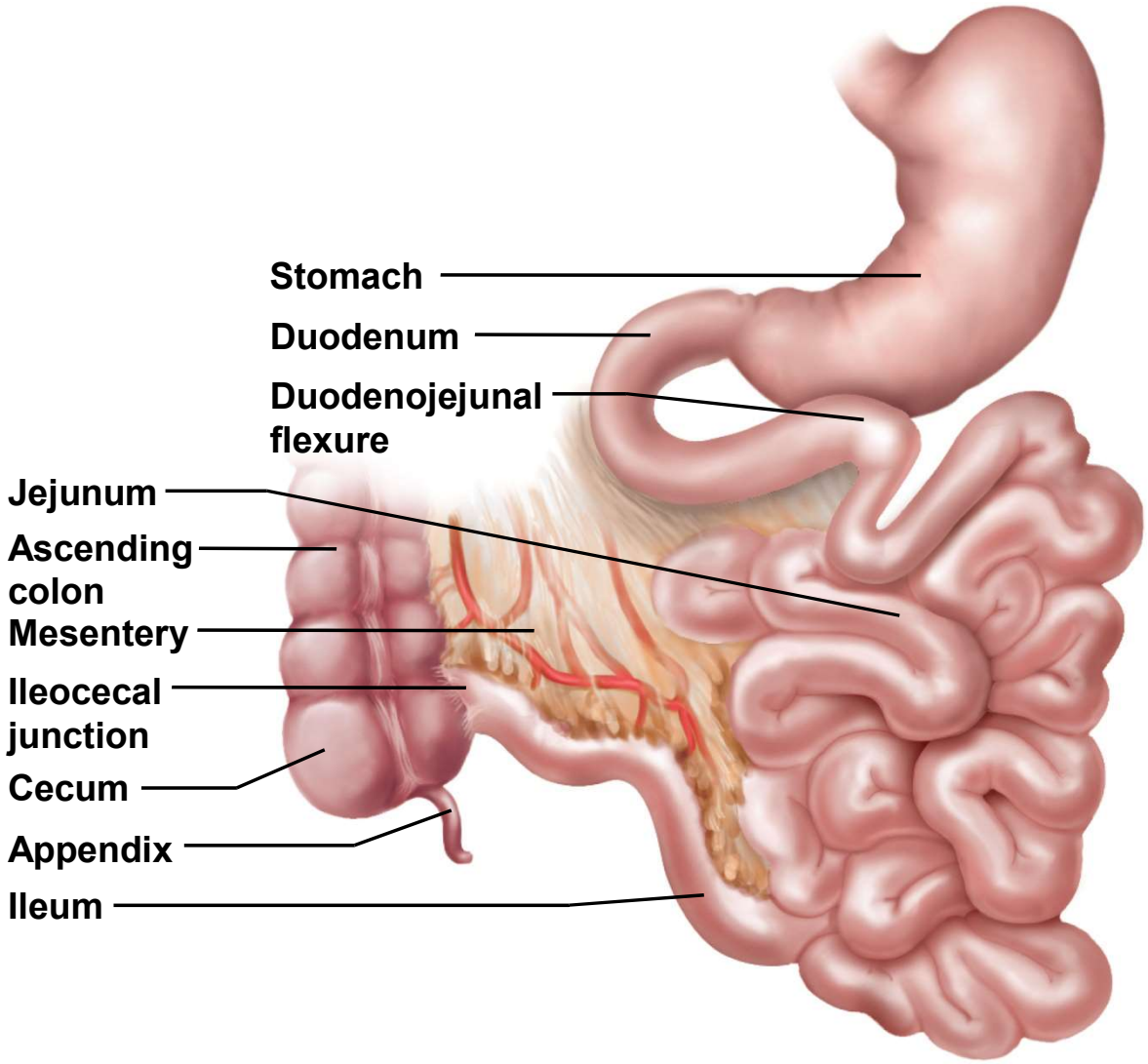



(a)

(b)

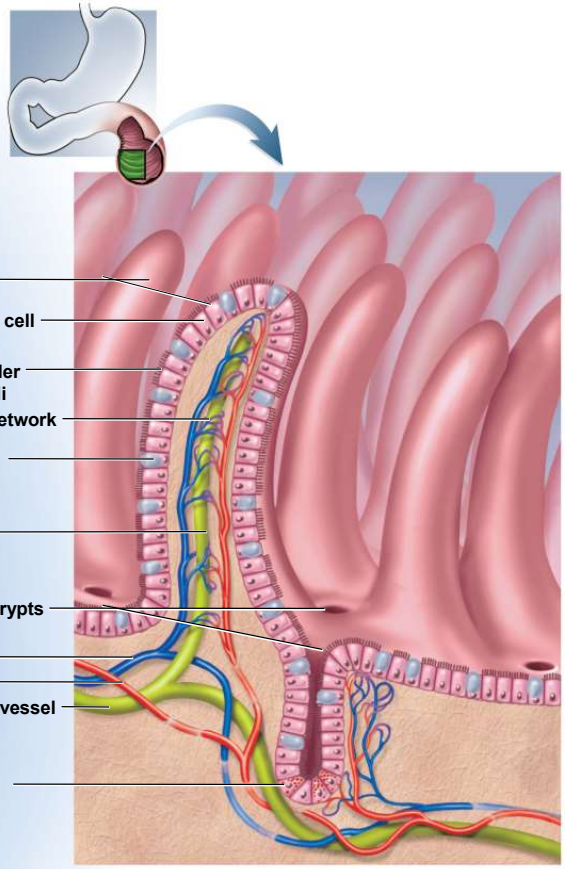

(c)

Intestinal Villi

Microscopic Anatomy

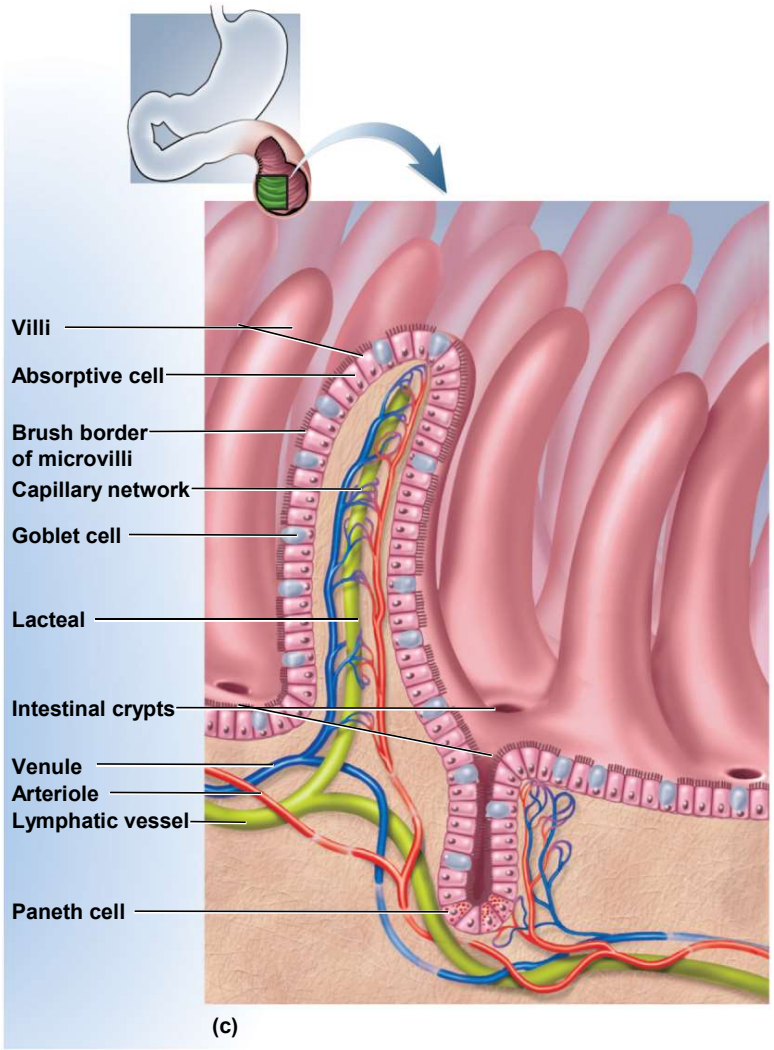

microvilli – fuzzy border of microvilli on apical surface of each absorptive cell

- about 1 μm high
- blood capillaries of villus absorb most of the nutrients
- lacteal absorbs most lipids
- the **brush border** increases absorptive surface area
- **brush border enzymes** – contained in the plasma membrane of microvilli
  - **carry out some of the final stages of enzymatic digestion**
  - not released into the lumen
  - **contact digestion** – the chyme must contact the brush border for digestion to occur
  - intestinal churning of chyme insures contact with the mucosa

Anatomy of Large Intestine

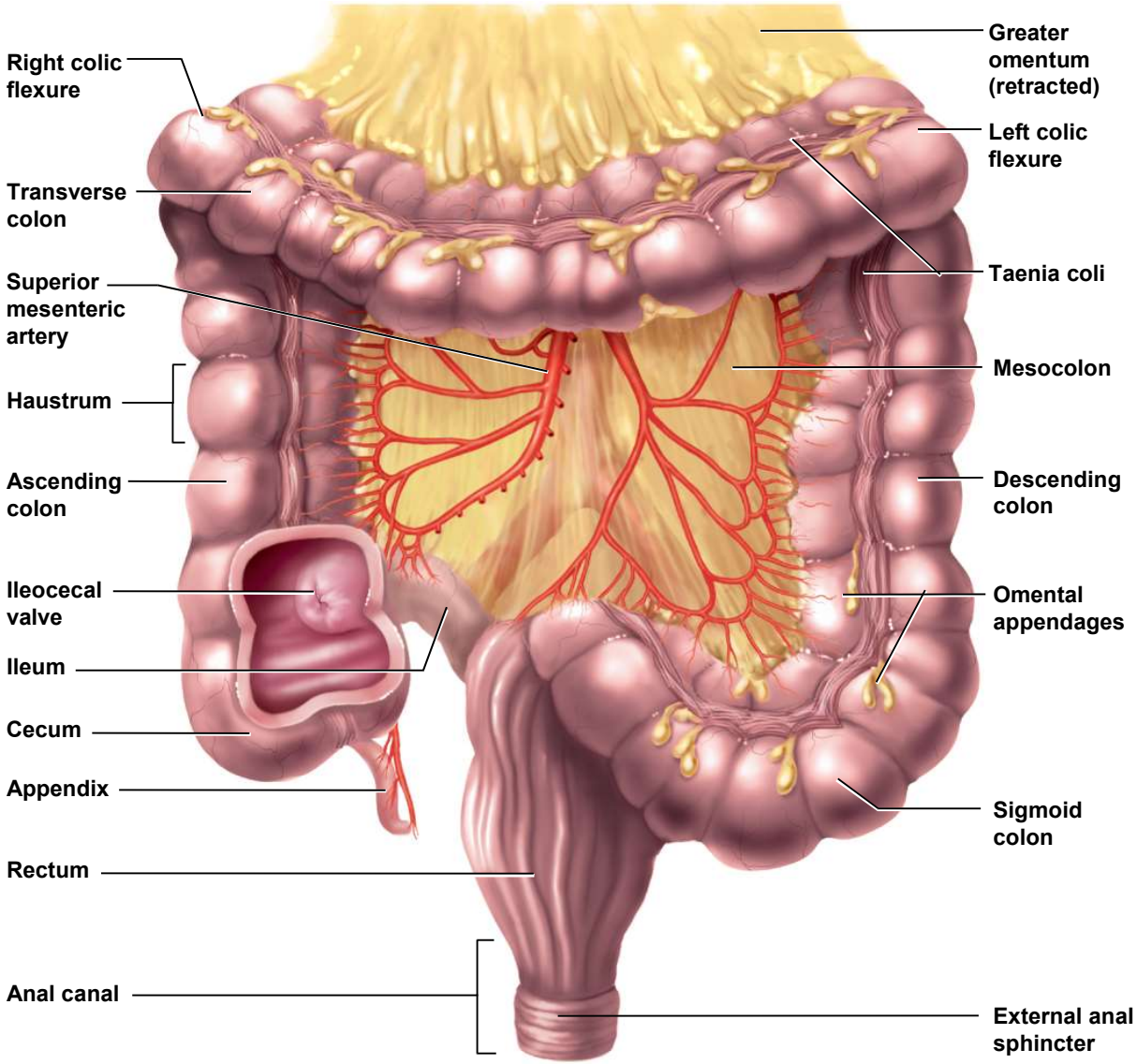

Anatomy of Anal Canal

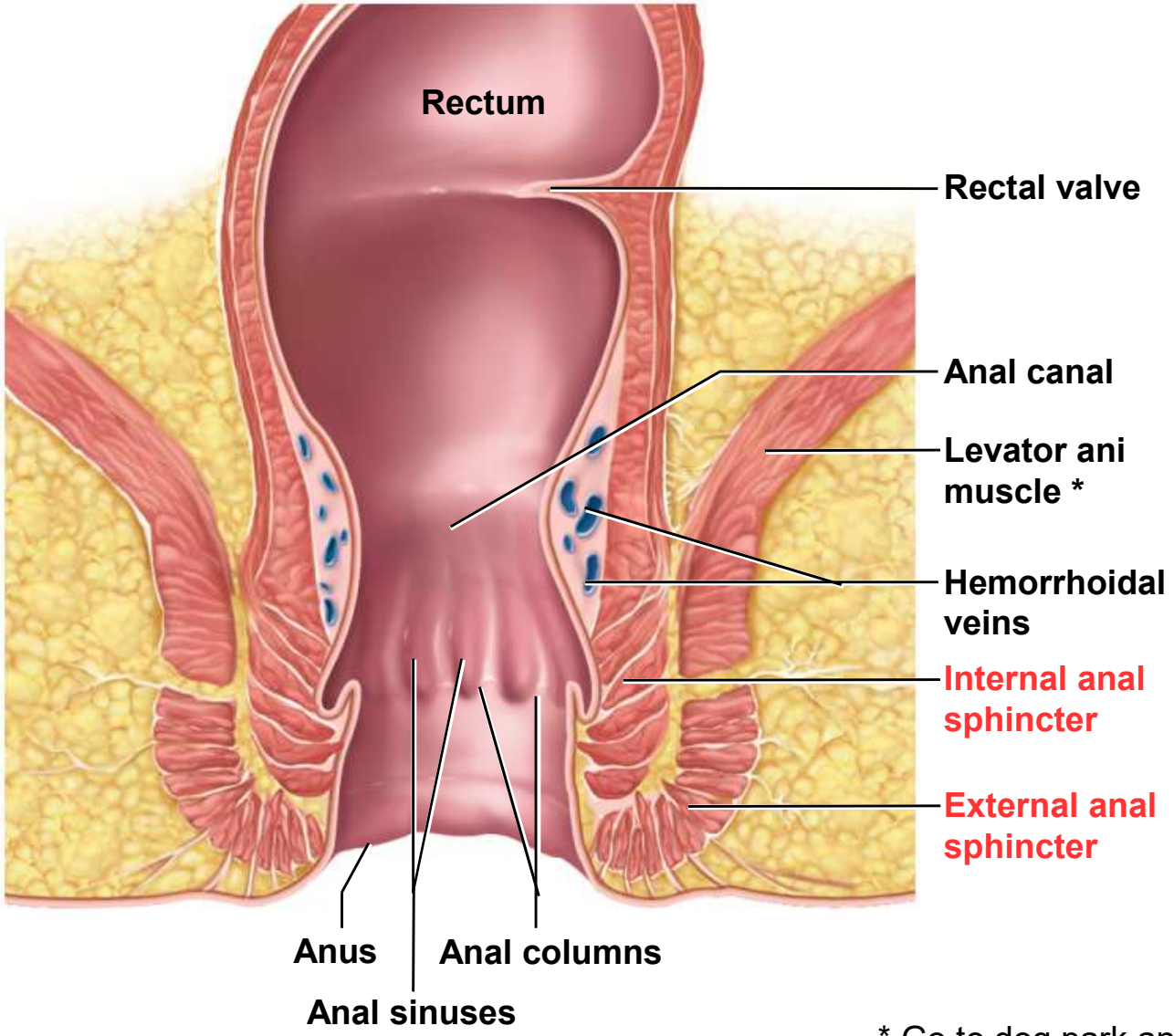

* Go to dog park and watch a dog deficate to see this muscle's function!

Gross Anatomy of Liver

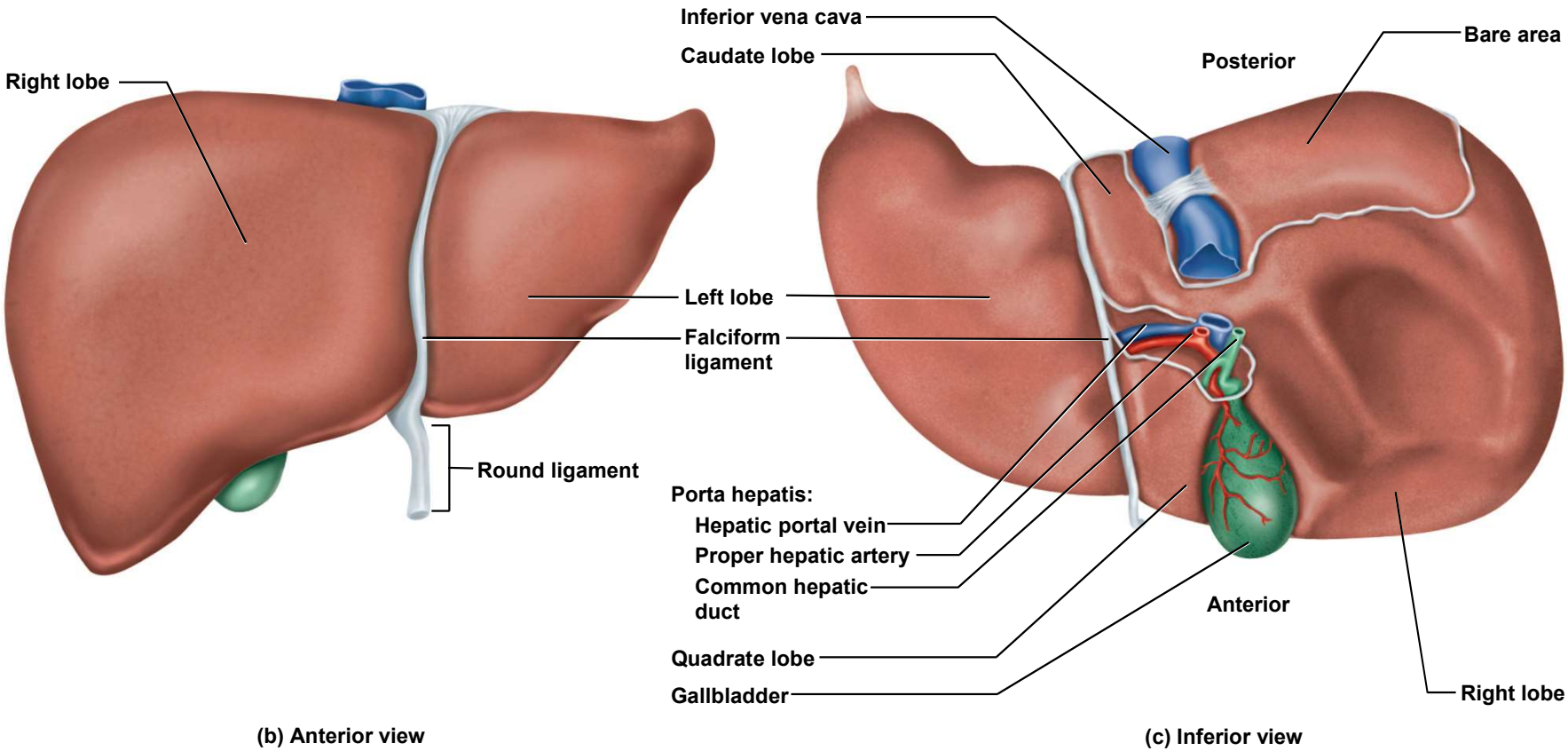

(b) Anterior view

(c) Inferior view

Gross Anatomy of the Gallbladder, Pancreas, and Bile Passages

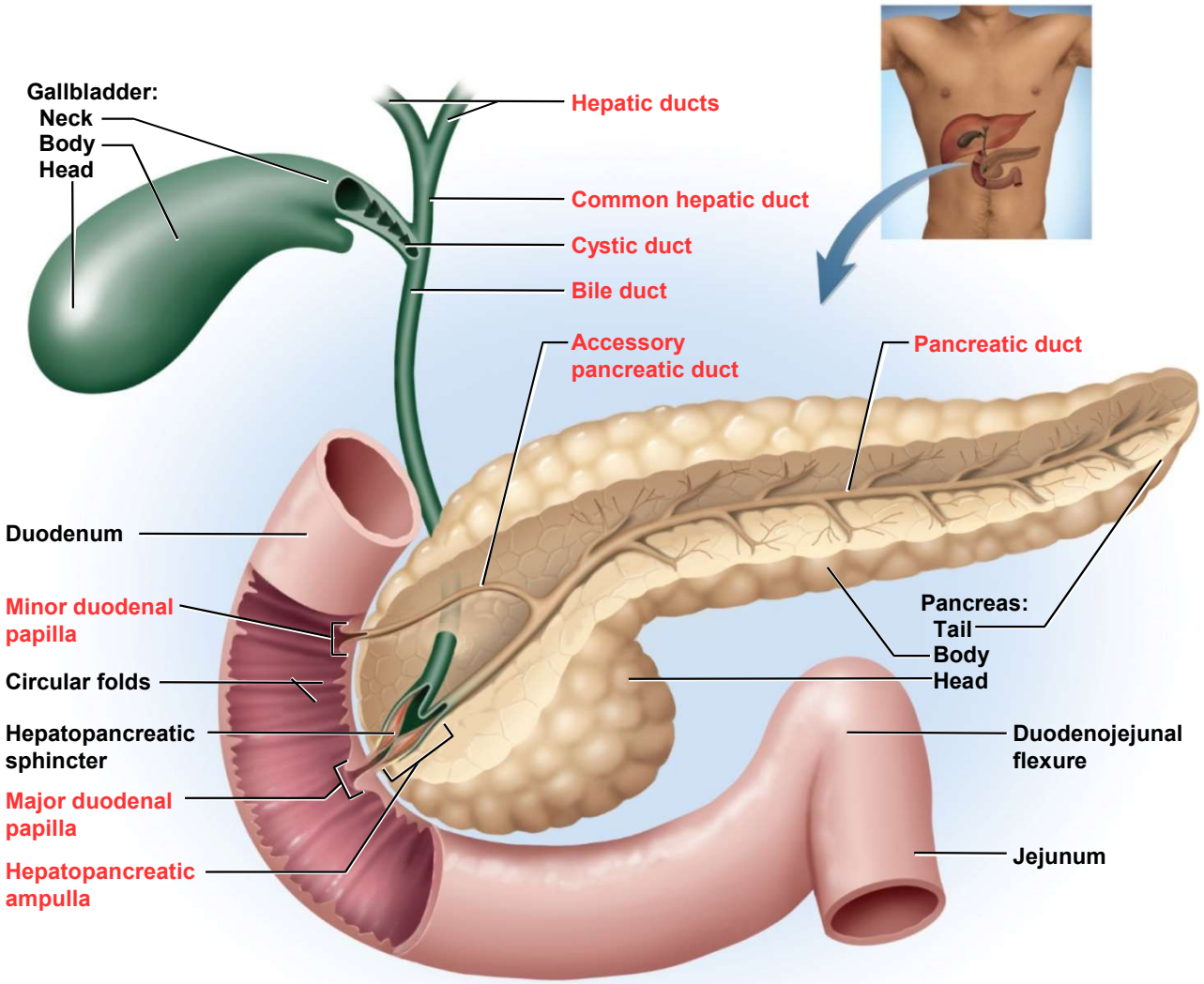

Summary of the structure and function of the accessory digestive organs.

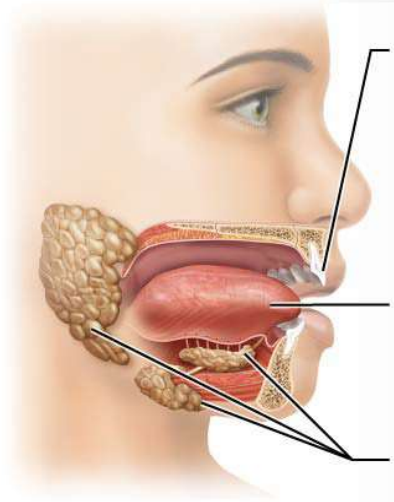

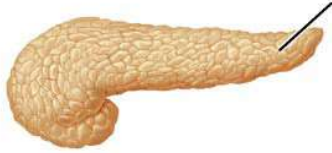

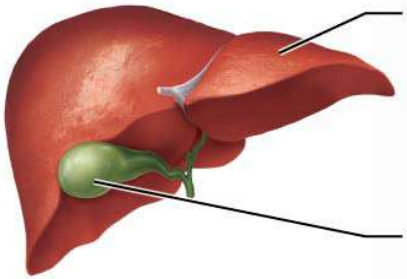

ORGAN	STRUCTURAL PROPERTIES	FUNCTIONAL ROLES
Teeth	• Two sets: primary and secondary dentition • Consist of a crown above the gum and a root embedded in bone • Composed of inner pulp cavity surrounded by dentin, which in turn is surrounded by enamel or cementum	• Mechanical digestion (mastication)
Tongue	• Consists of skeletal muscle with overlaying stratified squamous epithelium • Surface contains papillae	• Mechanical digestion • Propulsion (swallowing) • Sense of taste
Salivary glands	• Three sets: parotid glands, submandibular glands, and sublingual glands • Consist of mucous cells and serous cells	• Secrete saliva, which assists in chemical digestion, deters the growth of harmful microorganisms, and moistens food to assist in swallowing and mechanical digestion • Chemical digestion of carbohydrates
Pancreas	• Consists of pancreatic acini, composed of acinar cells surrounding a duct	• Secretes enzymes that catalyze chemical digestion of lipids, carbohydrates, proteins, and nucleic acids • Secretes bicarbonate ions to neutralize acidic chyme
Liver	• Consists of hexagonal liver lobules surrounding a central vein • Liver lobules contain plates of hepatocytes	• Mechanical digestion (via bile production) • Excretion (excretes wastes in bile)
Gallbladder	• Muscular sac on the posteroinferior liver	• Mechanical digestion (stores, concentrates, and releases bile)

Swallowing (Deglutition)

(This Topic Is Not a Learning Objective)

- a complex action involving over 22 muscles in the mouth, pharynx, and esophagus

- **swallowing center** – pair of nuclei in medulla oblongata that coordinates swallowing

    - communicates with muscles of the pharynx and esophagus by way of trigeminal, facial, glossopharyngeal, and hypoglossal nerves.

- **swallowing occurs in two phases // first phase = buccal phase**

    - under **voluntary control**
    - tongue collects food, presses it against the palate forming a bolus, and pushes it posteriorly
    - food accumulates in oropharynx in front of the 'blade' of the epiglottis
    - epiglottis tips posteriorly and food bolus slides around it through the laryngeal opening
    - bolus enters laryngopharynx and stimulates tactile receptors and activates next phase

Swallowing (Deglutition)

- **pharyngoesophageal phase**
  - is **involuntary**
  - <u>three actions prevent food and drink from re-entering the mouth or entering the nasal cavity or larynx</u>
    - the root of the tongue blocks the oral cavity
    - the soft palate rises and blocks the nasopharynx
    - the infrahyoid muscles pull the larynx up to meet the epiglottis while laryngeal folds close the airway
  - food bolus is driven downward by constriction of the upper, then middle, and finally the lower pharyngeal constrictors
  - bolus enters esophagus, stretches it, and stimulates peristalsis

Swallowing (Deglutition)

- **pharyngoesophageal phase**
  - **peristalsis** – wave of muscular contraction that pushes the bolus ahead of it // an entirely involuntary reflex
  - when standing or sitting upright, the food and liquid drops through the esophagus by **gravity** faster than peristalsis can keep up with it
  - peristalsis ensures you can swallow regardless of body position
  - liquid reaches the stomach in 1 to 2 seconds
  - food bolus in 4 to 8 seconds
  - when it reach lower end of the esophagus, the lower esophageal sphincter relaxes to let food pass into the stomach

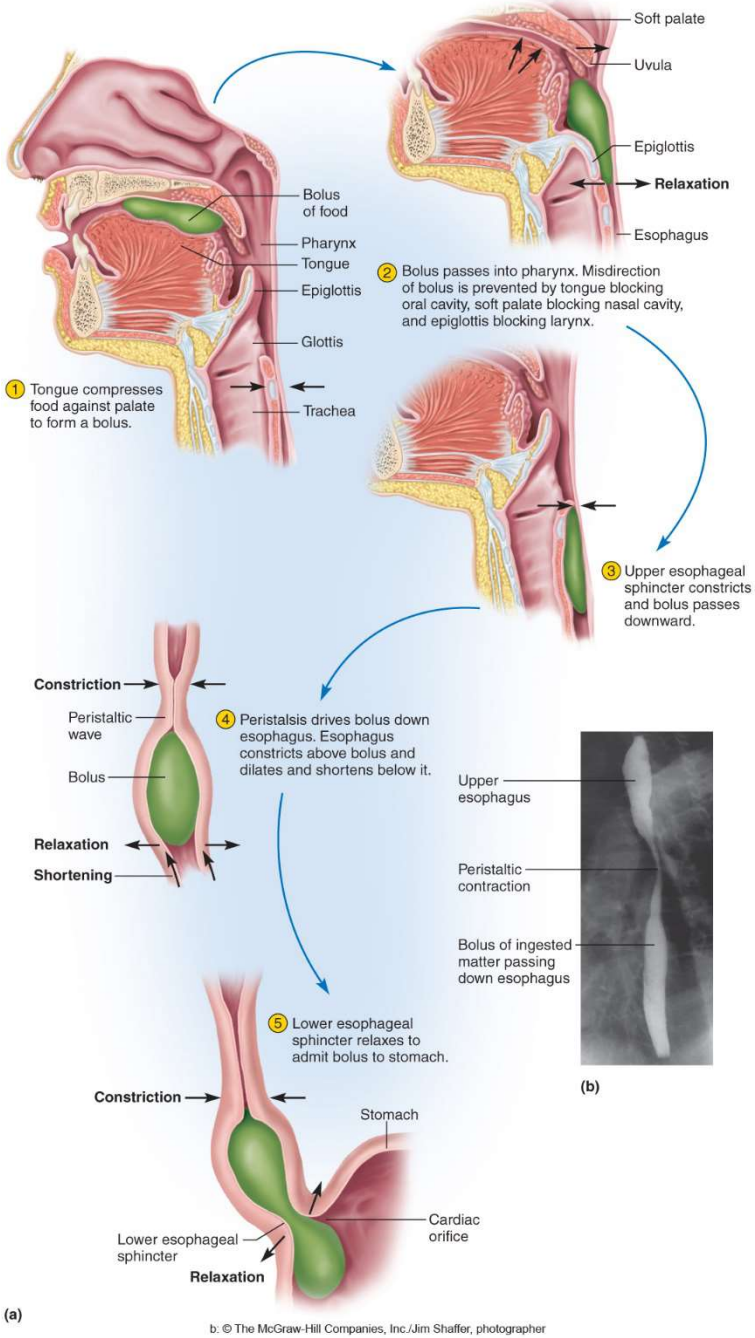

Swallowing occurs in "two phases"

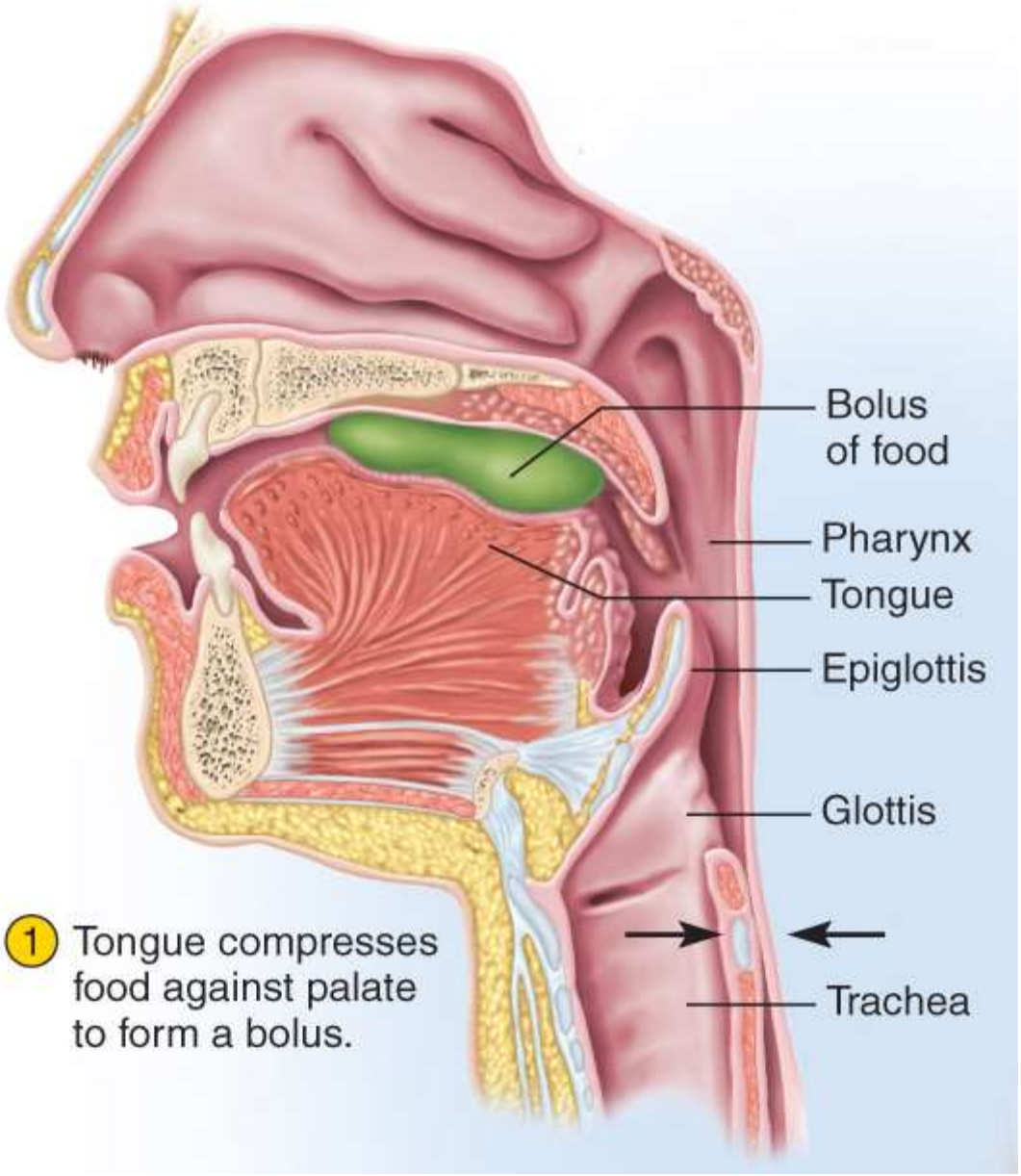
Bolus of food
Pharynx
Tongue
Epiglottis
Glottis
Trachea
1 Tongue compresses food against palate to form a bolus.

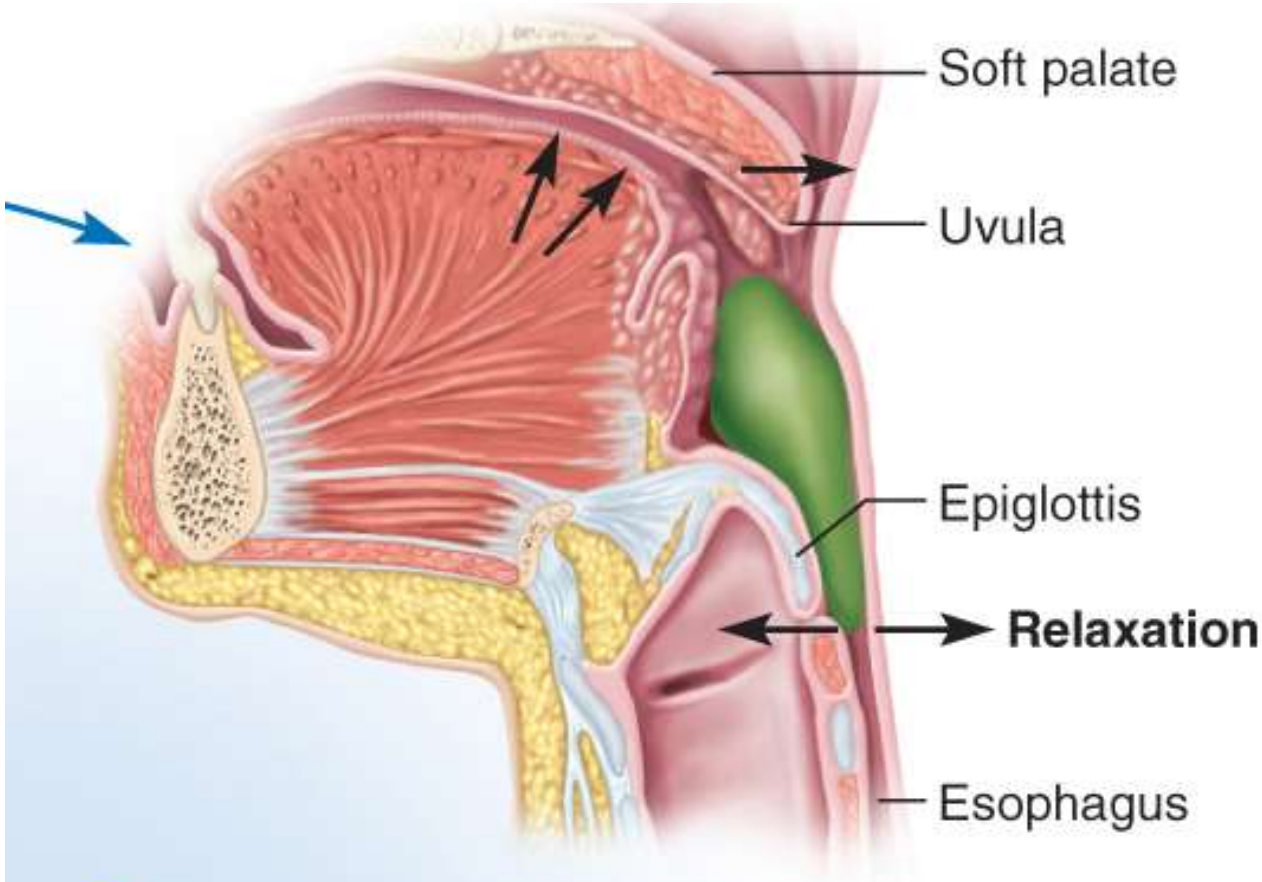

2 Bolus passes into pharynx. Misdirection of bolus is prevented by tongue blocking oral cavity, soft palate blocking nasal cavity, and epiglottis blocking larynx.

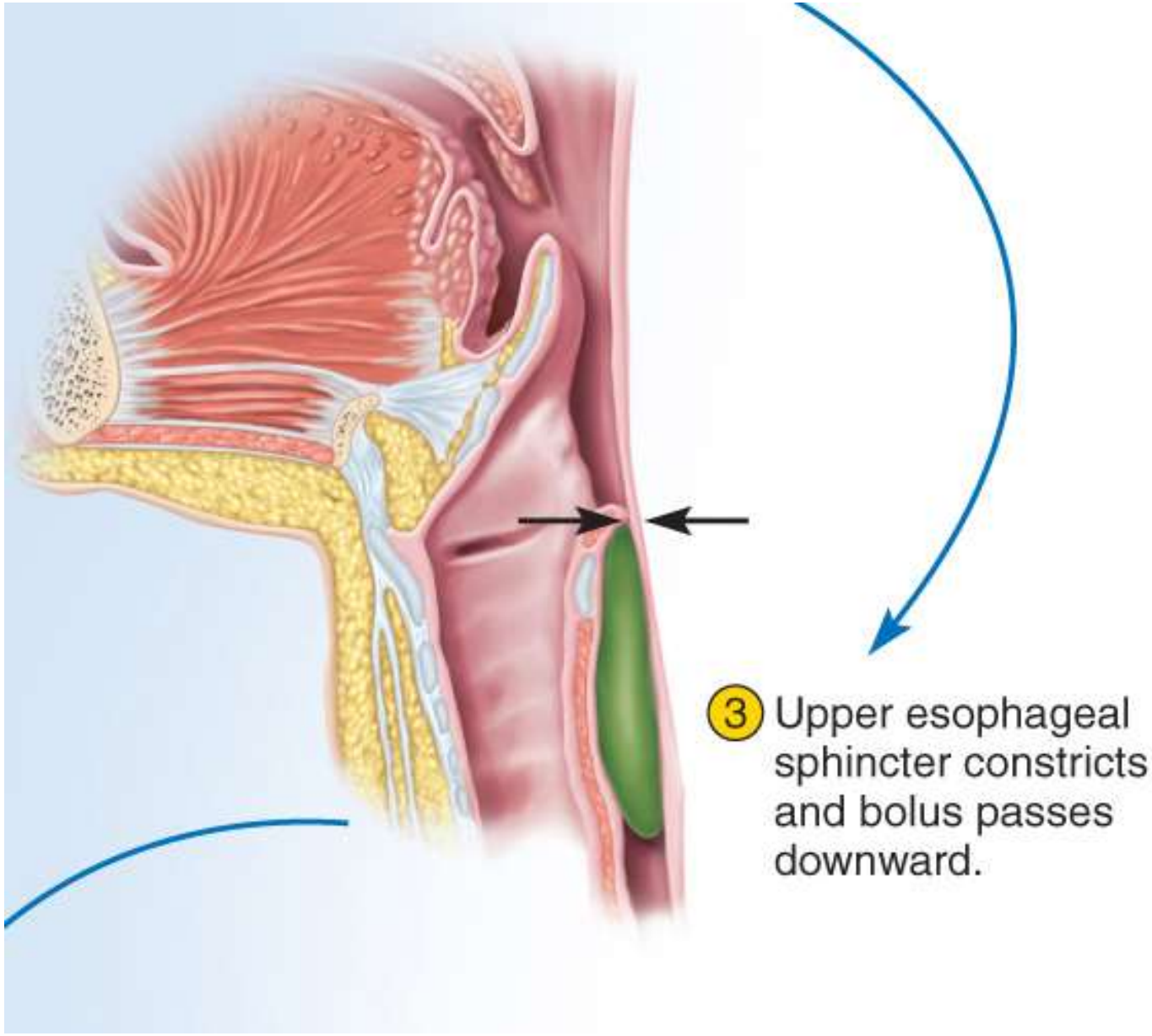
3 Upper esophageal sphincter constricts and bolus passes downward.

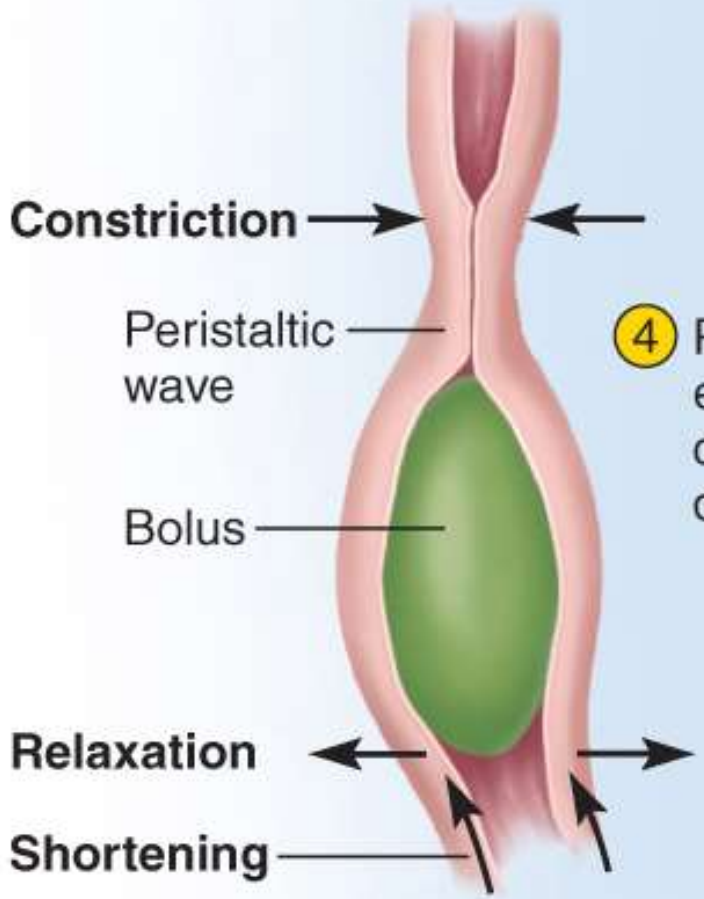

4 Peristalsis drives bolus down esophagus. Esophagus constricts above bolus and dilates and shortens below it.

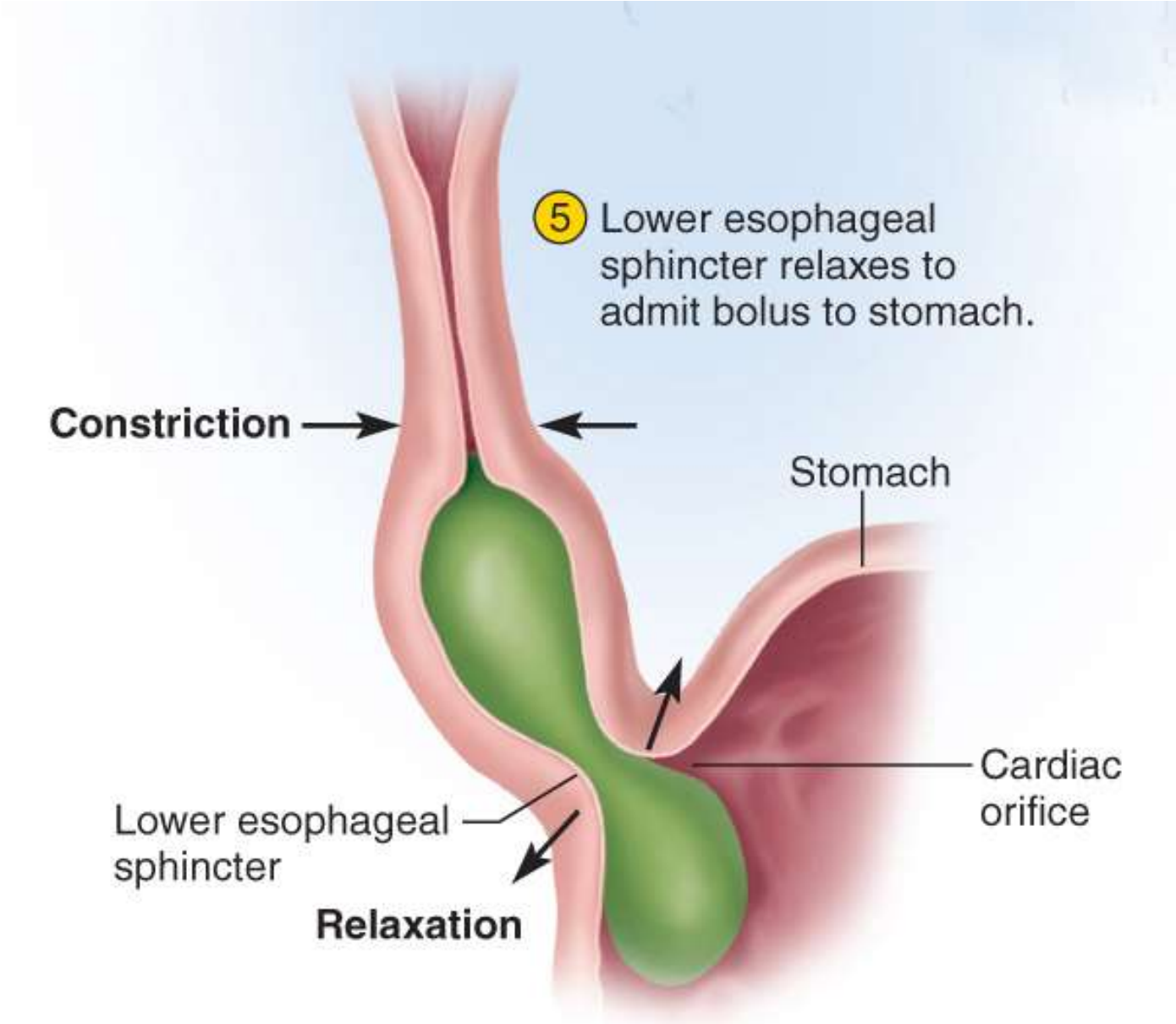
5 Lower esophageal sphincter relaxes to admit bolus to stomach.
Constriction
Stomach
Cardiac orifice
Lower esophageal sphincter
Relaxation

X-ray: Swallowing in Esophagus

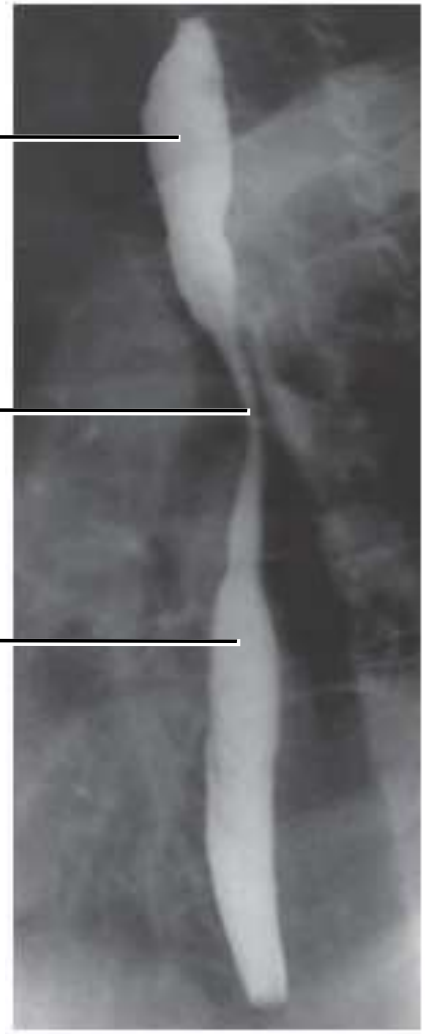

Learning Objective #4

Explain the stomach's structures, divisions, sphincters, smooth muscle layers, and glands

Gross Anatomy of Stomach

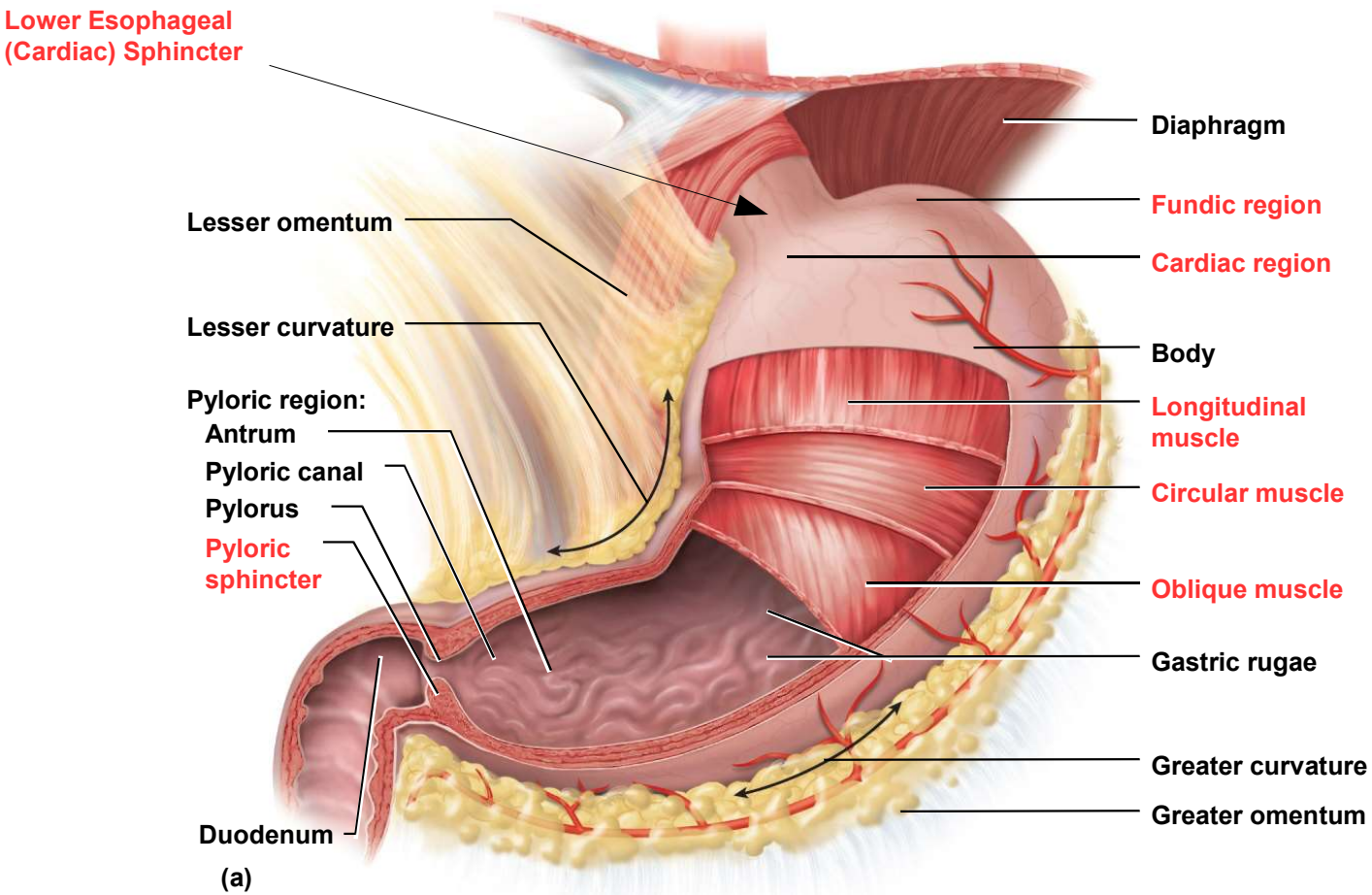

- Note: bulge of fundus, narrowing of pyloric region, thickness of pyloric sphincter, and greater and lesser curvatures

Gross Anatomy of Stomach

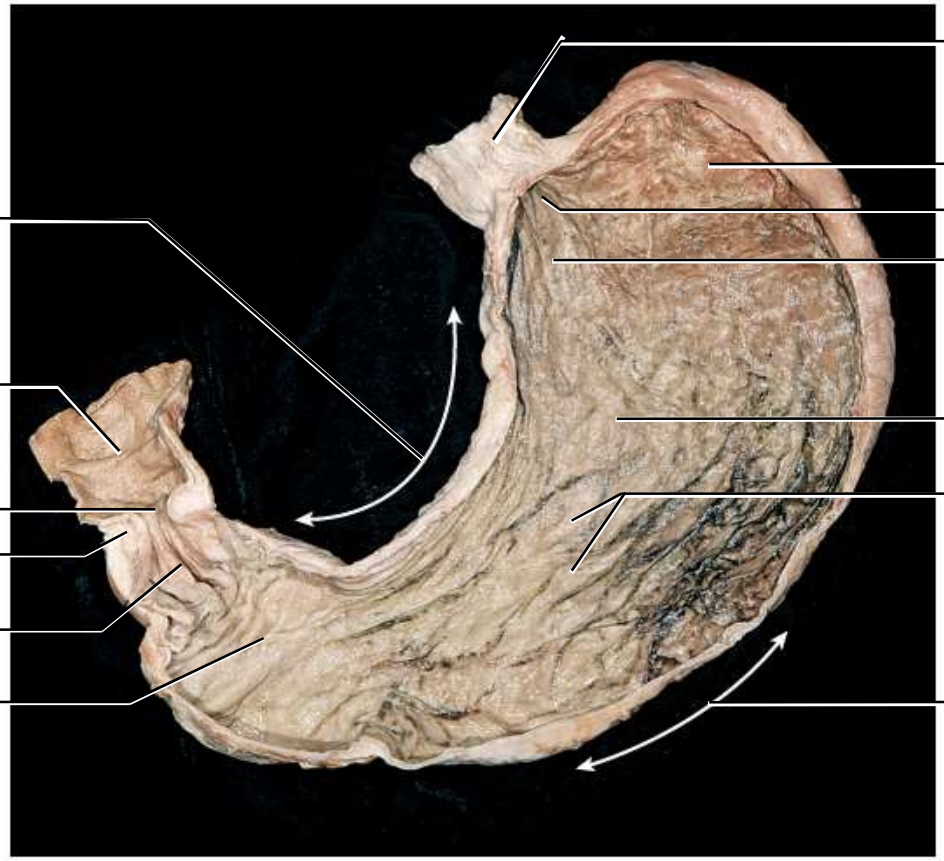

longitudinal wrinkles called **rugae** can be seen in empty stomach wall.

Gross Anatomy of Stomach

- J-shaped muscular organ with lesser and greater curvatures // nearly vertical in tall people, and horizontal in short people
  - divided into four regions
    - cardiac region (cardia) – small area within about 3 cm of the cardiac orifice
    - fundic region (fundus) – dome-shaped portion superior to esophageal attachment
    - body (corpus) – makes up the greatest part of the stomach
    - pyloric region – narrower pouch at the inferior end
      - subdivided into the funnel-like antrum
      - and narrower pyloric canal that terminates at pylorus
      - pylorus – narrow passage to duodenum
  - pyloric sphincter (gastroduodenal) – regulates the passage of chyme into the duodenum

Microscopic Anatomy

- **simple columnar epithelium** covers mucosa
  - apical regions of its surface cells are filled with **mucin**
  - swells with water and becomes **mucus** after it is secreted
- mucosa and submucosa flat when stomach is full, but form longitudinal wrinkles called **gastric rugae** when empty
- **muscularis externa** has three layers instead of two /// outer longitudinal, middle circular and inner oblique layers
- **gastric pits** – depressions in gastric mucosa
  - lined with simple columnar epithelium
  - two or three tubular glands open into the bottom of each gastric pit
  - **cardiac glands** in cardiac region
  - **pyloric glands** in pyloric regions
  - **gastric glands** in the rest of the stomach

Microscopic Anatomy

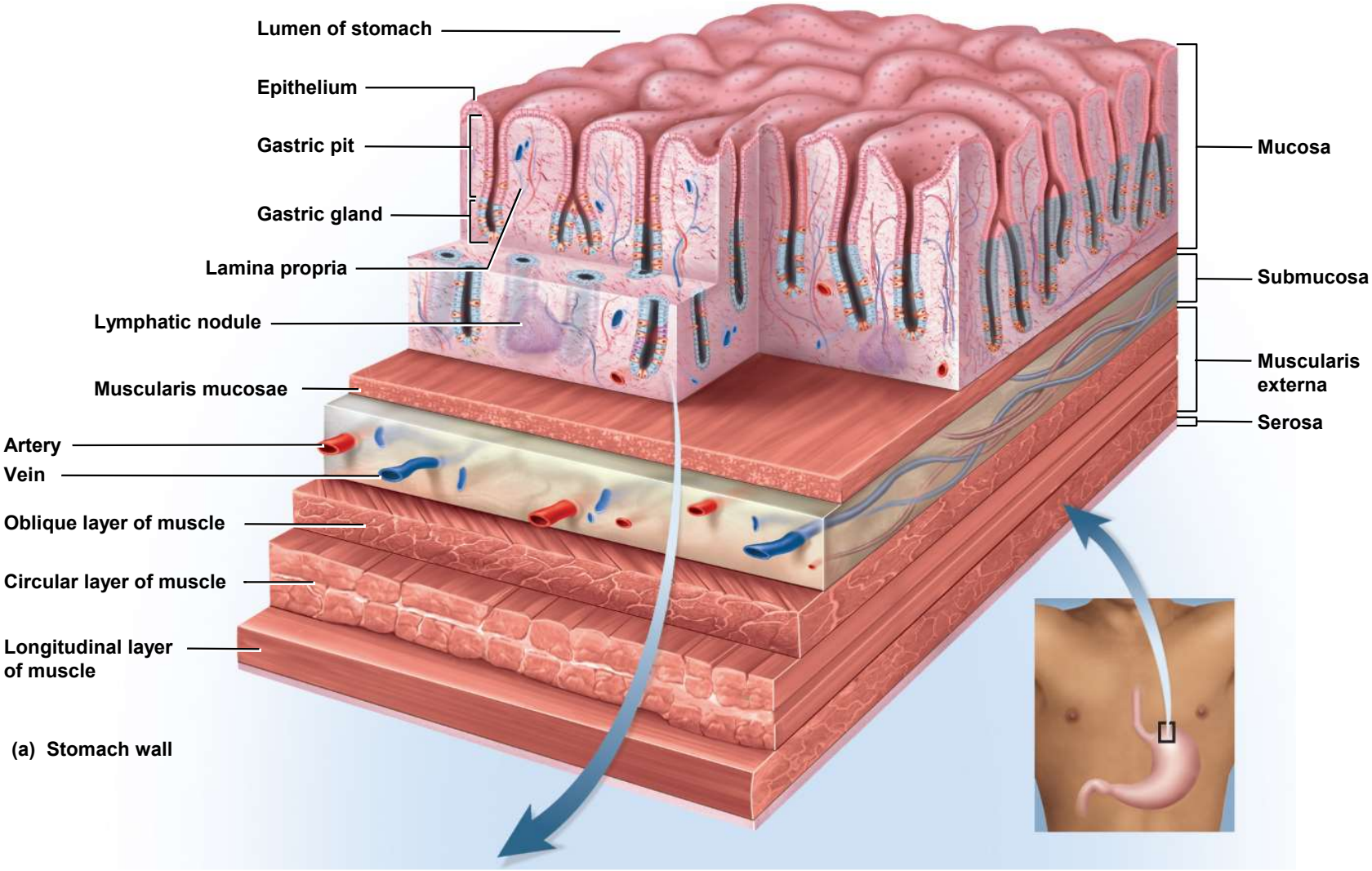

(a) Stomach wall

Note difference between the wall of stomach and the wall of intestine.

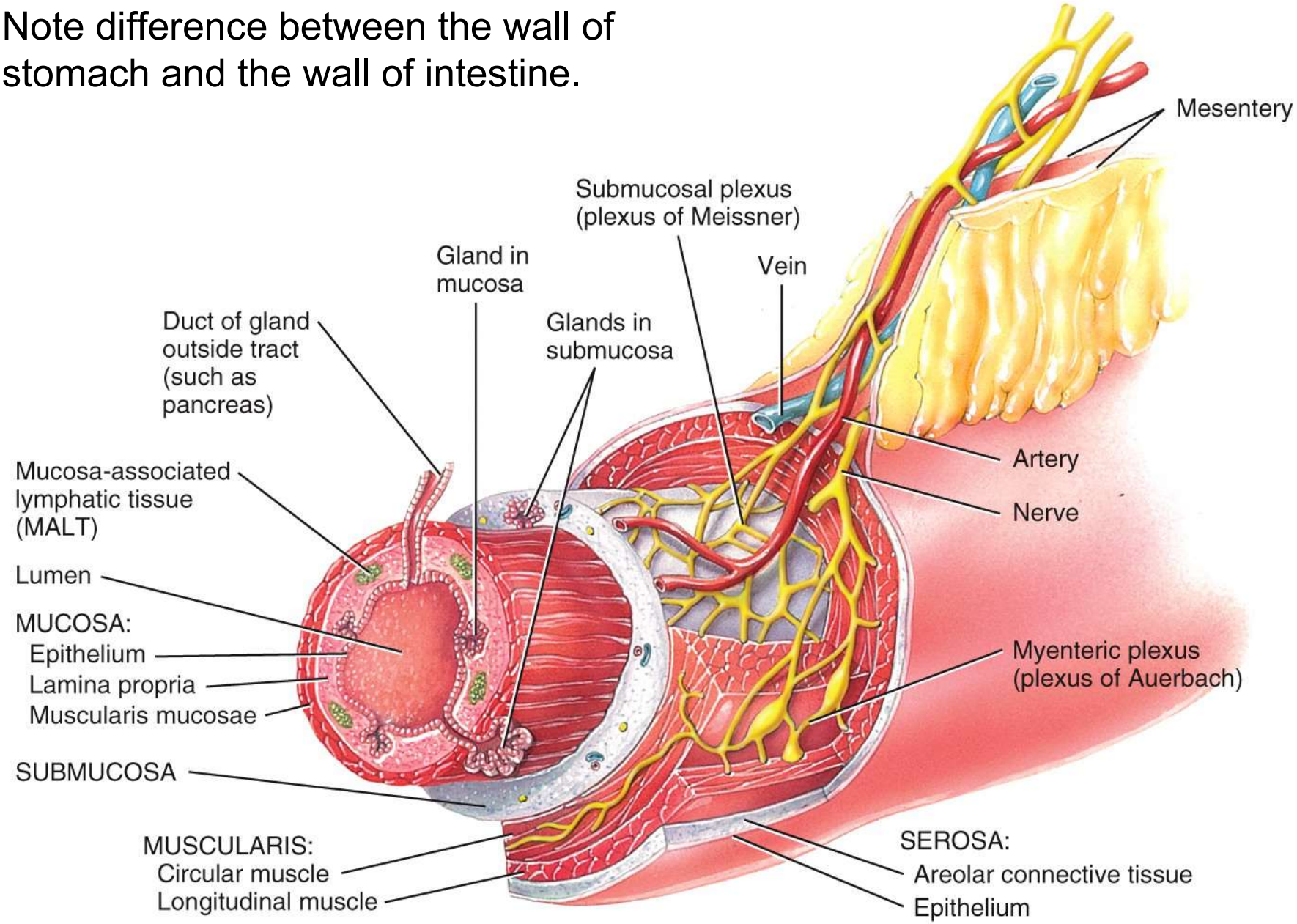

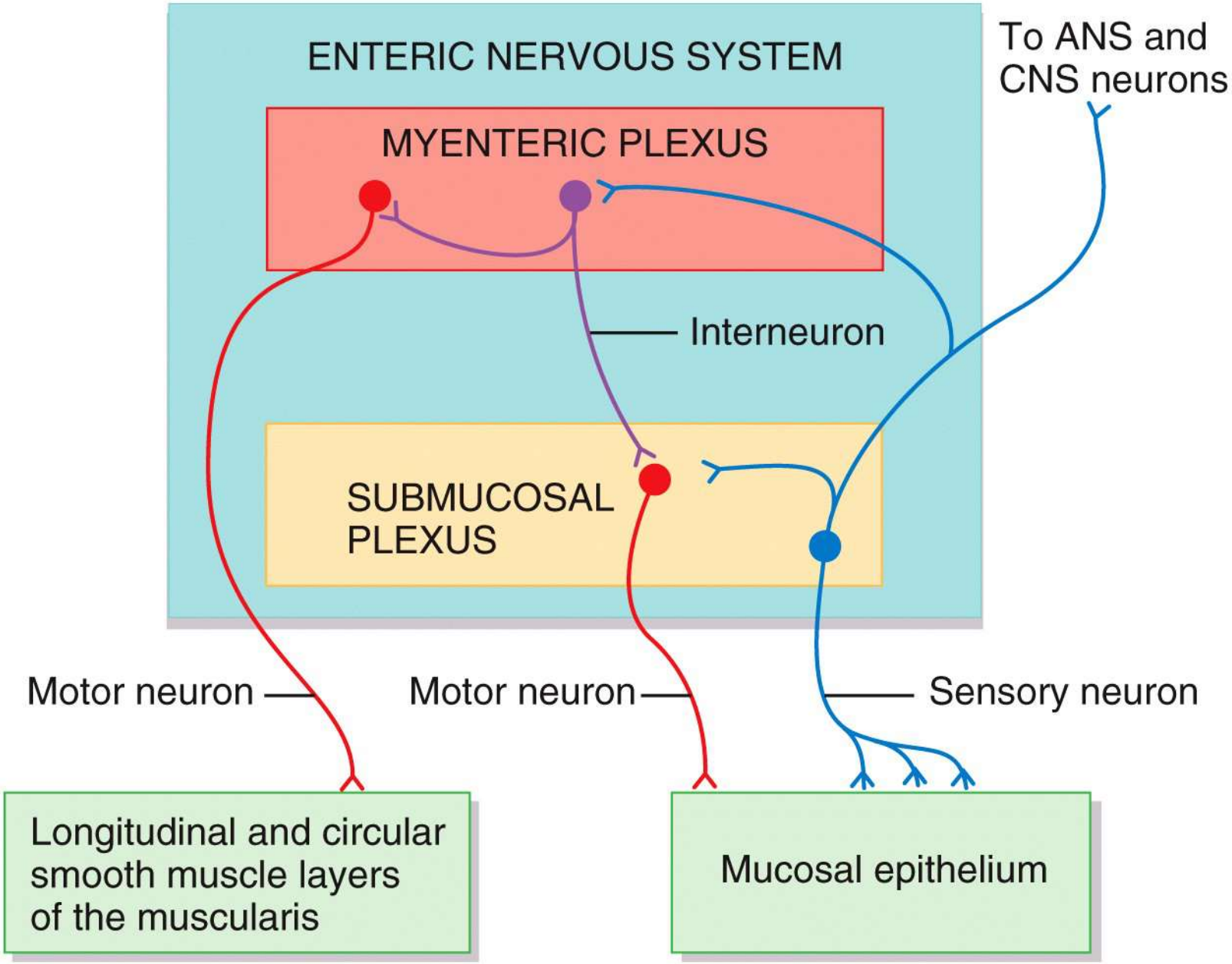
ENTERIC NERVOUS SYSTEM
To ANS and CNS neurons
MYENTERIC PLEXUS
Interneuron
SUBMUCOSAL PLEXUS
Motor neuron
Motor neuron
Sensory neuron
Longitudinal and circular smooth muscle layers of the muscularis
Mucosal epithelium

Opening of Gastric Pit

Visuals Unlimited

Pyloric and Gastric Glands

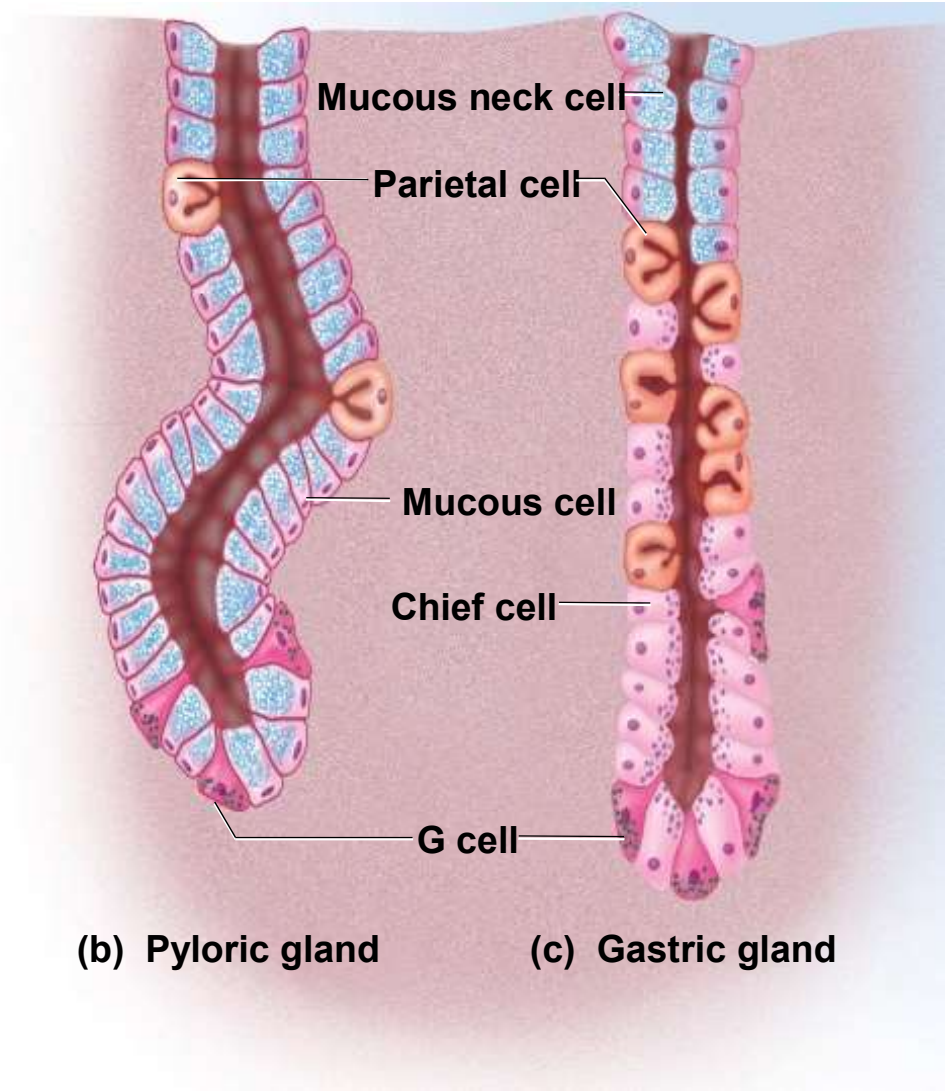

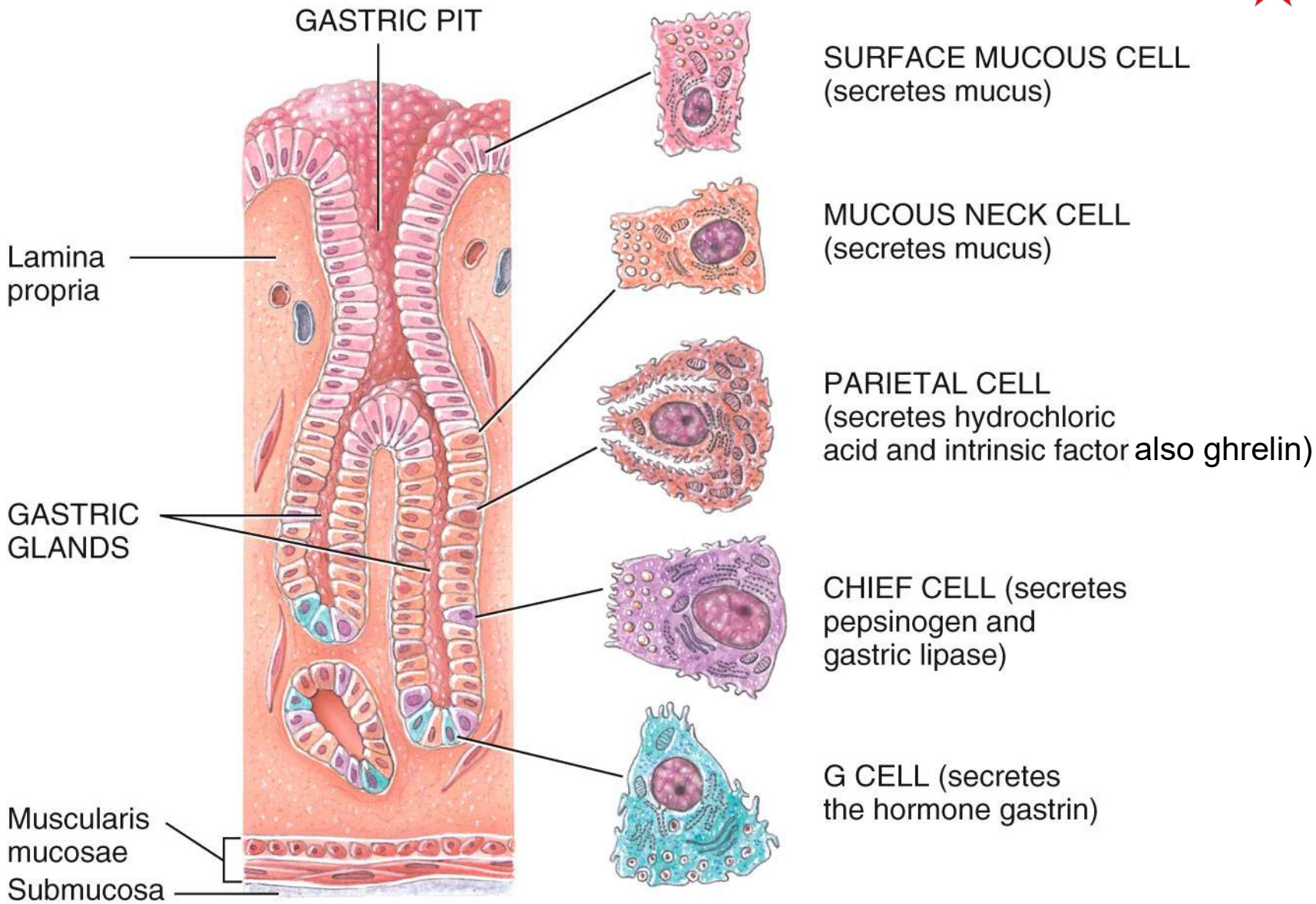

(b) Sectional view of the stomach mucosa showing gastric glands and cell types

Cells of Gastric Glands

- **Mucous cells** – secrete mucus
  - predominate in cardiac and pyloric glands
  - in gastric glands, called **mucous neck cells** since they are concentrated at the neck of the gland
- **Regenerative (stem) cells** – found in the base of the pit and in the neck of the gland
  - divide rapidly and produce a continual supply of new cells to replace cells that die
- **Parietal cells** – found mostly in the upper half of the gland
  - hydrochloric acid (HCl)
  - intrinsic factor
  - ghrelin / hunger hormone / stomach empty sends signal to hypothalamus – go find food!

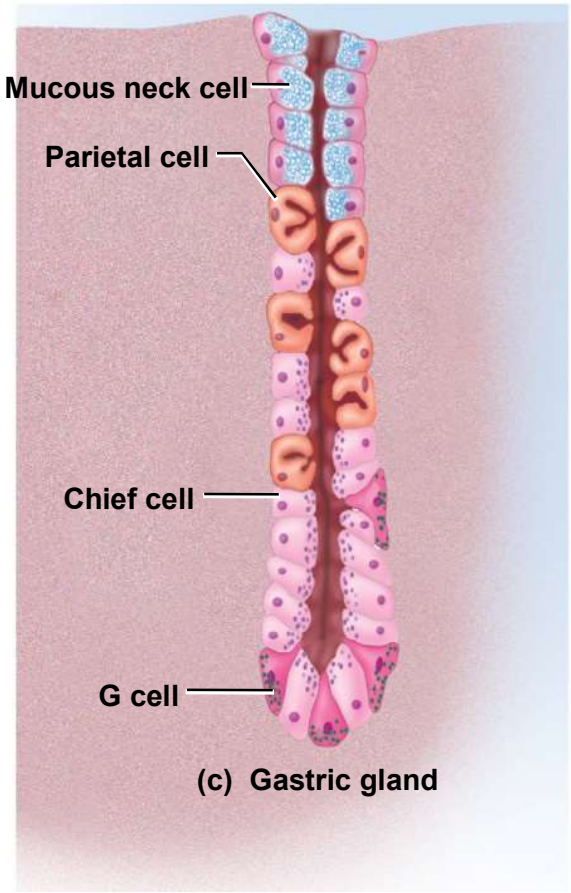

(c) Gastric gland

Cells of Gastric Glands

- **Chief cells** – most numerous
  - secrete **gastric lipase** and **pepsinogen**
  - dominate lower half of gastric glands
  - absent in pyloric and cardiac glands

- **Enteroendocrine cells** – concentrated in lower end of gland
  - up to eight different cell lines (e.g. G cell = gastrin)
  - secrete **hormones** and **paracrine messengers** that regulate digestion

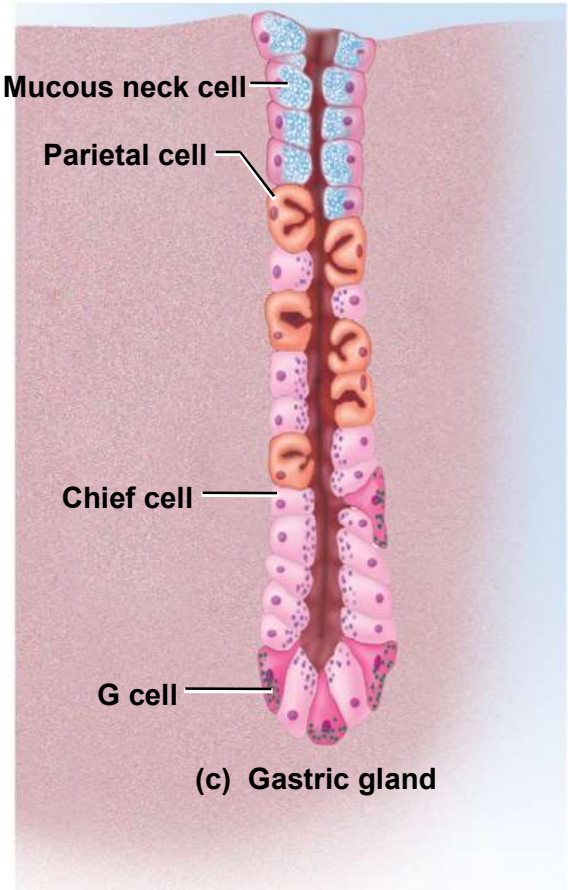

Gastric Secretions

- **Gastric juice –** 2 – 3 liters per day produced by the gastric glands

- Mainly a mixture of water, hydrochloric acid, and pepsin

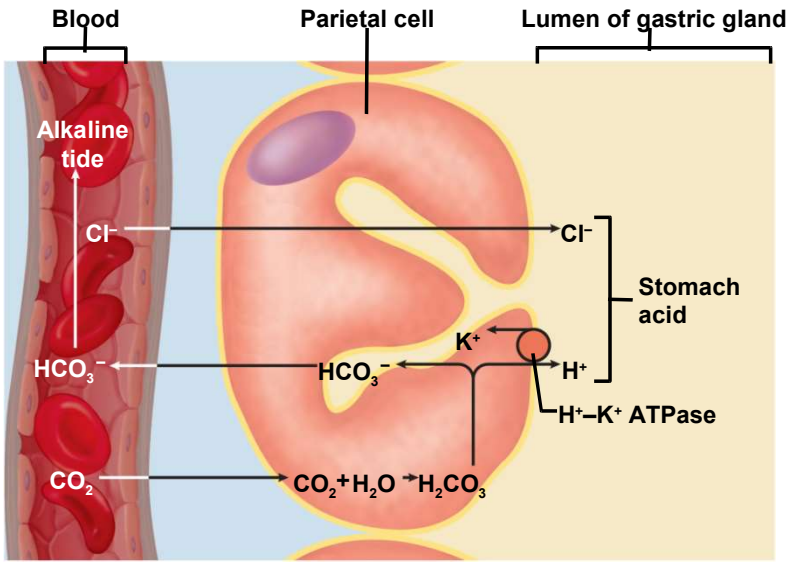

Hydrochloric Acid

- **Gastric juice** has a high concentration **of hydrochloric acid** /// pH as low as 0.8
- **Parietal cells produce HCl** (use carbonic anhydrase (CAH) to make HCl)
- See Next Slide

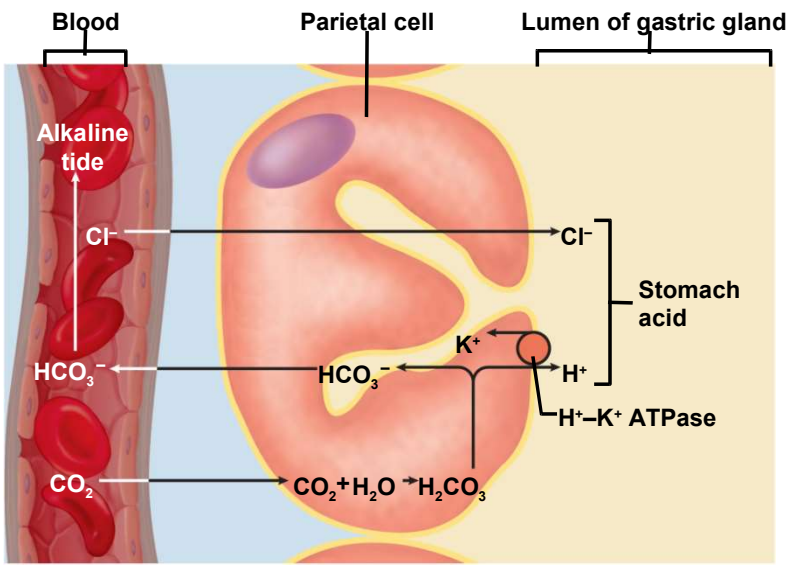

Hydrochloric Acid

- $CO_2 + H_2O \xrightarrow{\text{Carbonic Anhydrase}} H_2CO_3 \rightarrow HCO_3^- + H^+$

- **H^+** is pumped into gastric gland's lumen by the antiport, **H^+- K^+ ATPase** pump /// antiporter uses ATP to pump H^+ out and K^+ in

- **HCO_3^-** exchanged for **Cl^- (chloride shift)** from blood plasma

  - **Cl^-** (chloride ion) pumped into the lumen of gastric gland to join H^+ forming **HCl**

  - elevated HCO_3^- (bicarbonate ion) in blood causes **alkaline tide** increasing blood pH

Functions of Hydrochloric Acid

- Activates **pepsin** and **lingual lipase**
- Breaks up connective tissues and plant cell walls // helps liquefy food to form **chyme**
- Converts ingested **ferric ions (Fe^{3+})** to **ferrous ions (Fe^{2+})** // Fe^{2+} absorbed and used for hemoglobin synthesis
- Contributes to nonspecific disease resistance by destroying most ingested pathogens

Pepsin

- Zymogens are digestive enzymes secreted as inactive proteins /// converted to active enzymes by removing some of their amino acids

- Pepsinogen is a zymogen secreted by the chief cells /// *HCl converts pepsinogen into pepsin after enzyme is inside stomach*

  – hydrochloric acid removes some of its amino acids and forms pepsin that digests proteins

  – autocatalytic effect – as some pepsin is formed, it converts more pepsinogen into more pepsin // positive feedback mechanism

- Pepsin digests dietary proteins into shorter peptide chains

  – Note: protein digestion starts in stomach and is completed in the small intestine

Production and Action of Pepsin

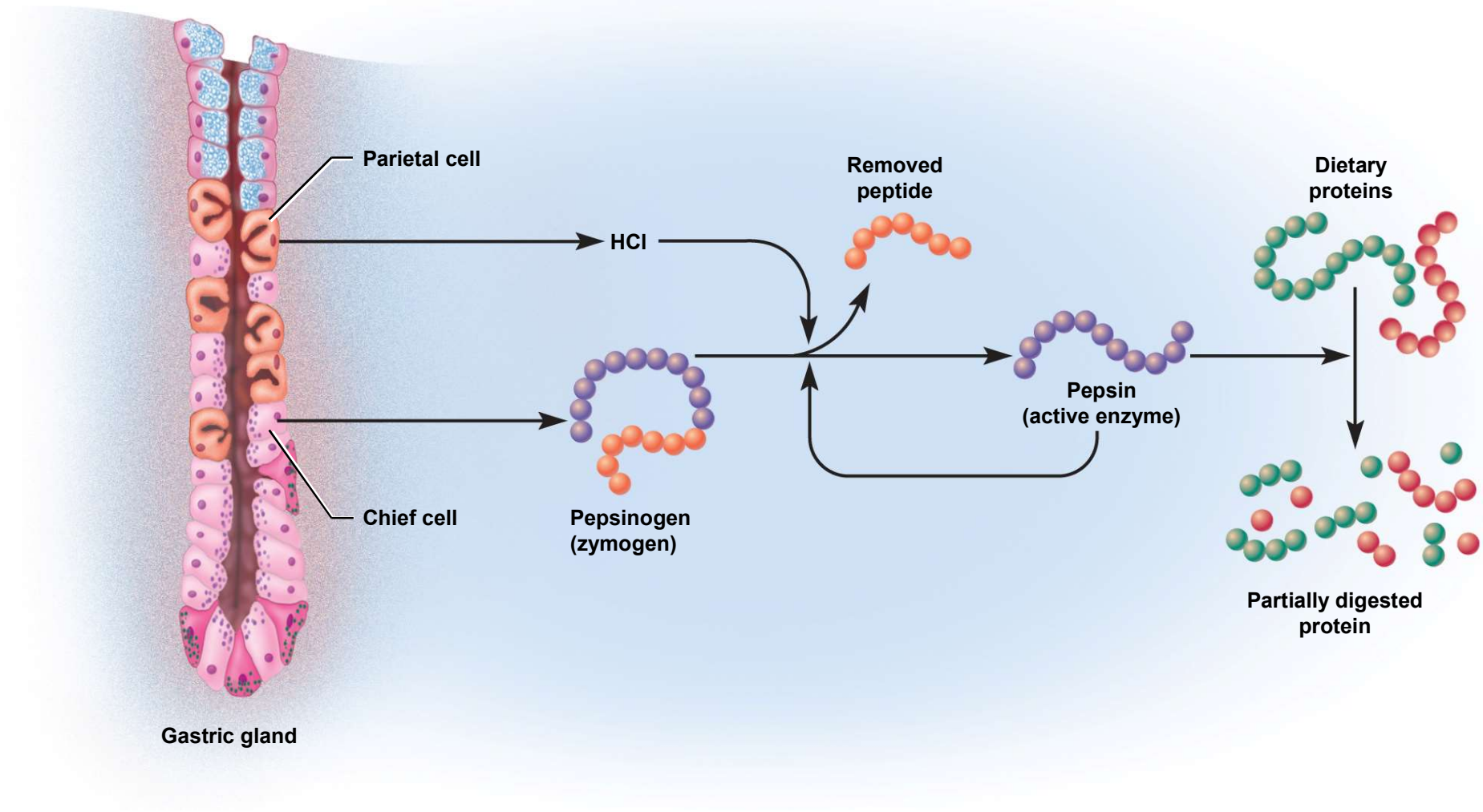

Gastric Lipase

- Produced by **chief cells**
- Important for infants (not produced in adults)
- **Gastric lipase** and **lingual lipase** play a minor role in digesting dietary fats
  - digests 15% of dietary fats in the stomach
  - <u>pancreatic lipase accounts for 85% of fats digested in the small intestine</u>

Intrinsic Factor

- A glycoprotein secreted by parietal cells
- Intrinsic factor is essential for the absorption of vitamin B_{12} by the small intestine
  - binds vitamin B_{12} and intestinal cells absorb this complex by receptor-mediated endocytosis
- Vitamin B_{12} is needed to synthesize hemoglobin // required to prevents pernicious anemia
- Secretion of intrinsic factor is the only indispensable function of the stomach
  - digestion can continue if stomach is removed (gastrectomy), but B_{12} supplements will be needed

Chemical Messengers of the Small Intestines

- Gastric glands, pyloric glands, and epithelial cells of the duodenum have various kinds of **enteroendocrine cells** that produce as many as 20 chemical messengers
  - some are **hormones** enter blood and stimulate distant cells
  - others are **paracrine** secretions that stimulate neighboring cells
    - Some of these chemical messengers are peptides and are produced in both the digestive tract and the central nervous system /// these are called **gut-brain peptides**
      - substance P, vasoactive intestinal peptide (VIP), gastric inhibitory peptide (GIP), neuropeptide Y (NPY)
      - Secretin, cholecystokinin, and glucose dependent insulintropic peptide (gastric inhibiting peptide) (secreted by duodenum / know the action of these enteroendocrine hormones)

Learning Objective #5

Discuss the functions of the stomach and explain the process of the emptying of the stomach.

Gross Anatomy of Stomach

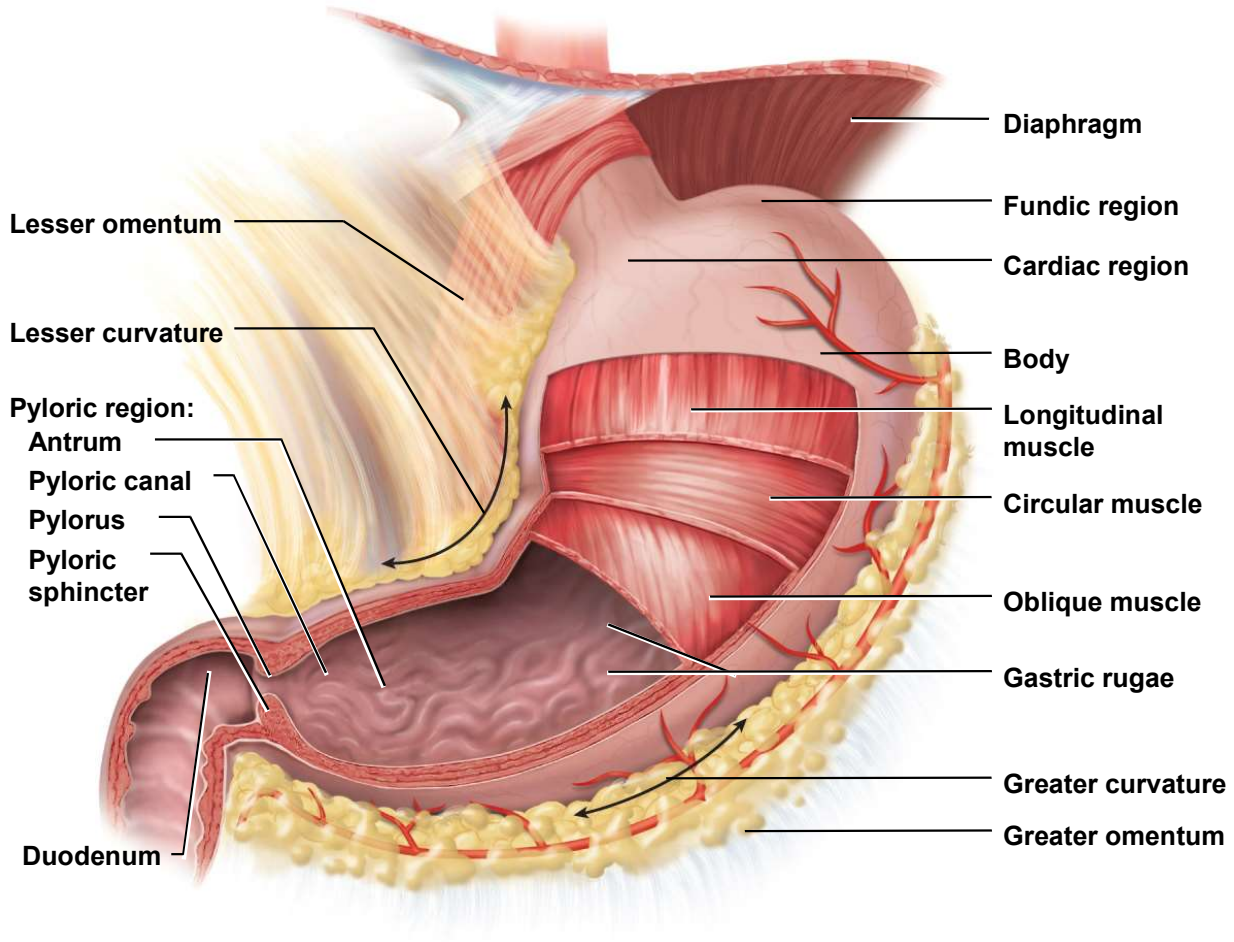

bulge of fundus, narrowing of pyloric region, thickness of pyloric sphincter, and greater and lesser curvatures

Stomach

- Muscular sac in upper left abdominal cavity immediately inferior to the diaphragm
- Primary function is as a food storage organ and designed to release “small volumes” into duodenum
  - internal volume of about 50 mL when empty
  - 1.0 – 1.5 L after a typical meal
  - up to 4 L when extremely full and will extend nearly as far as the pelvis
  - takes approximately 4 hours to clear normal meal
  - antrum hold 30 ml
  - 3 ml of chyme released into duodenum per contraction

Stomach

- Mechanical digestion breaks up bolus, turns solid food into a liquid, and begins chemical digestion of protein and fat
  - chyme – soupy or pasty mixture of semi-digested food in the stomach
- Chemical digestion
  - Salivary amilase / deactivated by gastric acid
  - Lingual and gastric lipase / activated by gastric acid
  - Gastric HCl denatures protein
  - Gastric Pepsinogen converted by gastric HCl into active pepsin
- Most chemical digestion occurs after the chyme passes into the small intestine (99%)

Innervation and Circulation

- Stomach receives:
  - parasympathetic fibers from vagus
  - sympathetic fibers from celiac ganglia
- Supplied with blood by branches of the celiac trunk
- Blood drained away from stomach and intestines to enter hepatic portal circulation // delivers nutrient rich hydrophilic nutrients directly to liver
  - filtered through liver before returning to systemic circulation via inferior vena cava // liver gets first pass of all water soluble nutrients!

Gastric Motility

- Swallowing center in medulla oblongata signals stomach to relax

- Also - Food stretches stomach activating a receptive-relaxation response /// resists stretching briefly // but then relaxes to hold more food

- Stomach now starts to shows a rhythm of peristaltic contractions which are controlled by pacemaker cells in longitudinal layer of muscularis externa

  - gentle ripple of contraction every 20 seconds churns and mixes food with gastric juice

  - becomes stronger contraction in pyloric region

  - after 30 minutes or so these contractions become quite strong //// they churn the food, mix it with gastric juice, and promote its physical breakup and chemical digestion

Gastric Motility

- Antrum holds about 30 mL of chyme
- As a parastaltic wave passes down the antrum, it moves about **3 mL of chyme** into the duodenum with each contraction
- Allows only a small amount of chyme into the duodenum /// enables the duodenum to
  - **neutralize the stomach acid**
  - **digest nutrients more efficiently**
- If duodenum is over filled then it inhibits gastric motility
- Typical meal emptied from stomach in **4 hours**
  - less time if the meal is more liquid
  - as long as 6 hours for a high fat meal

Digestion and Absorption

- Salivary and gastric enzymes partially digest protein and lesser amounts of starch and fat in the stomach
- Most chemical digestion and nearly all absorption occur after the chyme has passed into the small intestine
- Stomach does not absorb any significant amount of nutrients /// Stomach does absorb aspirin and some lipid-soluble drugs
- Alcohol is absorbed mainly by small intestine // intoxicating effects depends partly on how rapidly the stomach is emptied
  - Note: stomach detoxifies about 20% of poison before it enters small intestine

How Does the Stomach Protect Itself From Digestion?

- Stomach is protected in three ways from the harsh acidic and enzymatic environment it creates
  - mucous coat – thick, highly alkaline mucus resists action of acid and enzymes
  - tight junctions - between epithelial cells prevent gastric juice from seeping between them and digesting the connective tissue of the lamina propria and beyond
  - epithelial cell replacement – stomach epithelial cells live only 3 to 6 days // sloughed off into the chyme and digested with the food // replaced rapidly by cell division in the gastric pits
- Breakdown of these protective measures can result in inflammation and peptic ulcer

Healthy Mucosa and Peptic Ulcer

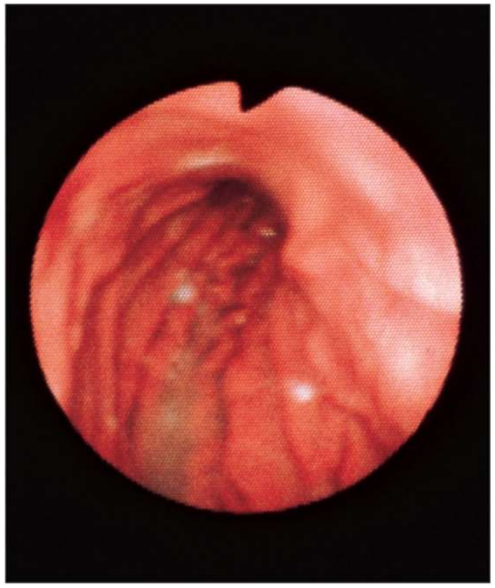

(a) Normal

(b) Peptic ulcer

Gastritis, inflammation of the stomach, can lead to a **peptic ulcer** as pepsin and hydrochloric acid erode the stomach wall

Most ulcers are caused by acid-resistant bacteria, ***Helicobacter pylori*** that can be treated with antibiotics and Pepto-Bismol.

Regulation of Gastric Function

- **Nervous** and **endocrine systems** collaborate to regulate stomach activity
  - increase gastric secretion and motility when food is eaten
  - suppresses them when the stomach empties
- Gastric activity is divided into **<u>three phases</u>**:
  - **cephalic phase** – stomach being controlled by brain
  - **gastric phase** – stomach controlling itself
  - **intestinal phase** – stomach being controlled by small intestine
- Phases over-lap and can occur simultaneously

Regulation of Gastric Function – Cephalic Phase

- **First Phase = cephalic phase**
  - **stomach responds** to site, smell, taste, or thought of food
  - sensory and mental inputs converge on the **hypothalamus** // relays signals to **medulla oblongata**
  - **vagus nerve** fibers from medulla oblongata stimulate the **enteric nervous system** of stomach // this then in in turn, stimulates gastric secretion

Regulation of Gastric Function – Gastric Phase

- **Second Phase = gastric phase**
  - period in which swallowed food and semi-digested protein in stomach activates gastric activity /// **two-thirds of gastric secretion** occurs in this phase
  - ***ingested food stimulates gastric activity in two* ways**:
    - by **stretching the stomach**
      - activates **short reflex** mediated through **myenteric nerve plexus**
      - activates **long reflex** mediated through the **vagus nerves and the brainstem**
    - by **increasing the pH** of its contents

Regulation of Gastric Function – Gastric Phase

- **More on Second Phase**
  - **gastric secretion is stimulated by three chemicals**
    - **acetylcholine (ACh)** – secreted by parasympathetic nerve fibers
    - **histamine** – a paracrine secretion from enteroendocrine cells in the gastric glands
    - **gastrin** – a hormone produced by the enteroendocrine cells (i.e. **G cells**) in pyloric glands

Regulation of Gastric Function – Intestinal Phase

- **Third Phase = intestinal phase**
  - stage in which the duodenum responds to arriving chyme and moderates gastric activity through hormones and nervous reflexes
  - duodenum **initially enhances** gastric secretion, but **soon inhibits it**
    - stretching of the duodenum accentuates vagovagal reflex that stimulates the stomach
    - peptides and amino acids in chyme stimulate **G cells** of the duodenum to secrete more **gastrin** which further stimulates the stomach

Regulation of Gastric Function - Intestinal Phase

- **The Enterogastric Reflex**
  - duodenum sends **inhibitory signals** to the stomach by way of the enteric nervous system
  - Enteroendocrines also participate in this reflex (see next slide)
  - At same time signals also sent to the medulla oblongata - triggered by acid and semi-digested fats in the duodenum
    - » **inhibits vagal nuclei** – reducing vagal stimulation of the stomach
    - » **stimulate sympathetic neurons** – send inhibitory signals to the stomach

Regulation of Gastric Function – Enterogastric Reflex

- Chyme also stimulates duodenal enteroendocrine cells to release these hormones: secretin, cholecystokinin, and glucose dependent insulinotropic peptide (old name gastric inhibiting peptide)
  - these hormones stimulate secretions from the pancreas and gall bladder
  - also suppress gastric secretion
  - stimulates insulin secretion in preparation for processing nutrients about to be absorbed by the small intestine
- Pyloric sphincter contracts tightly to limit chyme entering duodenum // gives duodenum time to work on chyme

Regulation of Gastric Function

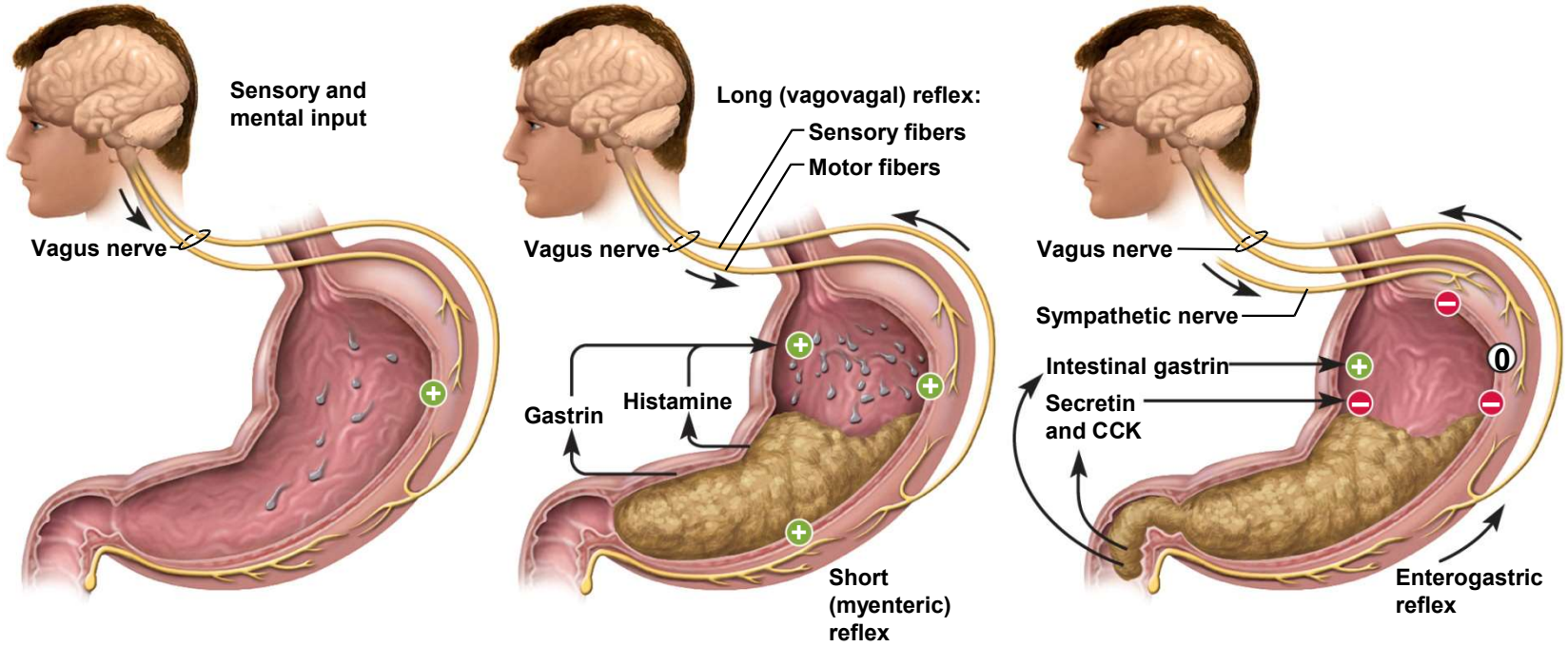

1 Cephalic phase
Vagus nerve stimulates gastric secretion even before food is swallowed.

Key
- ⊕ Stimulation
- ⊖ Inhibition
- 0 Reduced or no effect

2 Gastric phase
Food stretches the stomach and activates myenteric and vagovagal reflexes. These reflexes stimulate gastric secretion. Histamine and gastrin also stimulate acid and enzyme

3 Intestinal phase
Intestinal gastrin briefly stimulates the stomach, but then secretin, CCK, and the enterogastric reflex inhibit gastric secretion and motility while the duodenum processes the chyme already in it. Sympathetic nerve fibers suppress gastric activity, while vagal (parasympathetic) stimulation of the stomach is now inhibited.

Positive Feedback Control- Gastric Secretion

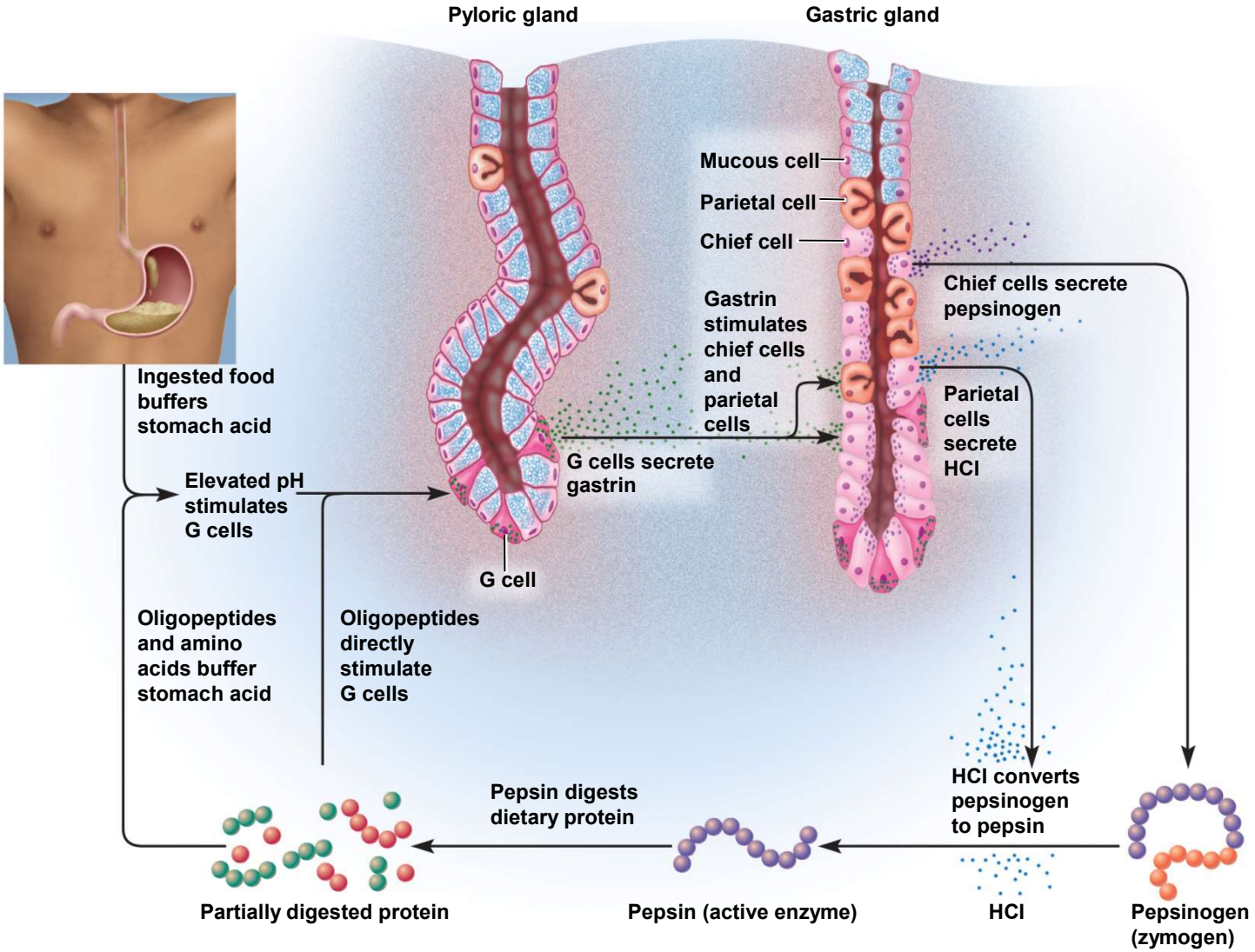

Learning Objective #6

Discuss the size and divisions of the small and large intestines.

Small Intestine

- Nearly all chemical digestion and nutrient absorption occurs in small intestine (99%)

- The longest segment of the digestive tract

  - 2.7 to 4.5 m long in a living person

  - 4 to 8 m long in a cadaver where there is no muscle tone

- The small in small intestine refers to the diameter not its length // diameter = 2.5 cm (1 inch)

Gross anatomy of the small intestine.

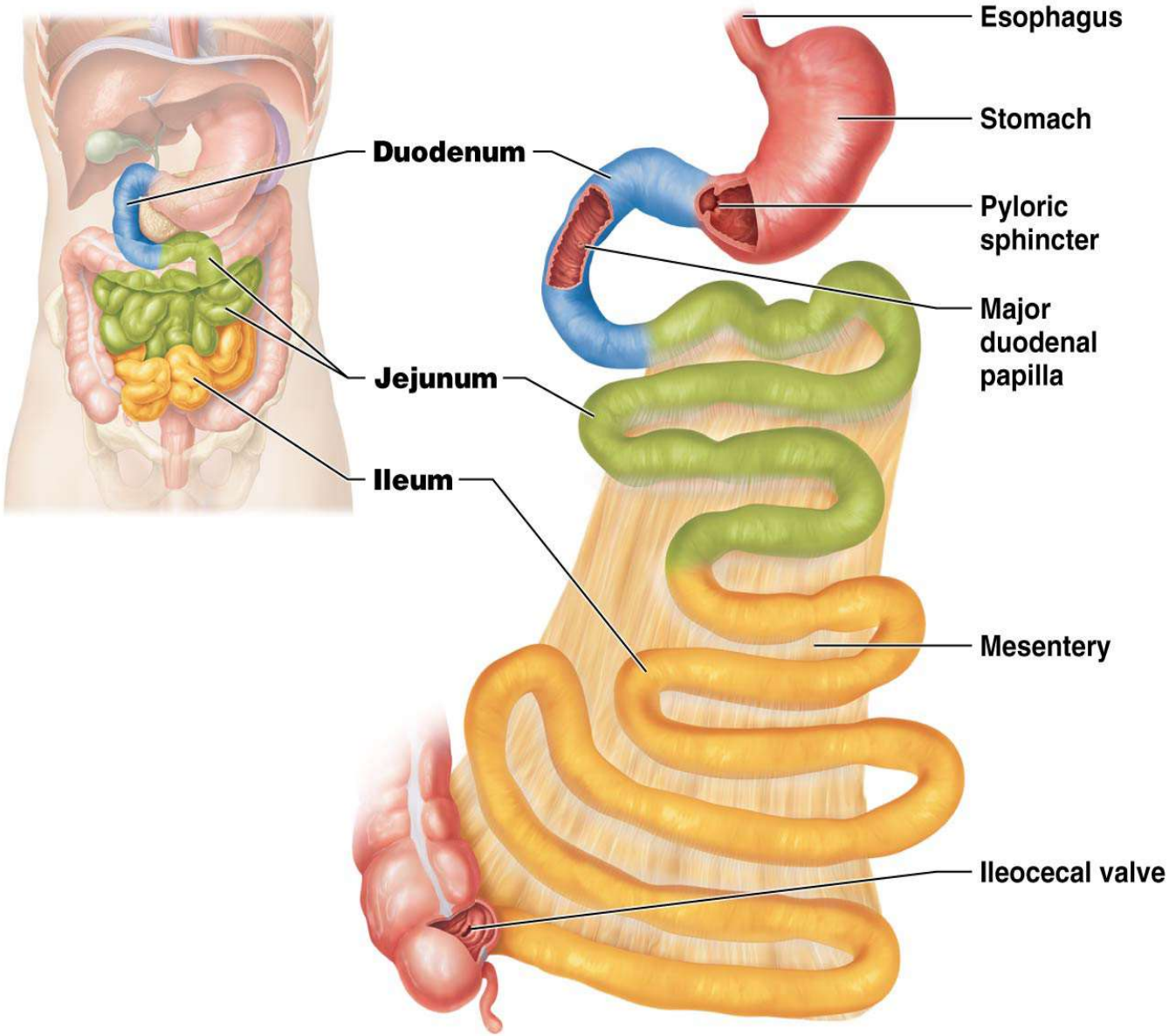

Small Intestine

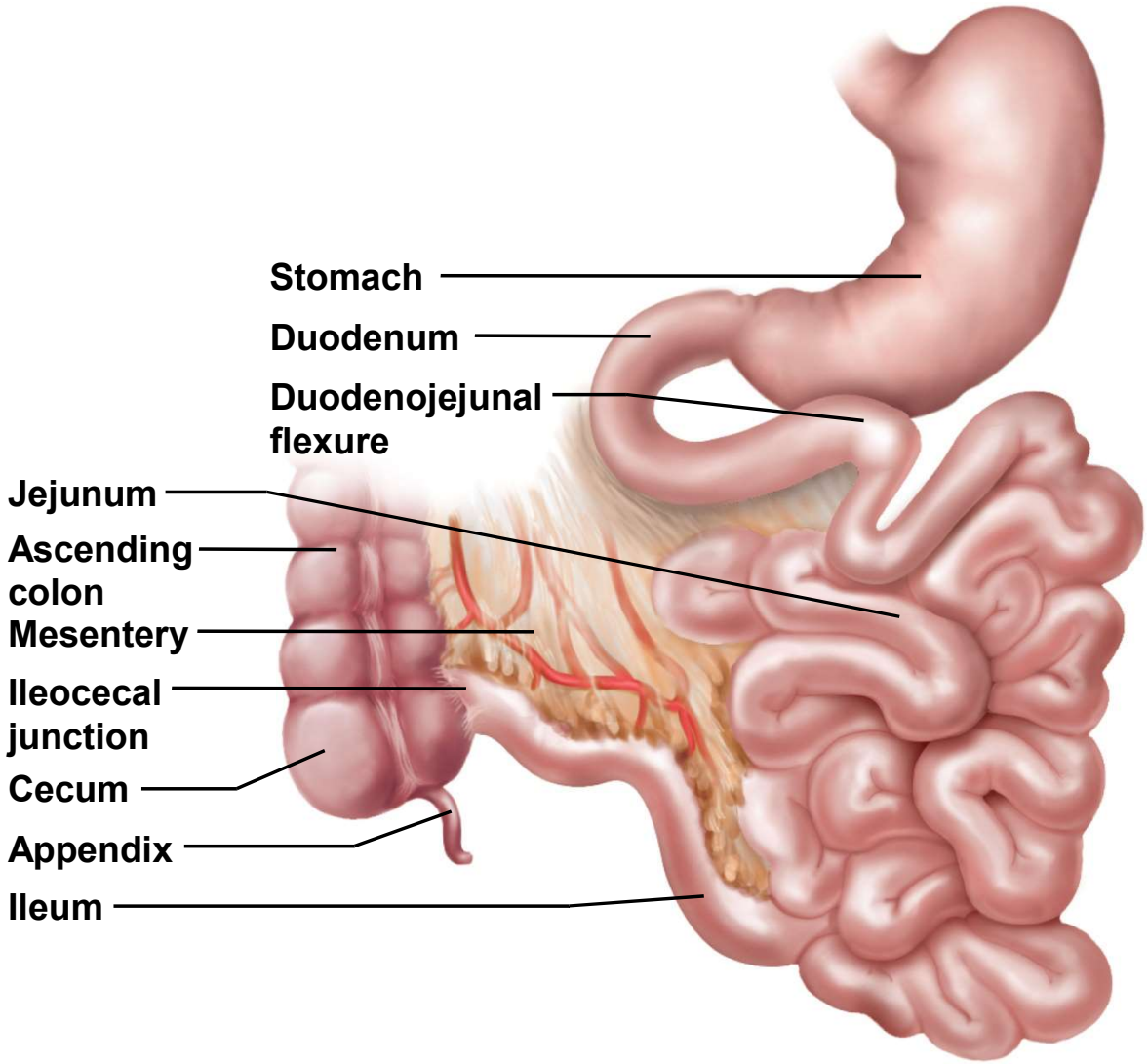

Coiled mass filling most of the abdominal cavity inferior to the stomach and the liver

Duodenum

- **Small intestine divided into three regions**
- **Duodenum**
  - the first 25 cm (10 inches)
  - begins at the **pyloric valve**
    - **major and minor duodenal papilla** distal to pyloric valve
    - receives **major and minor pancreatic ducts** respectively
  - arches around the **head of the pancreas**
  - ends at a sharp bend called the **duodenojejunal flexure**
  - most is **retroperitoneal**

Gross Anatomy

- **More about duodenum**
  - receives stomach contents, pancreatic juice, and bile
  - stomach acid is neutralized here
  - fats are **physically broken up (emulsified)** by the bile acids
  - **pepsin** is inactivated by increased pH
  - **pancreatic enzymes** take over the job of chemical digestion

Jejunum

- Jejunum
  - first 40% of small intestine beyond duodenum
  - roughly 1.0 to 1.7 m in a living person
  - has large, tall, closely spaced circular folds
  - its wall is relatively thick and muscular
  - especially rich blood supply which gives it a red color
  - most digestion and nutrient absorption occurs here
  - jejunum means empty

Ileum

- Ileum
  - forms the last 60% of the post duodenal small intestine
  - about 1.6 to 2.7 m
  - thinner, less muscular, less vascular, and paler pink color
  - Peyer patches – prominent lymphatic nodules in clusters on the side opposite the mesenteric attachment
    - readily visible with the naked eye
    - become progressively larger approaching the large intestine

Gross Anatomy

- **ileocecal junction**
  - the end of the small intestine
  - where the **ileum** joins the **cecum** of the large intestine
- **ileocecal valve**
  - a sphincter formed by the thickened muscularis of the ileum
  - protrudes into the cecum // regulates passage of food residue into the large intestine
- both jejunum and ileum are **intraperitoneal** and covered with **serosa**

Intestinal Secretion

- **Intestinal crypts** secrete 1 to 2 L of **intestinal juice** per day
  - in response to acid, hypertonic chyme, and distension of the intestines
  - pH of 7.4 to 7.8
  - contains water, mucus, and very little enzyme
  - most enzymes that function in the small intestine are found in the brush border or secreted in pancreatic juice

Anatomy of Large Intestine

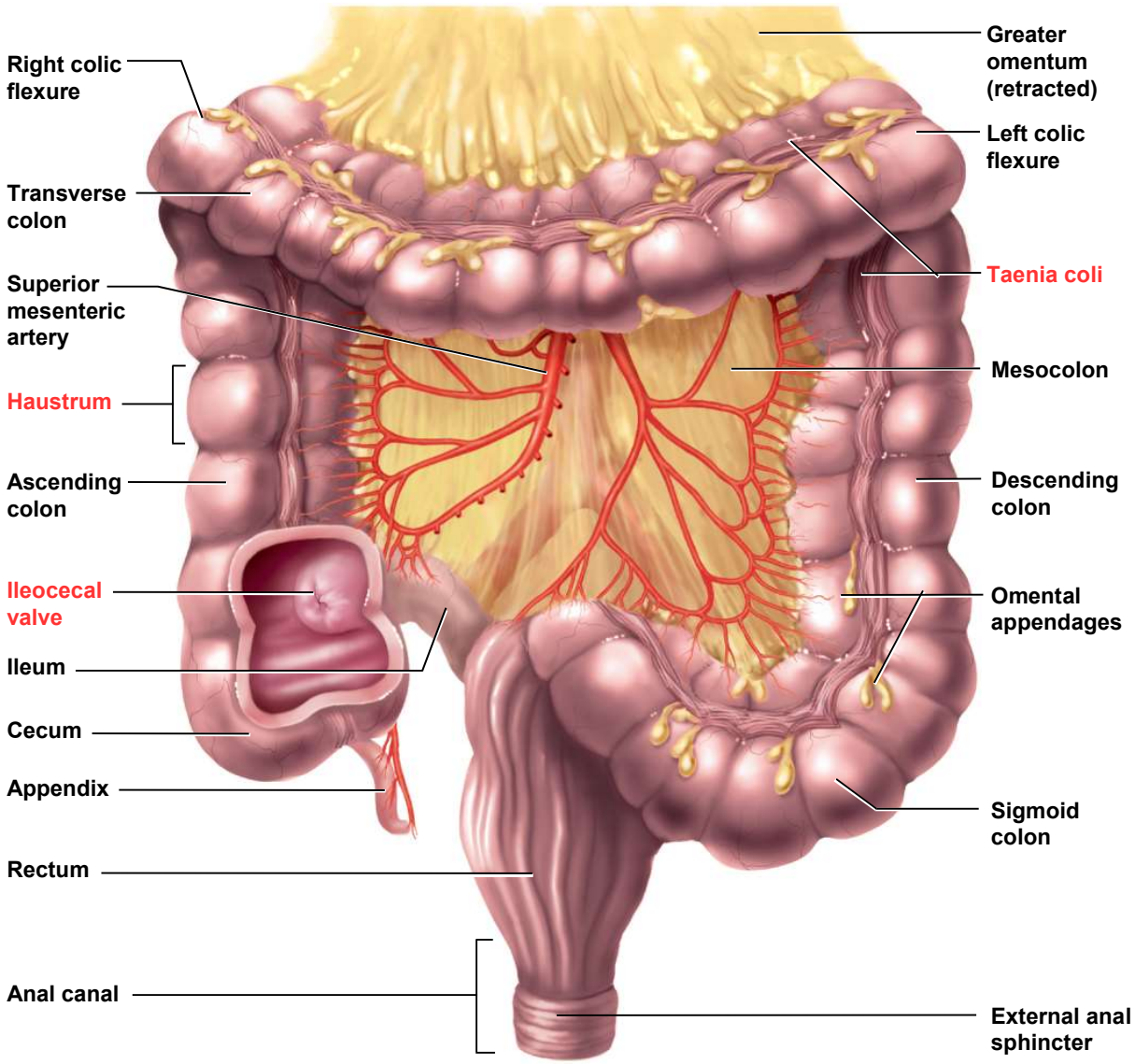

Gross Anatomy of Large Intestine

- **Large intestine**

  –measures 1.5 m (5 ft) long and 6.5 cm (2.5 in) in diameter in cadaver

  –begins as **cecum** inferior to ileocecal valve

  –**appendix** attached to the lower end of the cecum /// densely populated with lymphocytes and is a significant source of immune cells

  –ascending colon, right colic (hepatic) flexure, transverse colon, left colic (splenic) flexure, and descending colon frame the small intestine

  –sigmoid colon is S-shaped portion leading down into pelvis

Gross Anatomy of Large Intestine

- Muscularis externa unusual structue
  - taenia coli – longitudinal fibers concentrated in three thicken, ribbon like strips
  - haustra – pouches in the colon caused by the muscle tone of the taenia coli
  - internal anal sphincter - smooth muscle of muscularis externa
  - external anal sphincter - skeletal muscle of pelvic diaphragm
  - omental (epiploic) appendages – club-like, fatty pouches of peritoneum adhering to the colon – unknown function

Sigmoid Colon

- Segment between descending colon and rectum

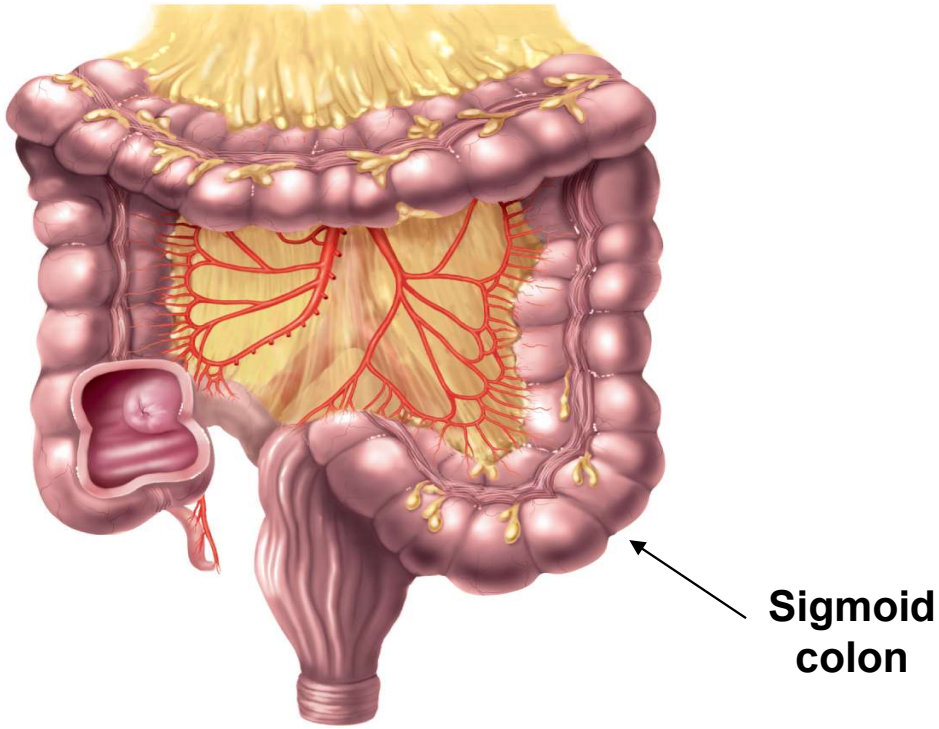

Gross Anatomy of Large Intestine

– **Rectum**

- Stores fecal material prior to defication
- portion ending at anal canal
- has 3 curves and 3 infoldings the transverse rectal folds (rectal valves)

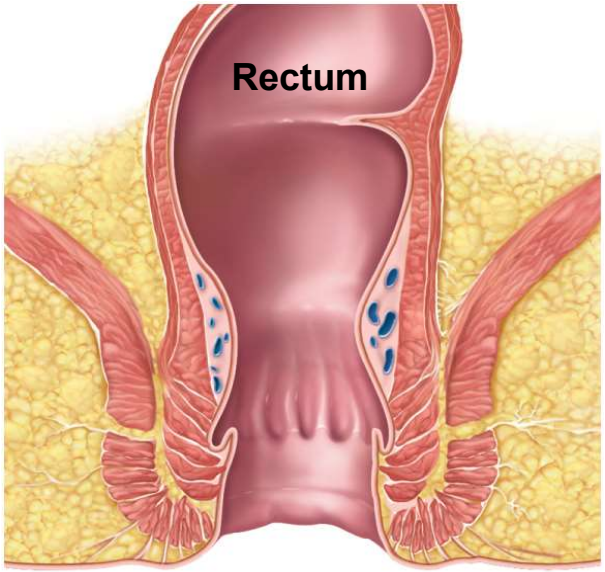

Gross Anatomy of Large Intestine

- **Anal canal** – final 3 cm of the large intestine
  - passes through **levator ani** muscle and pelvic floor
  - terminates at the anus
  - **anal columns and sinuses** – exude mucus and lubricant into anal canal during defecation
  - **large hemorrhoidal veins** for superficial plexus in anal columns and around orifice
  - **hemorrhoids** – permanently distended veins that protrude into the anal canal or form bulges external to the anus

Anatomy of Anal Canal

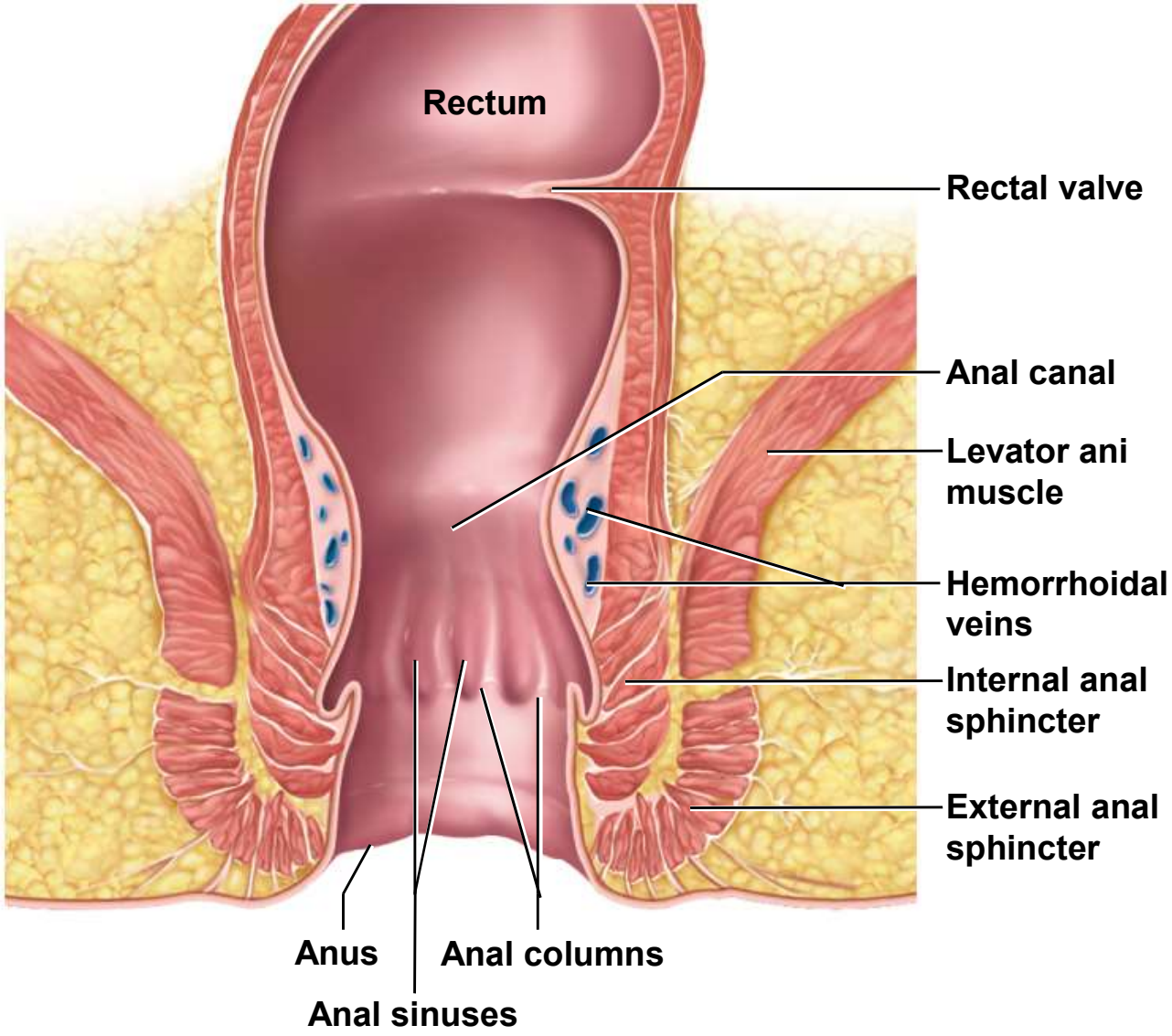

(b) Anal canal

Gross Anatomy of Large Intestine

- Large intestine receives about 500 mL of indigestible residue per day
  - reduces it to about 150 mL of feces by absorbing water and salts
  - feces eliminated by using the **defecation reflex**

Bacterial Flora and Intestinal Gas

- **Bacterial flora** populate large intestine
  - about 800 species of bacteria
  - ferment cellulose and other undigested carbohydrates // we absorb resulting sugars
  - help in synthesis vitamins B and K
- **Flatus** - intestinal gas
  - 7 to 10 L of gas produced daily // Most reabsorbed
  - average person expels 500 mL per day (flatus) // most of this gas is swallowed air and odorless
  - bacteria produce hydrogen sulfide,methane, **indole** and **skatole** /// produce odor of flatus and feces // hydrogen gas may explode during electrical cauterization used in surgery

Microscopic Anatomy

- Mucosa of large intestine
  - simple columnar epithelium through entire large intestine
  - anal canal has nonkeratinized stratified squamous epithelium in its lower half // provides abrasion resistance
- No circular folds or villi to increase surface area
- Intestinal crypts - glands sunken into lamina propria
- Greater density of mucous-secreting goblet cells
- Lamina propria and submucosal layers have large amount of lymphatic tissue /// provide protection from the bacteria that densely populate the LI

Absorption and Motility

- Large intestine takes about 12 to 24 hours to reduce the residue of a meal to feces /// does not chemically change the residue /// reabsorbs water and electrolytes

- **Feces** consist of 75% water and 25% solids - 30% bacteria, 30% undigested fiber, 10 – 20% fat, small amount of mucus and sloughed epithelial cells

- **Haustral contractions** occur every 30 minutes /// this kind of colonic motility is a form of segmentation /// distension of a haustrum stimulates it to contract

- **Mass movements** occur *1 to 3 times a day* /// triggered by **gastrocolic** and **duodenocolic reflexes** /// filling of the stomach and duodenum stimulates motility of the colon /// moves residue for several centimeters with each contraction

Defecation

- Stretching of the rectum stimulates defecation reflexes
  - accounts for the urge to defecate that is often felt soon after a meal
  - **intrinsic defecation reflex** works entirely within the myenteric plexus
    - stretch signals travel through the plexus to the muscularis causing it to contract and internal sphincter to relax /// relatively weak contractions
  - **parasympathetic defecation reflex** involves spinal cord
    - stretching of rectum sends sensory signals to spinal cord
    - pelvic nerves return signals intensifying peristalsis and relaxes the internal anal sphincter
    - defecation occurs only if external anal sphincter is voluntarily relaxed
- Abdominal contractions (Valsalva maneuver) increase abdominal pressure as <u>levator ani lifts anal canal upwards</u> /// feces will fall away

Neural Control of Defecation

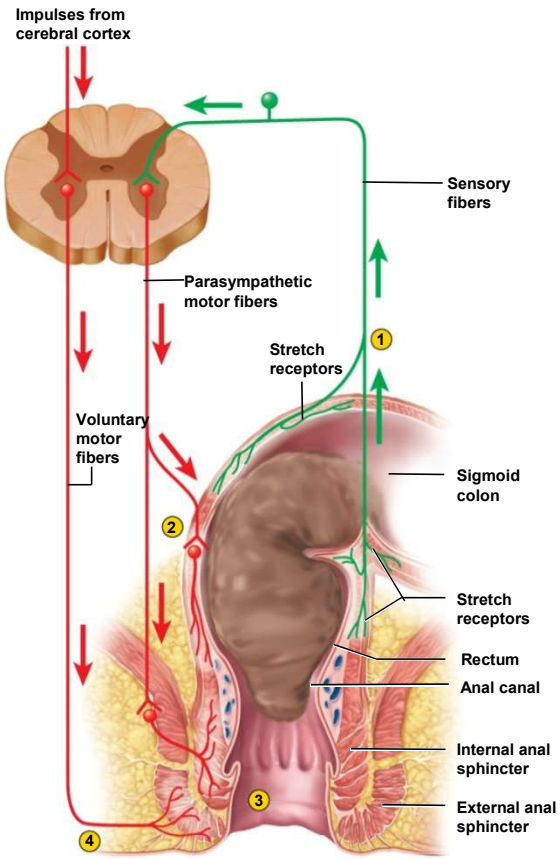

1. Feces stretch the rectum and stimulate stretch receptors, which transmit signals to the spinal cord.
2. A spinal reflex stimulates contraction of the rectum.
3. The spinal reflex also relaxes the internal anal sphincter.
4. Impulses from the brain prevent untimely defecation by keeping the external anal sphincter contracted. Defecation occurs only if this sphincter also relaxes.

1. filling of the rectum
2. reflex contraction of rectum and relaxation of internal anal sphincter
3. voluntary relaxation of external sphincter

Learning Objective #7

Discuss the functions of the liver, gall bladder, and pancreas.

The Liver

- reddish brown gland located immediately inferior to the diaphragm
- body's largest gland // weighs about 1.4 kg (3 pounds)
- variety of critical functions
- **secretes bile** which contributes to digestion /// two major components = bile pigments and bile acids

Gross Anatomy of Liver

- Four lobes - **right**, **left**, **quadrate**, and **caudate**
  - **falciform ligament** separates left and right lobes // sheet of mesentery that suspends the liver from the diaphragm
  - **round ligament (ligamentum teres)** = fibrous remnant of umbilical vein // carries blood from umbilical cord to the liver of the fetus
- From inferior view, squarish **quadrate lobe** next to the **gall bladder** and a tail-like **caudate lobe** posterior to that

Gross Anatomy of Liver

- **porta hepatis** – irregular opening between these lobes
  - point of **entry** for the **hepatic portal vein** and **proper hepatic artery**
  - point of **exit** for the **bile passages**
  - all travel in **lesser omentum**
- **gall bladder –** adheres to a depression on the inferior surface of the liver, between right and quadrate lobes
- **bare area** on superior surface where it is attach to diaphragm

Gross Anatomy of Liver

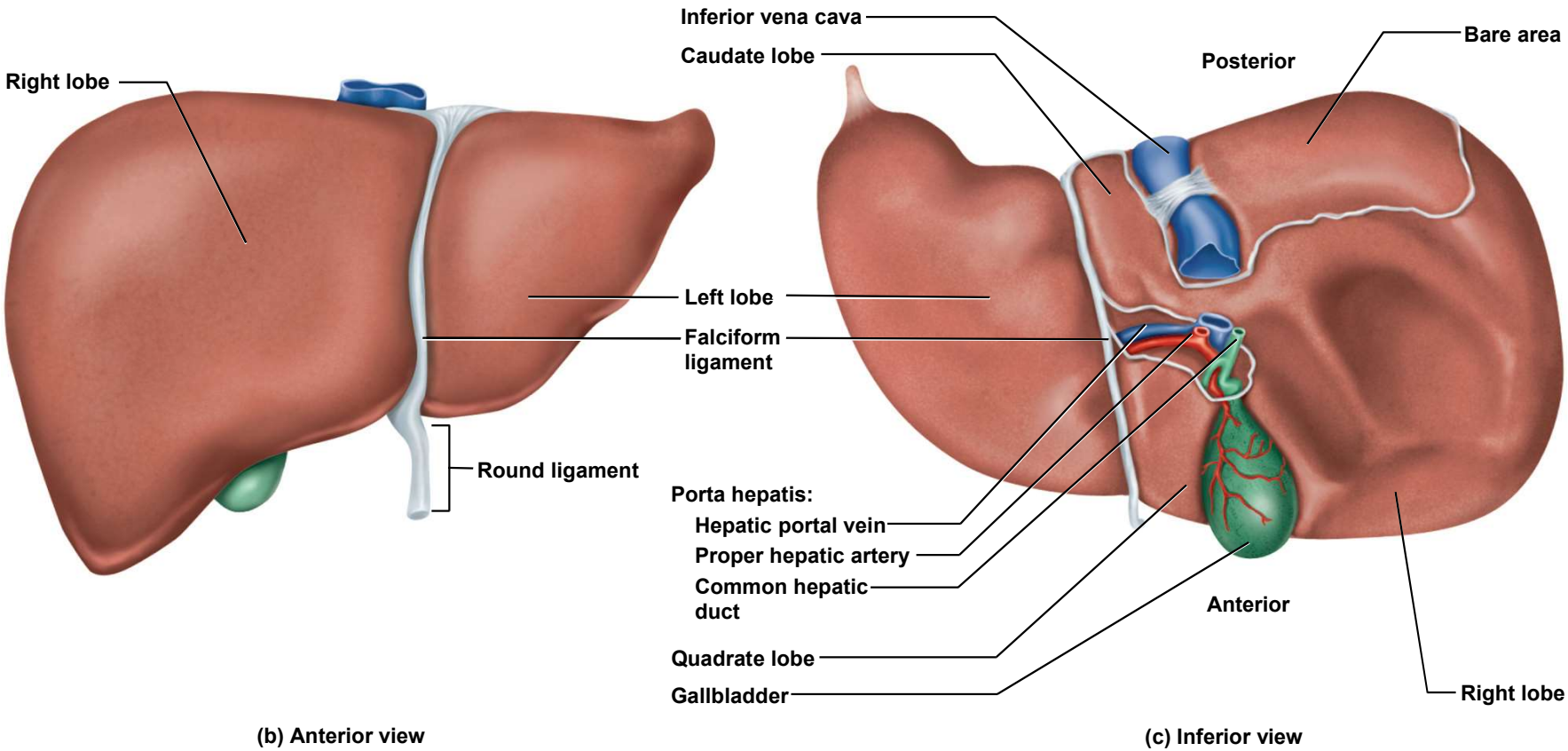

(b) Anterior view

(c) Inferior view

Microscopic Anatomy of Liver

- **Hepatic lobules** – tiny innumerable cylinders that fill the interior of the liver
  - about 2 mm long and 1 mm in diameter
  - consists of:
    - **central vein** – passing down the core
    - **hepatocytes** – cuboidal cells surrounding central vein in radiating sheets or plates /// each plate of hepatocytes is an epithelium one or two cells thick

Microscopic Anatomy of Liver

- **hepatic sinusoids** – blood-filled channels that fill spaces between the plate
  - lined by a **fenestrated endothelium** that separates hepatocytes from blood cells
  - allows plasma into the space between the hepatocytes and endothelium
  - hepatocytes have **brush border of microvilli** that project into this space
  - blood filtered through the sinusoids comes directly from the stomach and intestines
- **hepatic macrophages (Kupffer cells)** – phagocytic cells in the sinusoids that remove bacteria and debris from the blood

Functions of Hepatocytes

- After a meal, the hepatocytes absorb nutrients from the blood /// glucose, amino acids, iron, vitamins, and other nutrients for metabolism or storage (eg glycogen)
- Removes and degrades /// hormones, toxins, bile pigments, and drugs /// many macrophage in liver
- Secretes into the blood /// albumin, lipoproteins, clotting factors, activates angiotensin, complement proteins, and other products
- In between meals, hepatocytes breaks down stored glycogen and releases glucose into the blood
- Produces bile / bile transported to and stored in gall bladder
- Hepatocytes also able to preform gluconeogenisis and lipogenisis

Microscopic Anatomy of Liver

- **Hepatic lobules** are separated by a sparse connective tissue stroma
- **Hepatic triad** = **two vessels** and a **bile ductule** /// visible in the triangular areas where three or more lobules meet
  - branches of **proper hepatic artery and hepatic portal vein**
    - **both supply blood to sinusoids** which receive a mixture of nutrient-laden venous blood from the intestines, and freshly oxygenated arterial blood from the celiac trunk
    - after filtering through the sinusoids, the blood is collected in the **central vein**
    - ultimately flows into **the right and left hepatic veins**
    - leave the liver at its superior surface and immediately drain into the **inferior vena cava**

Microscopic Anatomy of Liver

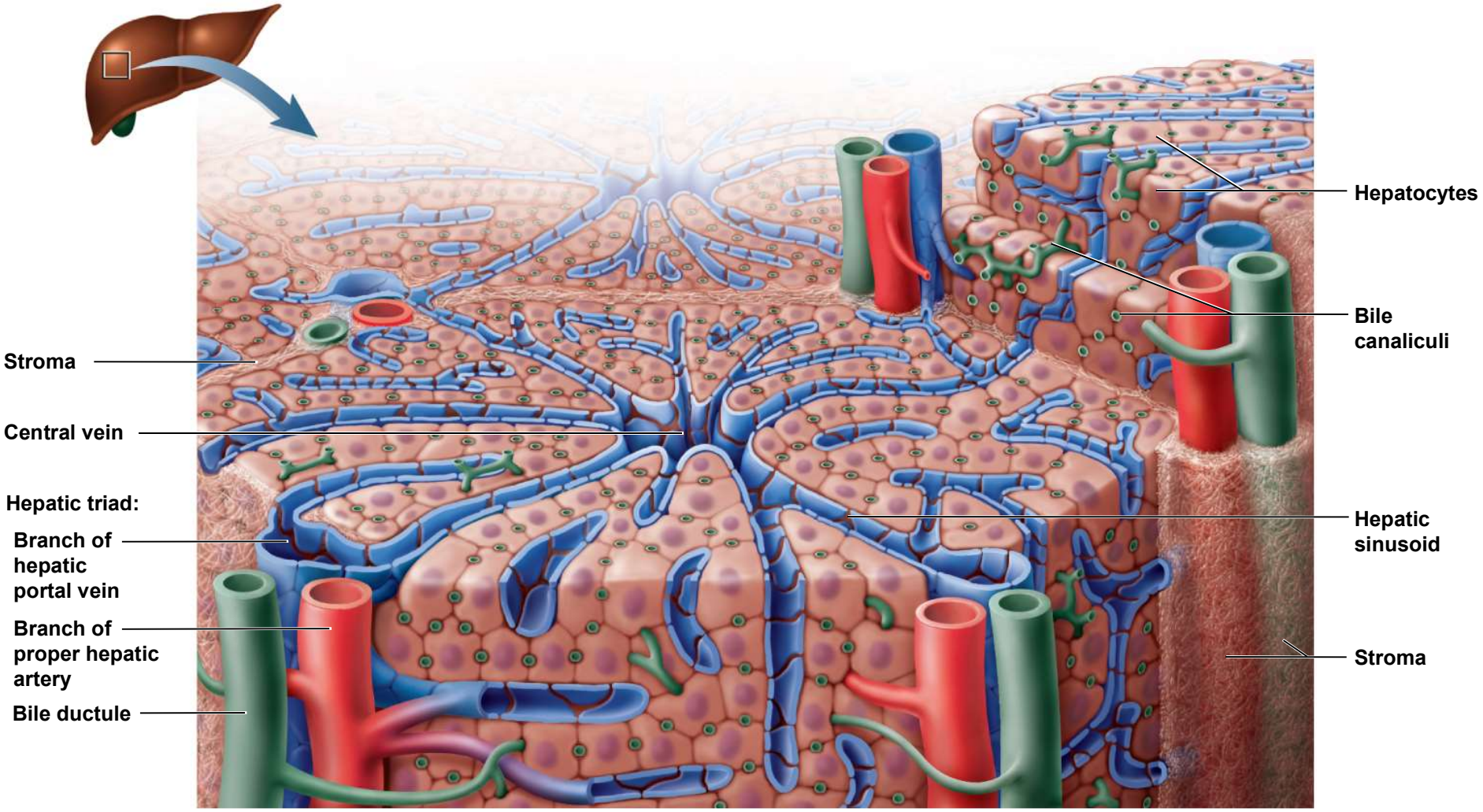

(a)

Histology of Liver - Hepatic Triad

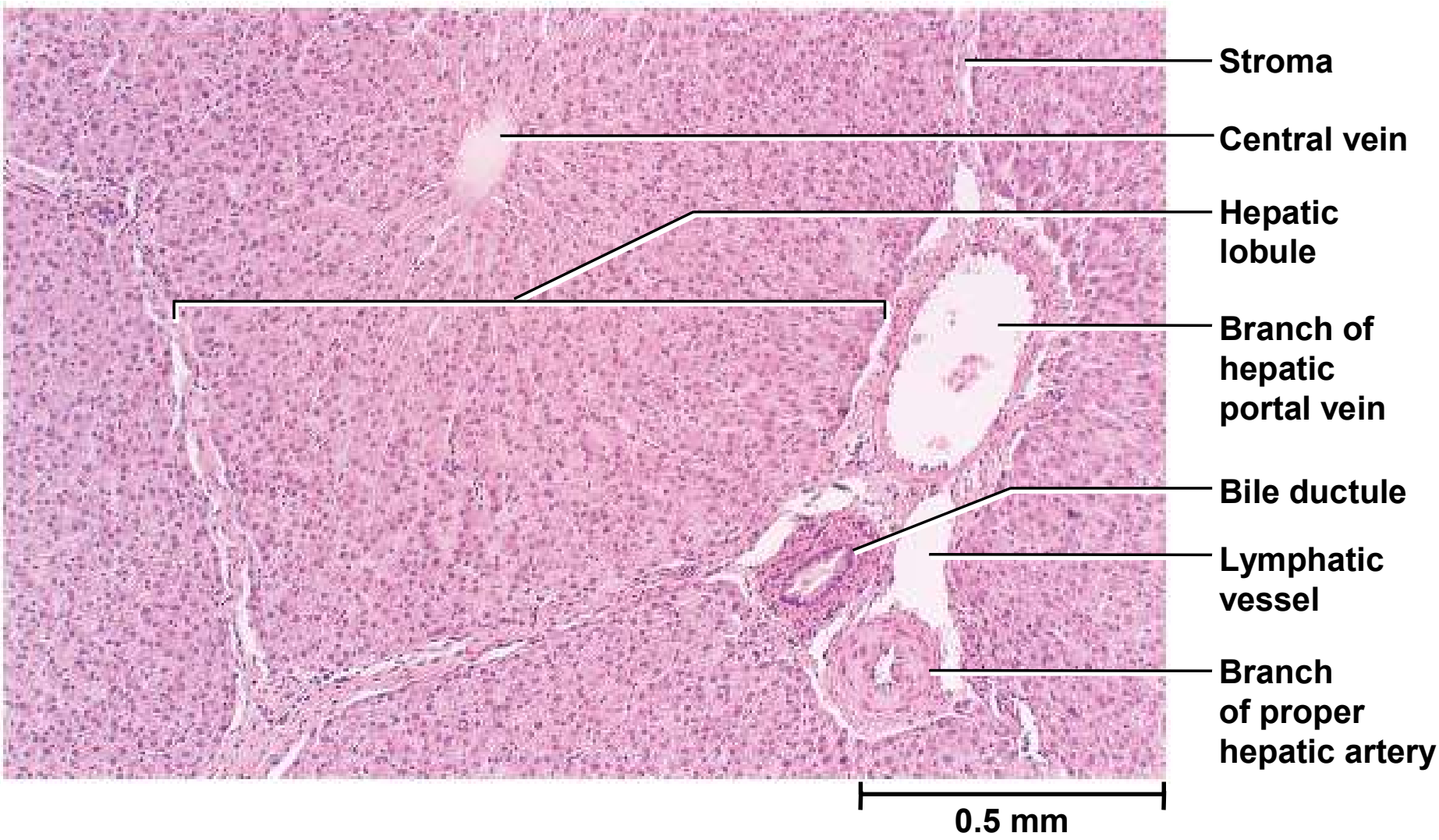

Microscopic Anatomy of Liver

- **Bile canaliculi** – narrow channels into which the liver secretes bile
  - bile passes into bile **ductules** of the triads
  - ultimately into the **right and left hepatic ducts**
  - **common hepatic duct** – formed from convergence of right and left hepatic ducts on inferior side of the liver
  - **cystic duct** coming from gall bladder joins common hepatic duct

Bile Duct and the Liver

- bile duct - formed from union of cystic and common hepatic ducts // descends through lesser omentum toward the duodenum
- near duodenum, bile duct joins the duct of the pancreas
- forms expanded chamber – hepatopancreatic ampulla // terminates in a fold of tissue – major duodenal papilla on duodenal wall // Accessory pancreatic duct – minor duodenal papilla
- major duodenal papilla contains muscular hepatopancreatic sphincter (sphincter of Oddi)
    - regulates passage of bile and pancreatic juice into duodenum
    - between meals, sphincter closes and prevents release of bile into the intestines

Liver, Gallbladder, and Pancreas

- Small intestine receives chyme from the stomach
- As chyme enters duodenum, secretions from liver and pancreas added to the chyme
  - enter digestive tract near the junction of stomach and small intestine
  - secretions from liver and pancreas are important to the digestive process of the small intestine

Gallbladder

- **Gallbladder** – a pear-shaped sac on underside of liver
  - serves to **store and concentrate bile** by a factor of 20 by absorbing water and electrolytes
  - about 10 cm long
  - internally lined by highly folded mucosa with **simple columnar epithelium**
  - **head (fundus)** usually projects slightly beyond inferior margin of liver
  - **neck (cervix)** leads into the **cystic duct**

Gross Anatomy of the Gallbladder, Pancreas, and Bile Passages

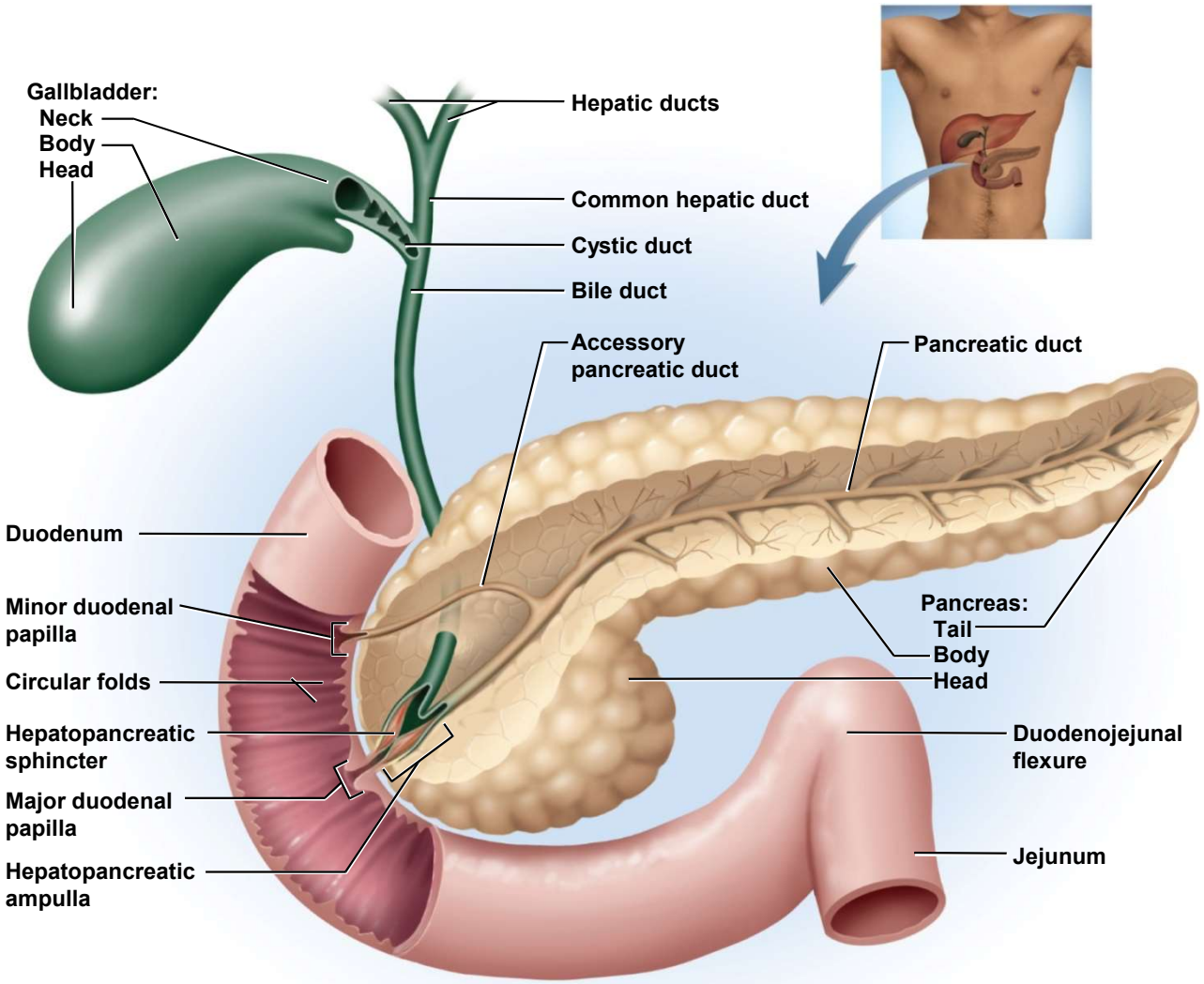

Secretion of bile.

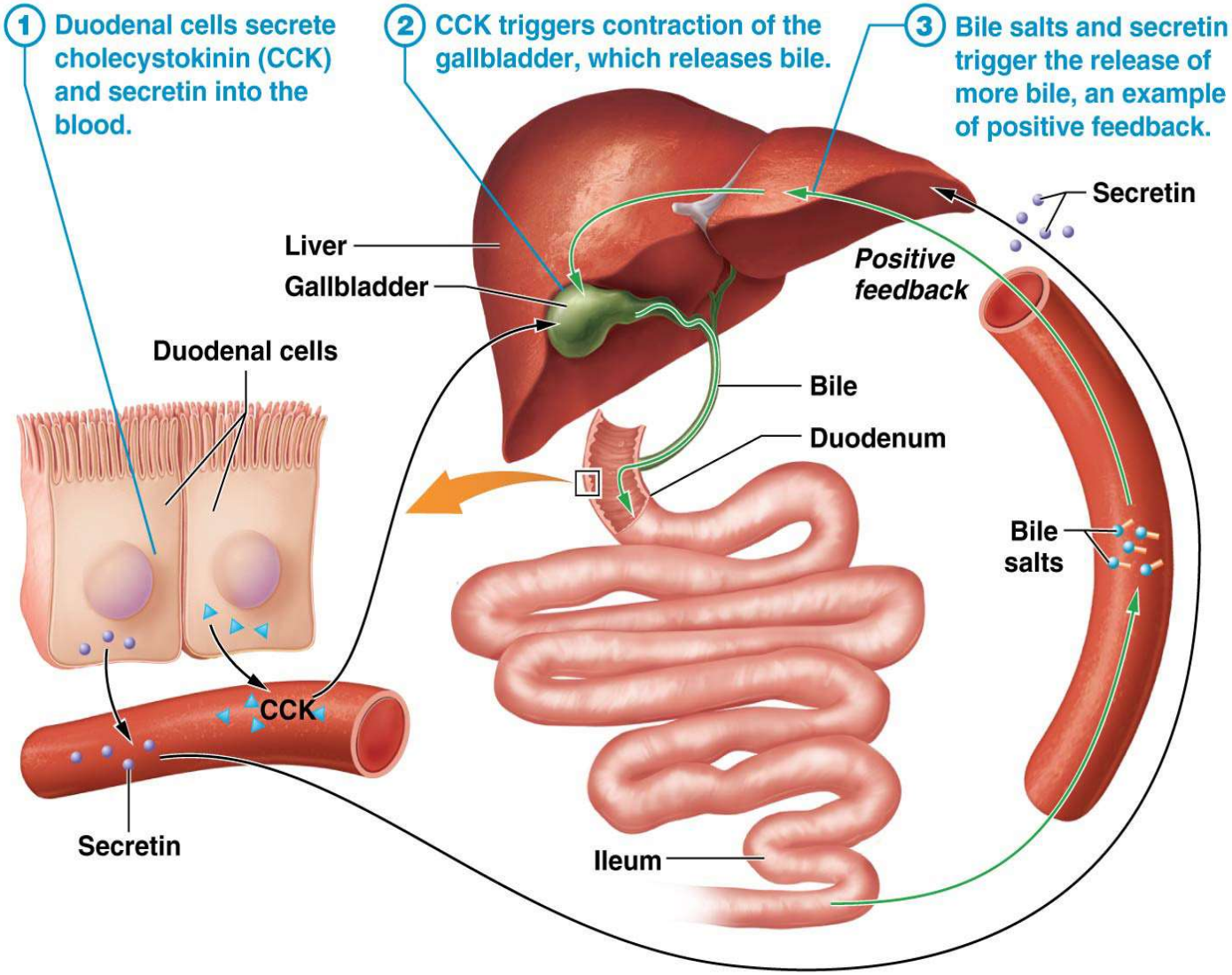

Note: Secretin also stimulate cells lining pancreatic ducts and bile duct to secrete bicarbonae. Why?

The Pancreas

- Spongy retroperitoneal gland posterior to the greater curvature of the stomach
  - measure 12 to 15 cm long, and 2.5 cm thick
  - has head encircled by duodenum, body, midportion, and a tail on the left
  - both an endocrine and exocrine gland
    - endocrine portion – pancreatic islets that secrete insulin and glucagon
    - exocrine portion – 99% of pancreas that secretes 1200 to 1500 mL of pancreatic juice per day /// secretory acini release their secretion into small ducts that converge on the main pancreatic duct

The Pancreas

- **Pancreatic duct** runs lengthwise through the middle of the gland
  - joins the bile duct at the **hepatopancreatic ampulla**
  - **hepatopancreatic sphincter** controls release of both bile and pancreatic juice into the duodenum
- **Accessory pancreatic duct**
  - smaller duct that branches from the main pancreatic duct
  - opens independently into the duodenum
  - **bypasses the sphincter** and allows <u>pancreatic juice to be released into the duodenum even when bile is not</u>

The Pancreas

- **Pancreatic juice** – alkaline mixture of water, enzymes, zymogens, sodium bicarbonate, and other electrolytes
  - acini secrete the enzymes and zymogens
  - **ducts** secrete bicarbonate /// required in order to **buffer HCl** from the stomach

Pancreatic Acinar Cells

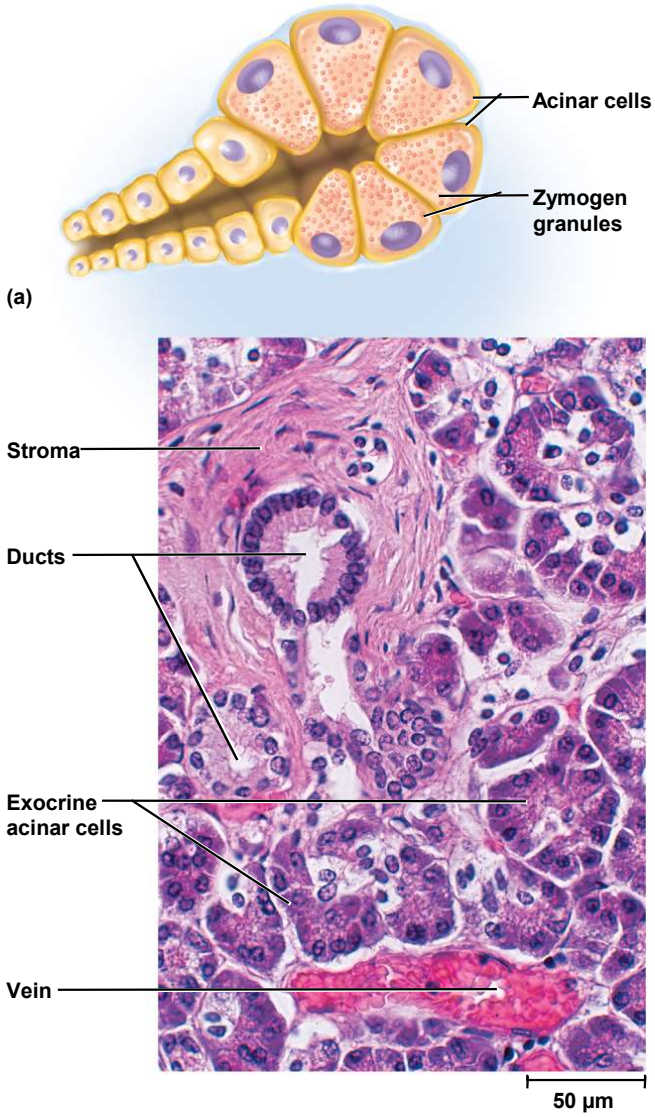

Pancreatic Proteolytic Zymogens

- Trypsinogen
  - secreted into intestinal lumen
  - converted to trypsin by enterokinase // this is a , brush boader enzyme of small intestine's mucosa
  - trypsin is autocatalytic – this means it converts trypsinogen into still more trypsin
  - trypsin = proteinolytic enzyme
- Chymotrypsinogen /// this is converted to trypsinogen by trypsin
- Procarboxypeptidase /// this is converted to carboxypeptidase by trypsin

Activation of Pancreatic Enzymes in the Small Intestine

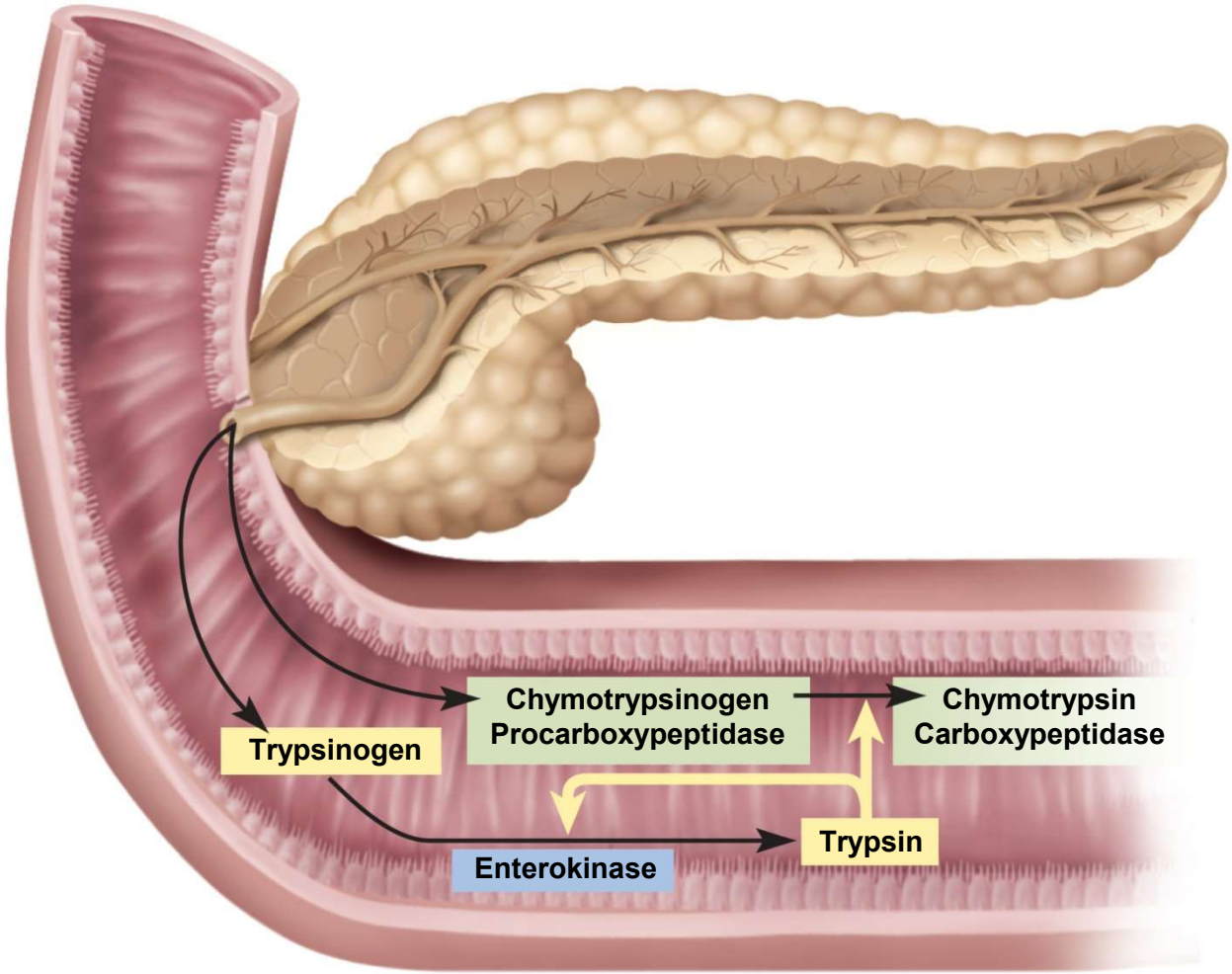

Other Pancreatic Enzymes

- **Pancreatic amylase** – digests starch
- **Pancreatic lipase** – digests fat
- **Ribonuclease** and **deoxyribonuclease** – digest RNA and DNA respectively

Regulation of Pancreatic & Gall Bladder Secretion (1 of 2)

- **Three stimuli** are chiefly responsible for the release of **pancreatic and bile secretions**
  - 1.) acetylcholine
  - 2. cholecystokinin
  - 3. secretin

- **Acetylcholine (ACh)** - from vagus nerves and enteric nerves
  - stimulates acini to secrete their enzymes during the cephalic phase of gastric control even before food is swallowed
  - enzymes remain in acini and ducts until chyme enters the duodenum

How Pancreatic & Gall Bladder Secretion Regulated (2 of 2)

- **Cholecystokinin (CCK) -** secreted by mucosa of duodenum in response to arrival of fats in small intestine
  - stimulate pancreatic acini cells to **secrete digestive enzymes**
  - strongly stimulates gall bladder to release bile
  - induces relaxation of hepatopancreatic sphincter that allows both bile and pancreatic digestive enzymes into the duodenum
- **Secretin -** released from duodenum in response to acidic chyme arriving from the stomach
  - stimulates ducts in both liver and pancreas **to secrete more sodium bicarbonate**
  - raising pH to level pancreatic and intestinal digestive enzymes require

Learning Objective #8

State the composition and functions of bile.

Bile

- Bile – yellow-green fluid containing minerals, cholesterol, neutral fats, phospholipids
  - Primary secretions are bile acids (also called salts) and bile pigments
  - liver secretes about 500 – 1000 ml of bile daily
  - bile gets to the gallbladder by first filling the bile duct but if hepatopancreatic papillae closed fluid fills gallbladder

Bile

Bile pigments

- **bilirubin** – principal pigment derived from the **decomposition of hemoglobin** /// bacteria in large intestine metabolize **bilirubin to urobilinogen** /// responsible for the **brown color of feces**

Bile acids (also called bile salts)

- steroids synthesized from cholesterol /// **gallstones** may form if bile becomes excessively concentrated
- **80% of bile acids are reabsorbed** in the ileum and returned to the liver /// hepatocytes absorb and resecrete them /// **enterohepatic circulation** – this route secretion, reabsorption, and resecretion of bile acids two or more times during digestion of an average meal
- **20% of the bile acids are excreted in the feces** /// this is the body's only way of eliminating excess cholesterol /// liver synthesizes new bile acids from cholesterol to replace those lost in feces
- Another fat molecule associated with the bile acids is **lecithin**, a phospholipid that helps in fat digestion and absorption

Emulsification
Action of Bile Acids and Lethin

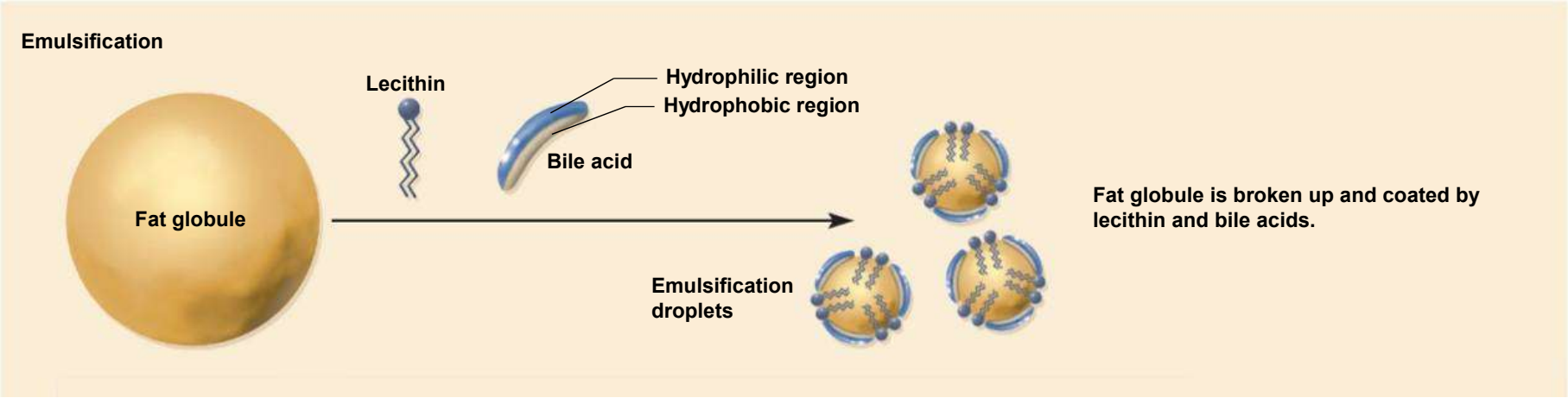

Learning Objective #9

Describe the problem caused by the obstruction of the opening of the pancreatic duct in the duodenum.

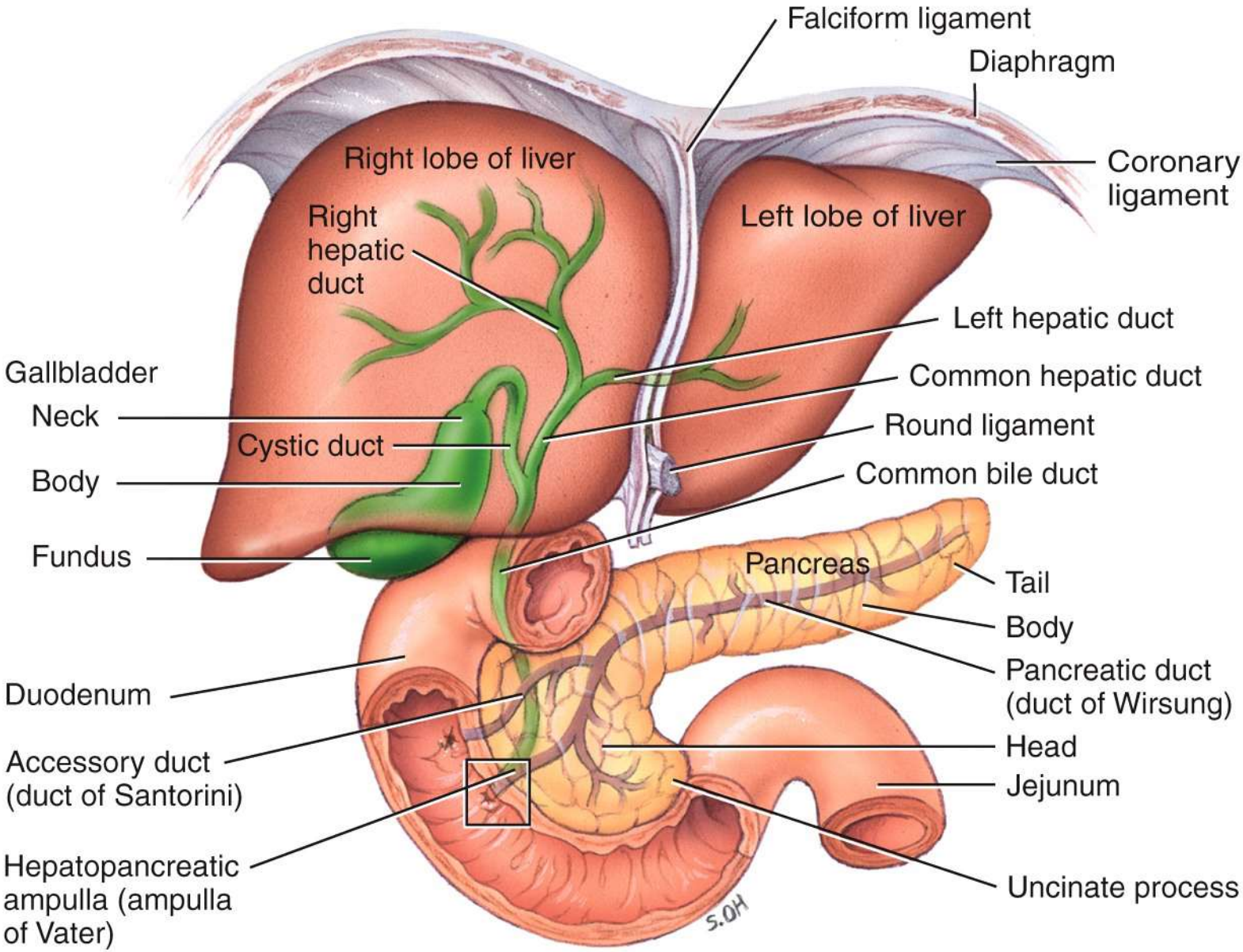

(a) Anterior view

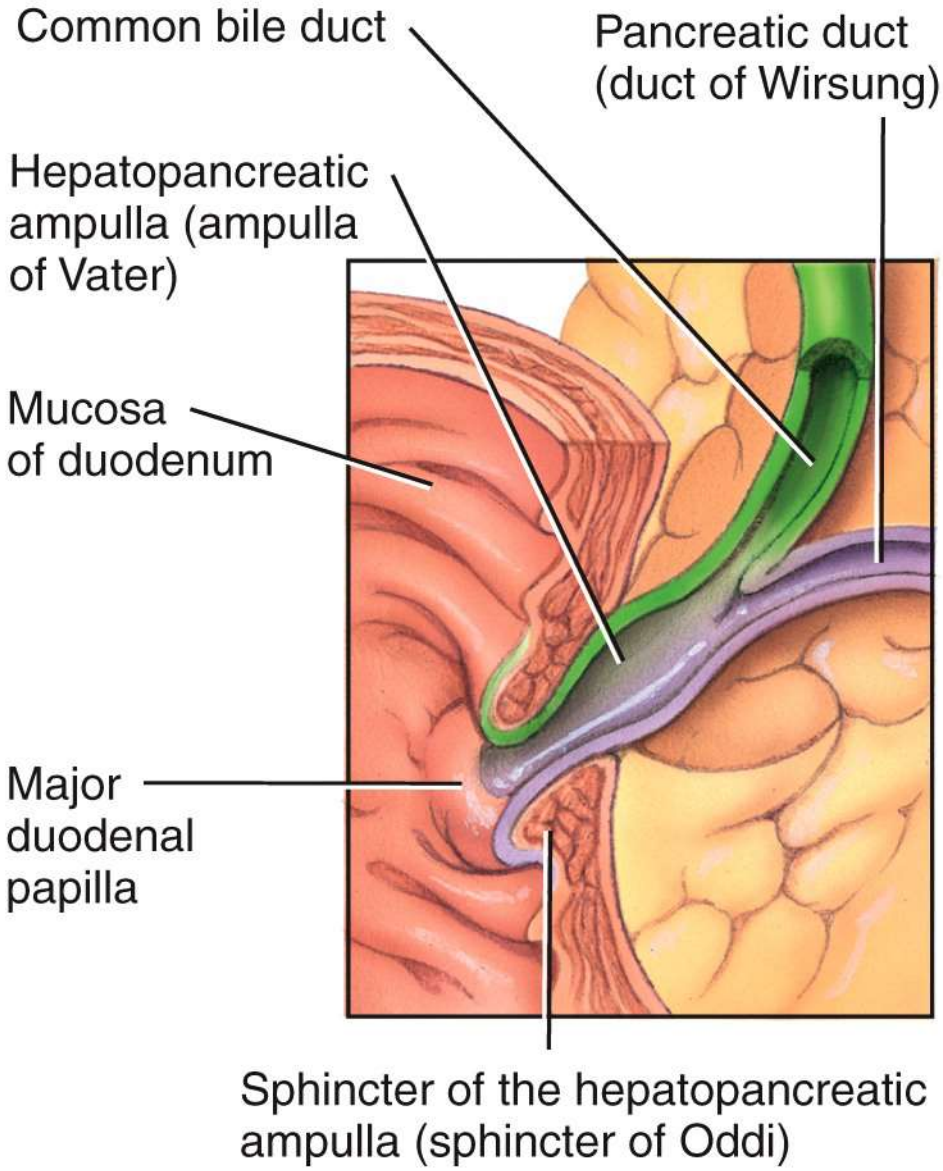

(b) Details of hepatopancreatic ampulla

Gallstones

- **gallstones (biliary calculi)** - hard masses develop in either the gallbladder or bile ducts
  - composed of cholesterol, calcium carbonate, and bilirubin
  - gallstones cause obstruction within ducts // very painful // prevents essential molecules for proper fat metabolism from reaching the duodenum
  - cause jaundice - yellowing of skin and sclera due to bile pigment accumulation, poor fat digestion, and impaired absorption of fat-soluble vitamins
- **lithotripsy** - use of ultrasonic vibration to pulverize stones without surgery
- **cholelithiasis** - formation of gallstones /// most common in obese women over 40 due to excess cholesterol

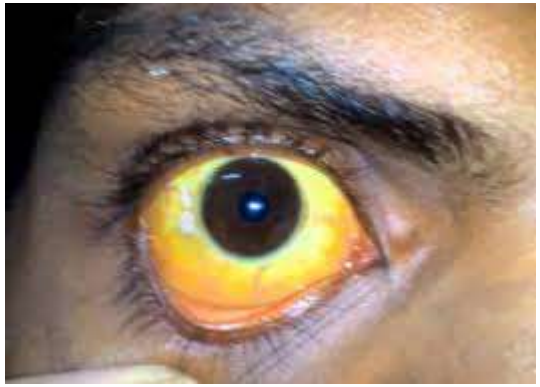


2004: Overweight, Multiple Health Issues
2006: Jaundice From Liver Disease
2014: 100% RECOVERED AND HEALTHY!

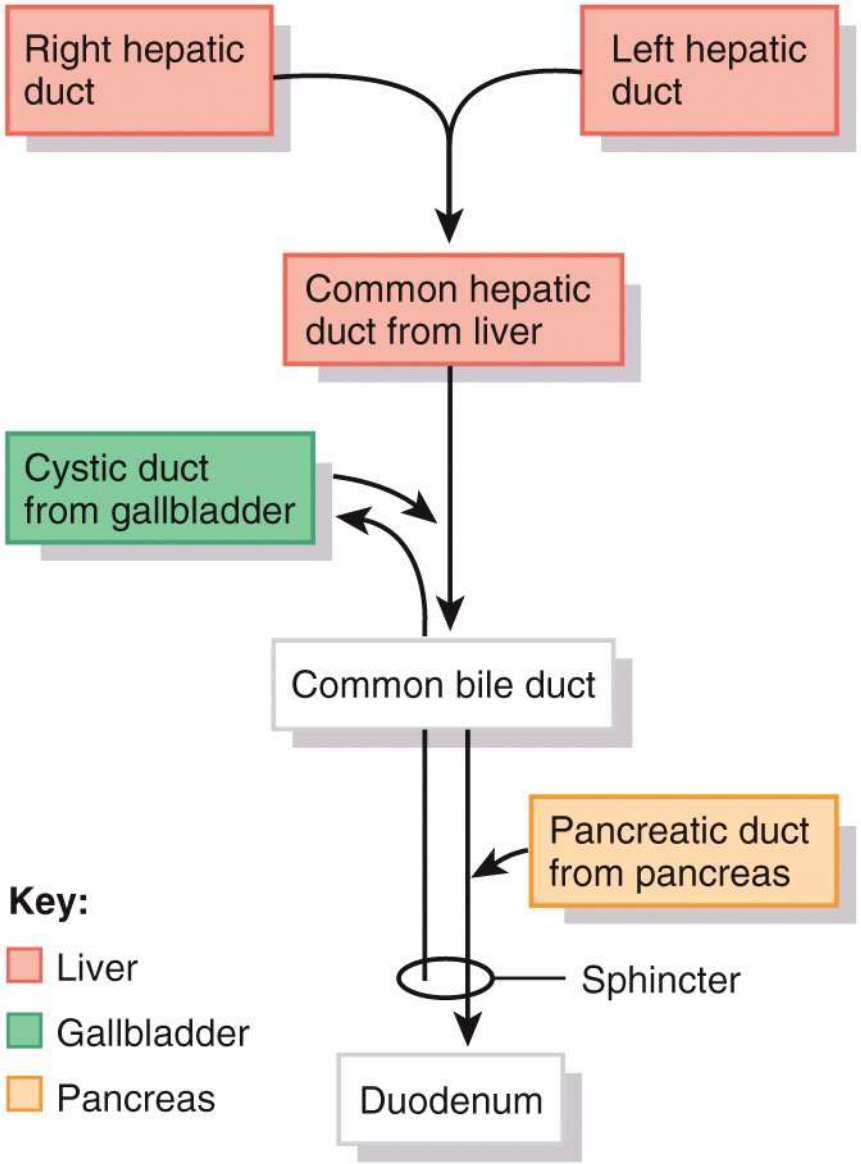

(c) Ducts carrying bile from liver and gallbladder and pancreatic juice from pancreas to the duodenum

Gross Anatomy of the Gallbladder, Pancreas, and Bile Passages

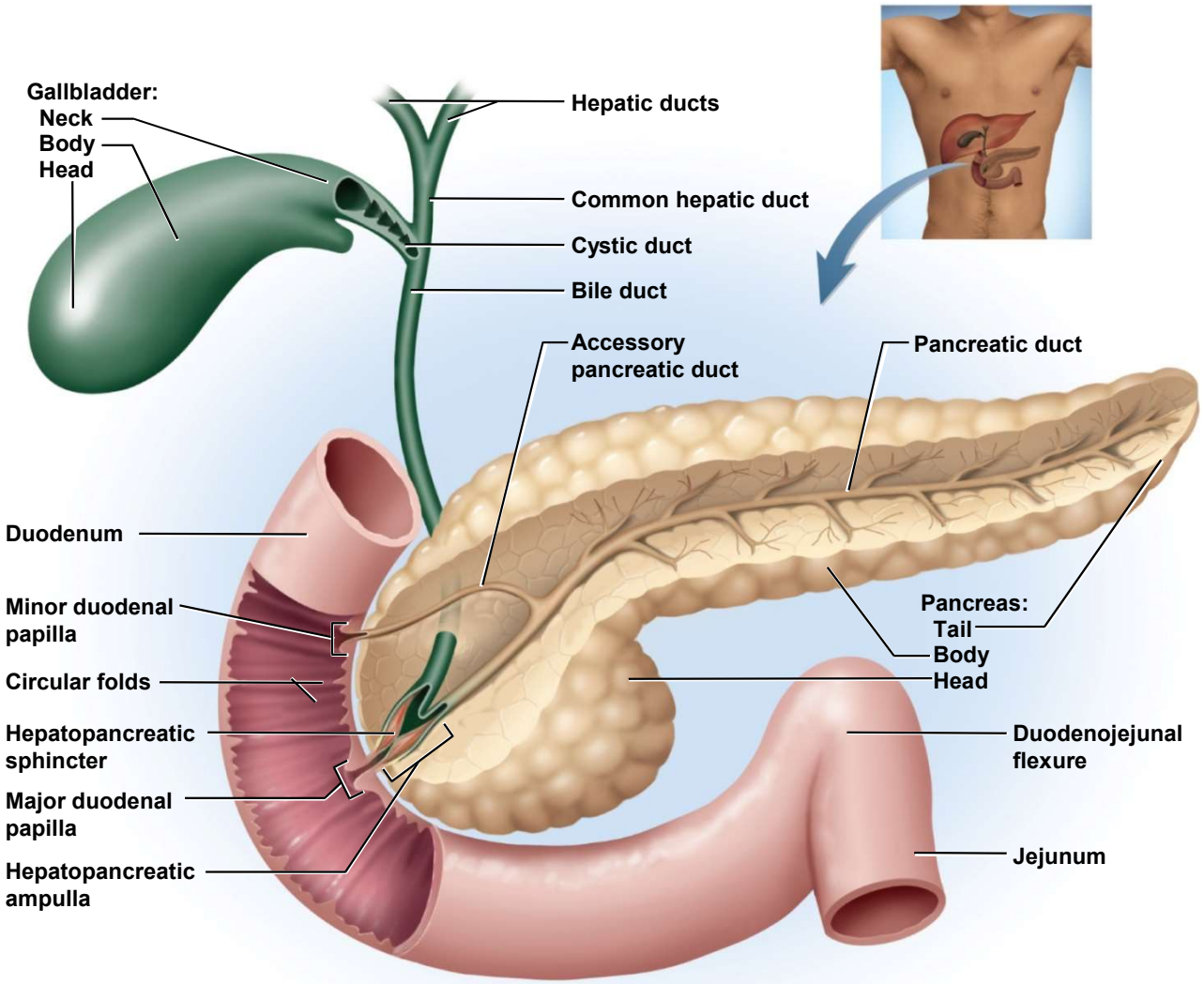

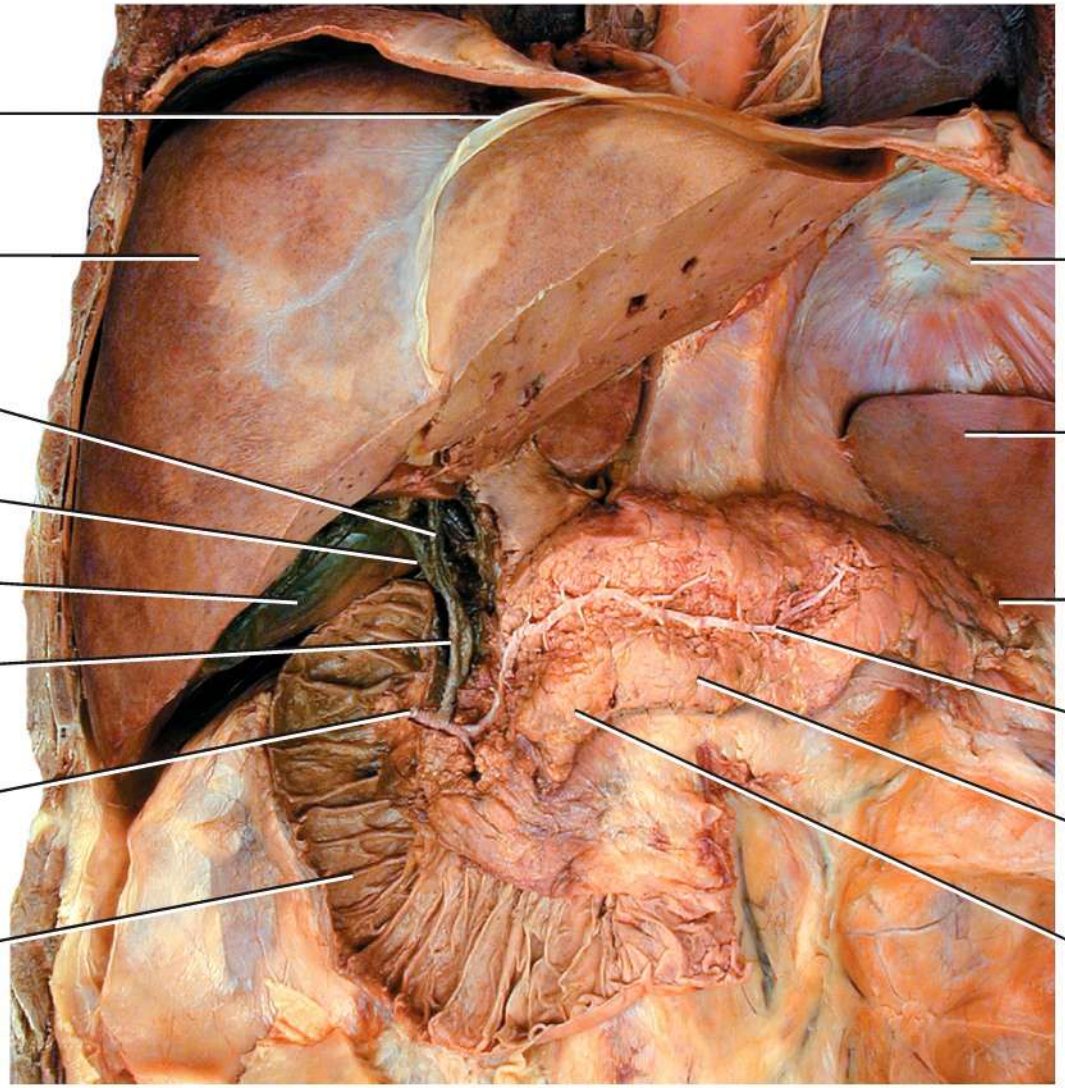

Dissection Shawn Miller, Photograph Mark Nielsen

(d) Anterior view