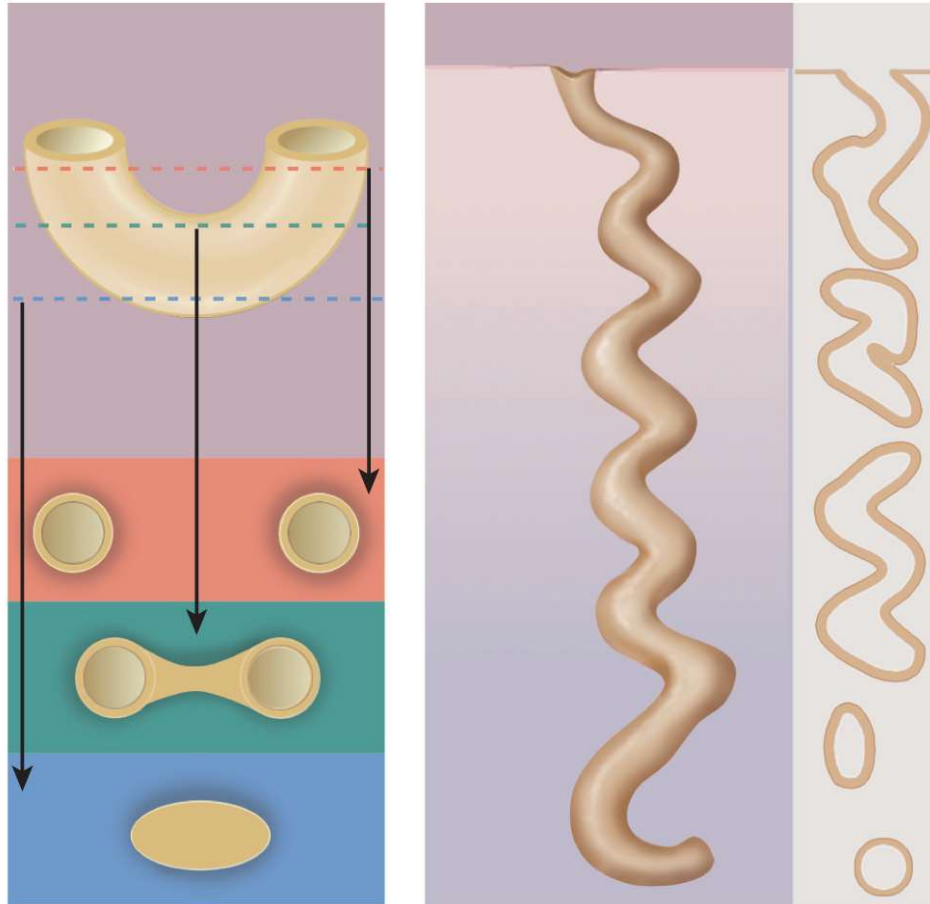


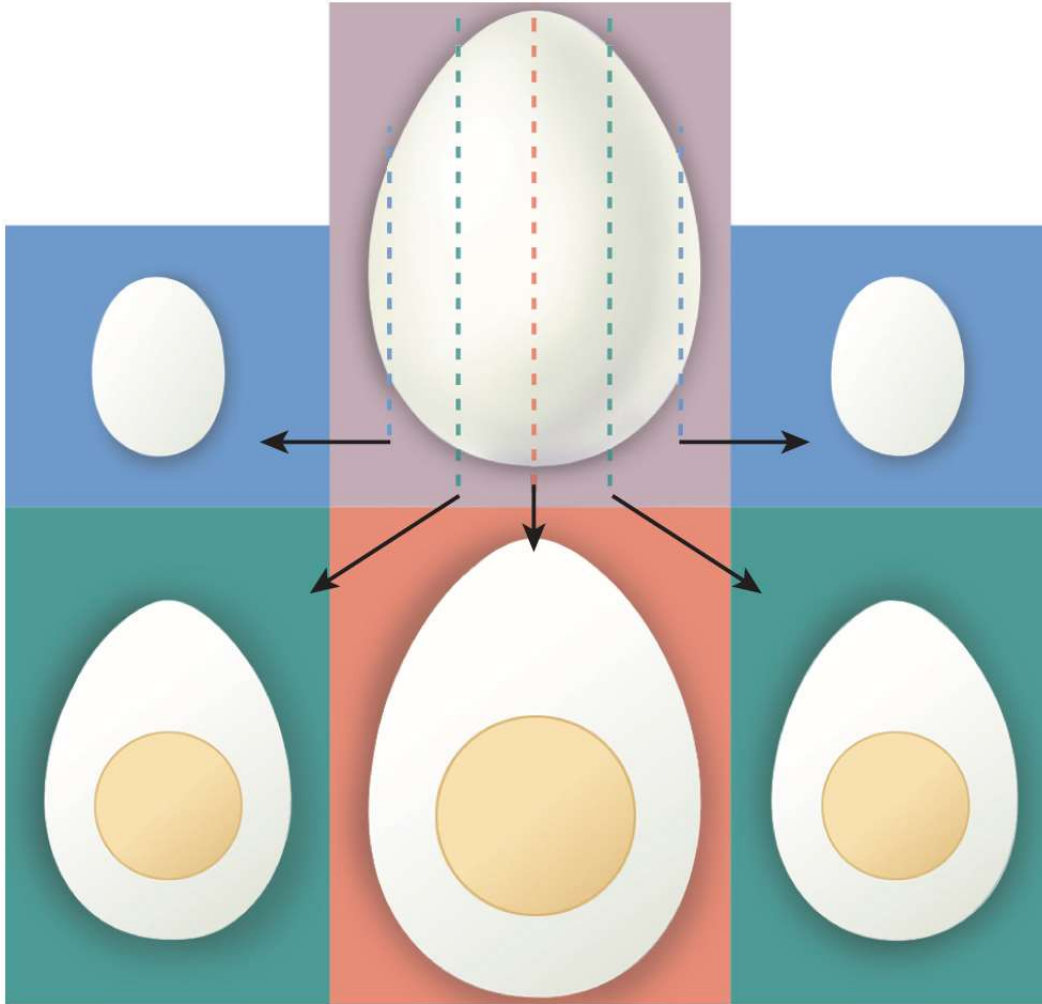
How to Interpret Tissue Sections Using a Microscope



Interpreting Tissue Sections

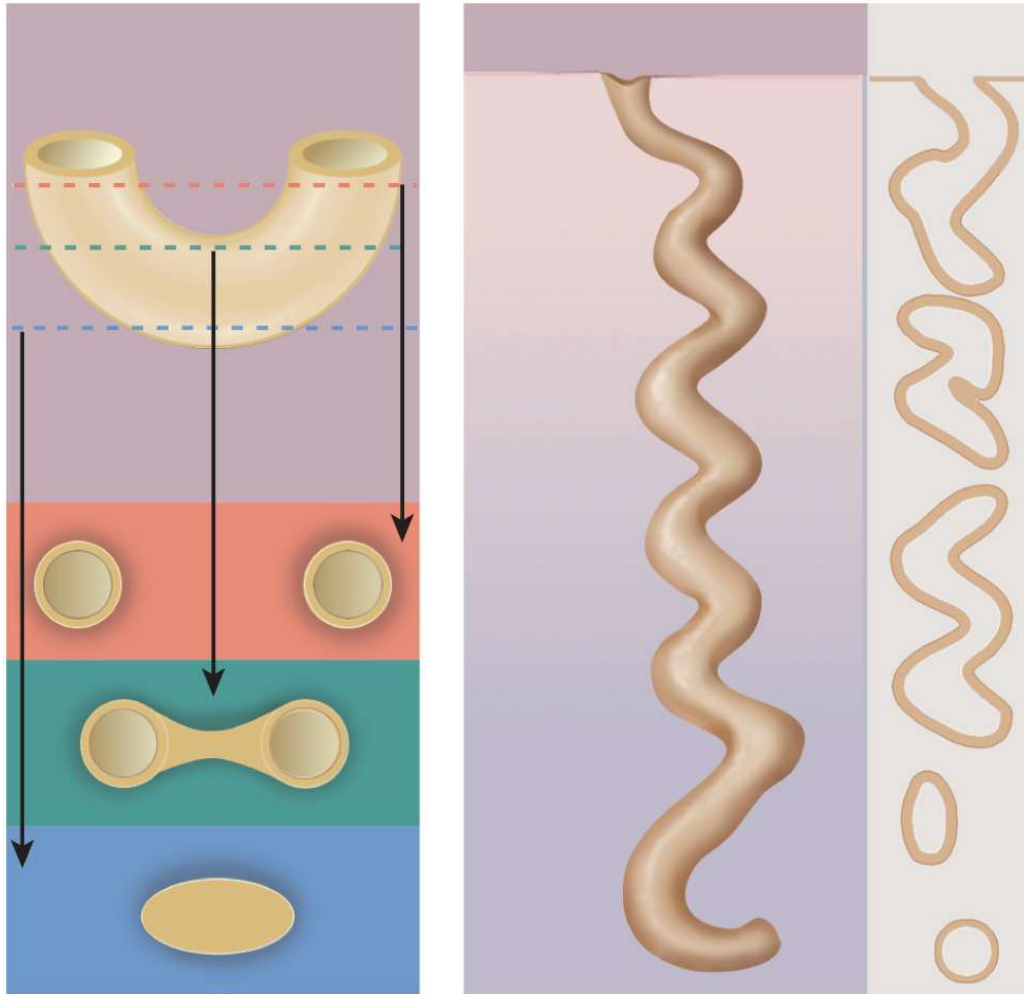
- Microscopic sectioning converts a **three-dimensional structure into a two-dimensional slice**
- Preparation of histological specimens
 - fixative prevents decay (e.g. formalin)
 - histological sections – tissue is sliced into thin sections one or two cells thick
 - stains – tissue is mounted on slides and artificially colored with histological stain - increases contrast // stains bind to different cellular components and increases contrast

Sectioning Solid Objects



- sectioning a cell with a centrally located nucleus
- some slices miss the cell nucleus
- in some sections the nucleus looks smaller than other sections

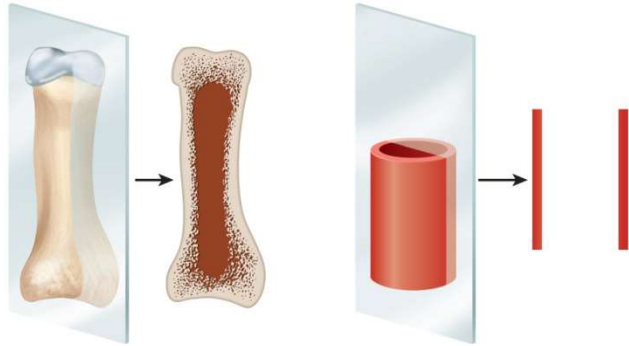
Sectioning Hollow Structures



- **cross section** of blood vessel, gut, or other tubular organ.
- **longitudinal section** of a sweat gland /// notice what a single slice could look like.

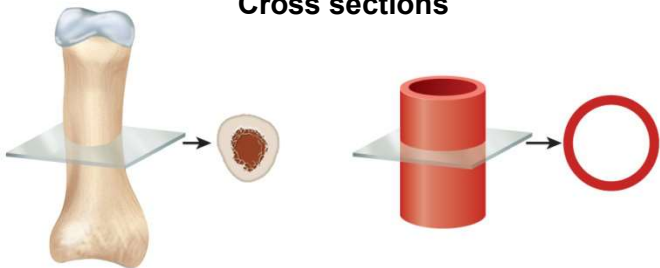
Types of Tissue Sections

Longitudinal sections



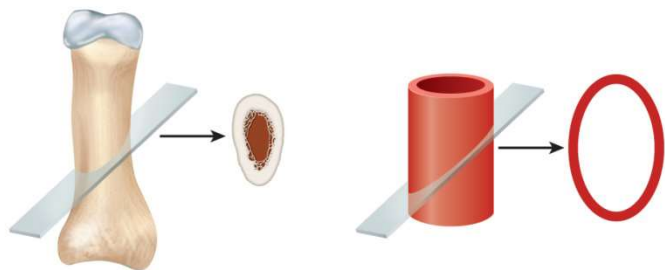
- **longitudinal section (l.s.)**
 - tissue cut along long direction of organ

Cross sections



- **cross section (c.s. or x.s.) or transverse section (t.s.)**
 - tissue cut perpendicular to length of organ

Oblique sections



- **oblique section**
 - tissue cut at angle between cross and longitudinal section

Non-sectioned Preparation

- **Smear** – tissue is rubbed or spread across the slide and often a cover slip is placed over the tissue sample /// E.g. blood smear to identify formed elements
- **Spread** – cobwebby tissue is laid out on a slide without cover slip /// E.g. areolar tissue