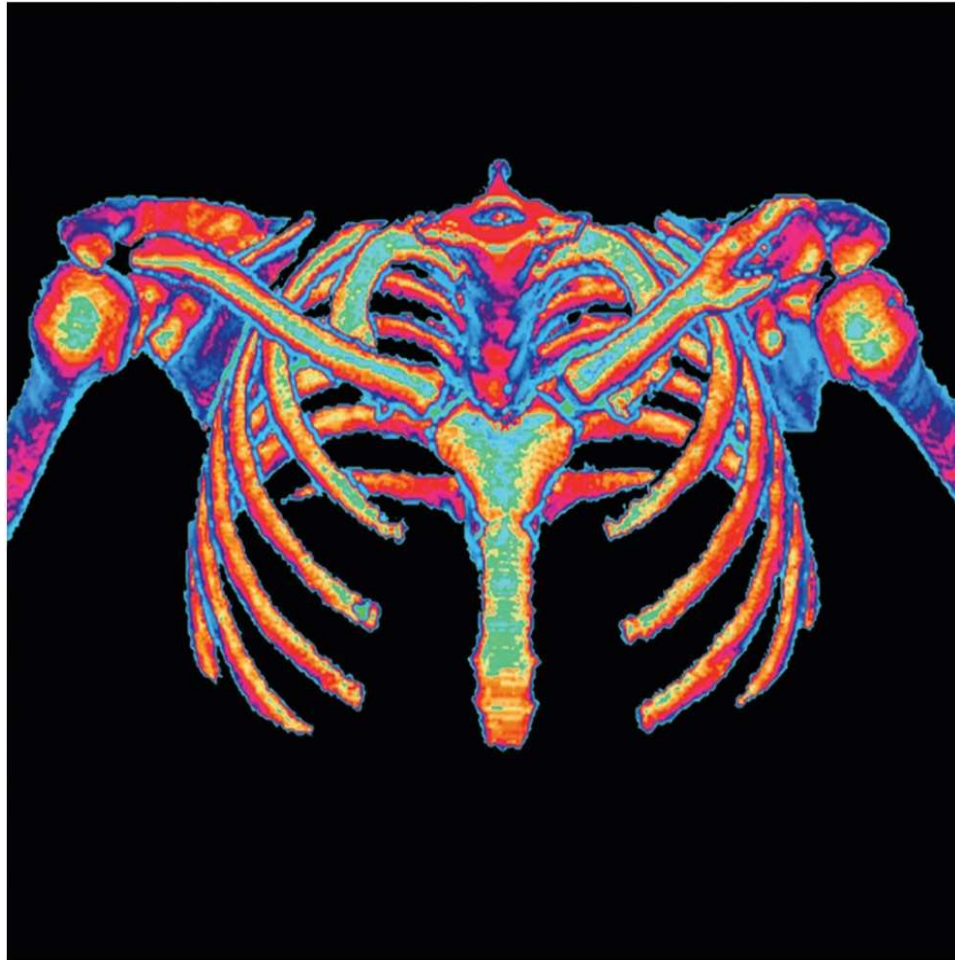


Chapter 8.5

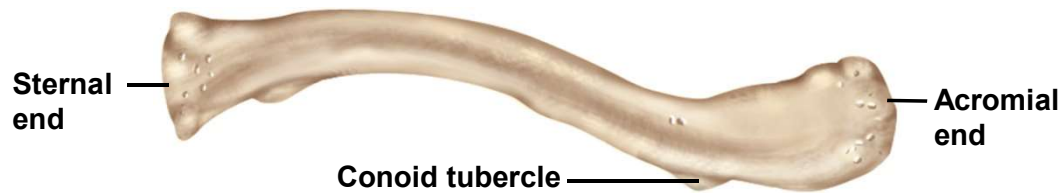
The Pectoral Girdle & Upper Limb



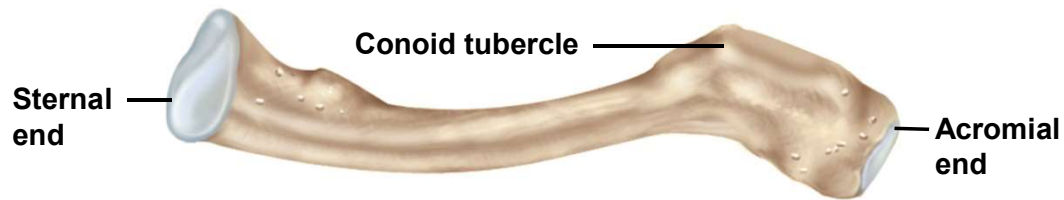
Pectoral Girdle

- pectoral girdle (shoulder girdle) – supports the arm
- consists of two bones on each side of the body // clavicle (collarbone) and scapula (shoulder blade)
- clavicle articulates medially to the sternum and laterally to the scapula
 - sternoclavicular joint
 - acromioclavicular joint
- scapula articulates with the humerus
 - glenohumeral joint - shoulder joint
 - easily dislocated due to loose attachment

Clavicle



(a) Superior view



(b) Inferior view

- clavicle - S-shaped, somewhat flattened bone
- inferior – grooves and ridges for muscle attachment
- sternal end - rounded head
- acromial end – flattened
 - conoid tubercle – roughened tuberosity near acromial end
 - ligament attachment
- braces the shoulder keeping upper limb away from the midline of the body
- most frequently fractured bone in the body

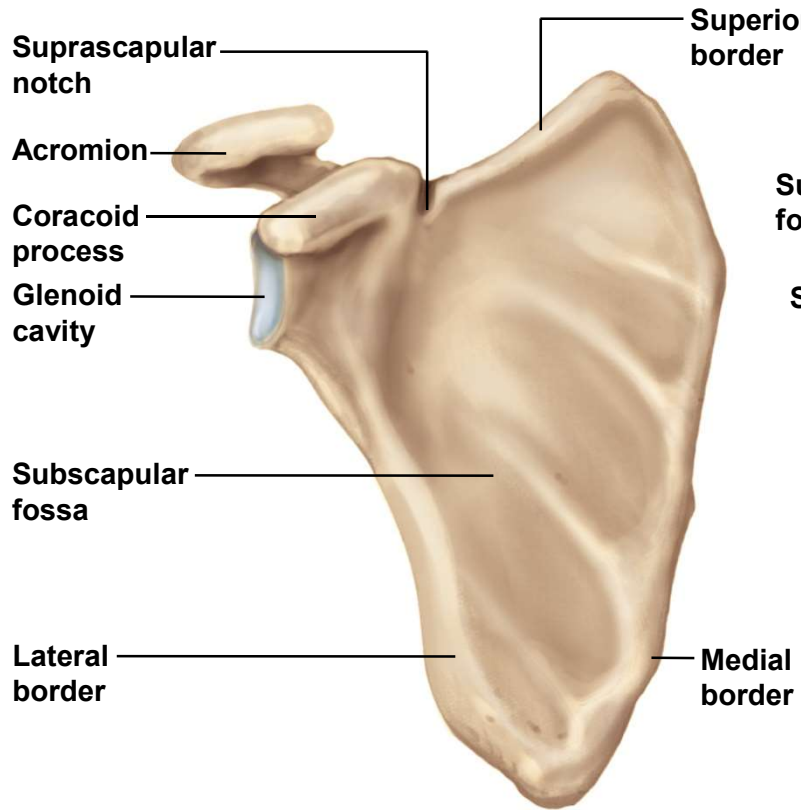
Scapula

- scapula – named for its resemblance to a spade or shovel
- triangular plate that posteriorly overlies ribs 2 to 7
 - three sides - superior, medial (vertebral) and lateral (axillary) borders
 - three angles – superior, inferior, and lateral angles
- suprascapular notch – conspicuous notch on superior border // provides passage for a nerve
- spine – transverse ridge on posterior surface
 - supraspinous fossa – indentation superior to the spine
 - infraspinous fossa – broad surface inferior to the spine

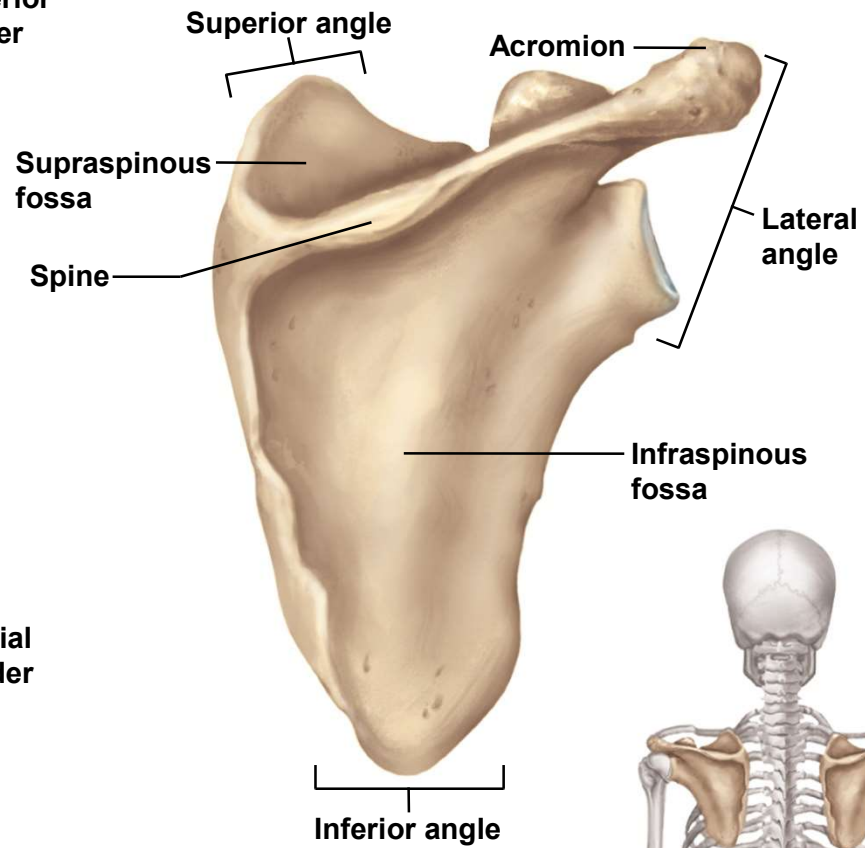
Scapula

- **subscapular fossa** – concave, anterior surface of scapula
- complex **lateral angle of scapula** has three main features:
 - **acromion** – platelike extension of the spine // forms apex of the shoulder // **articulates with the clavicle** – the sole point of attachment of the scapula and the upper limb to the rest of the skeleton
 - **coracoid process** – shaped like a bent finger // provides attachment for tendons of the biceps brachii and other arm muscles
 - **glenoid cavity** – shallow socket that articulates with the head of the humerus // forming **glenohumeral joint**

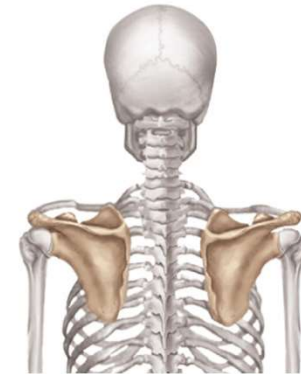Scapula



(a) Anterior view



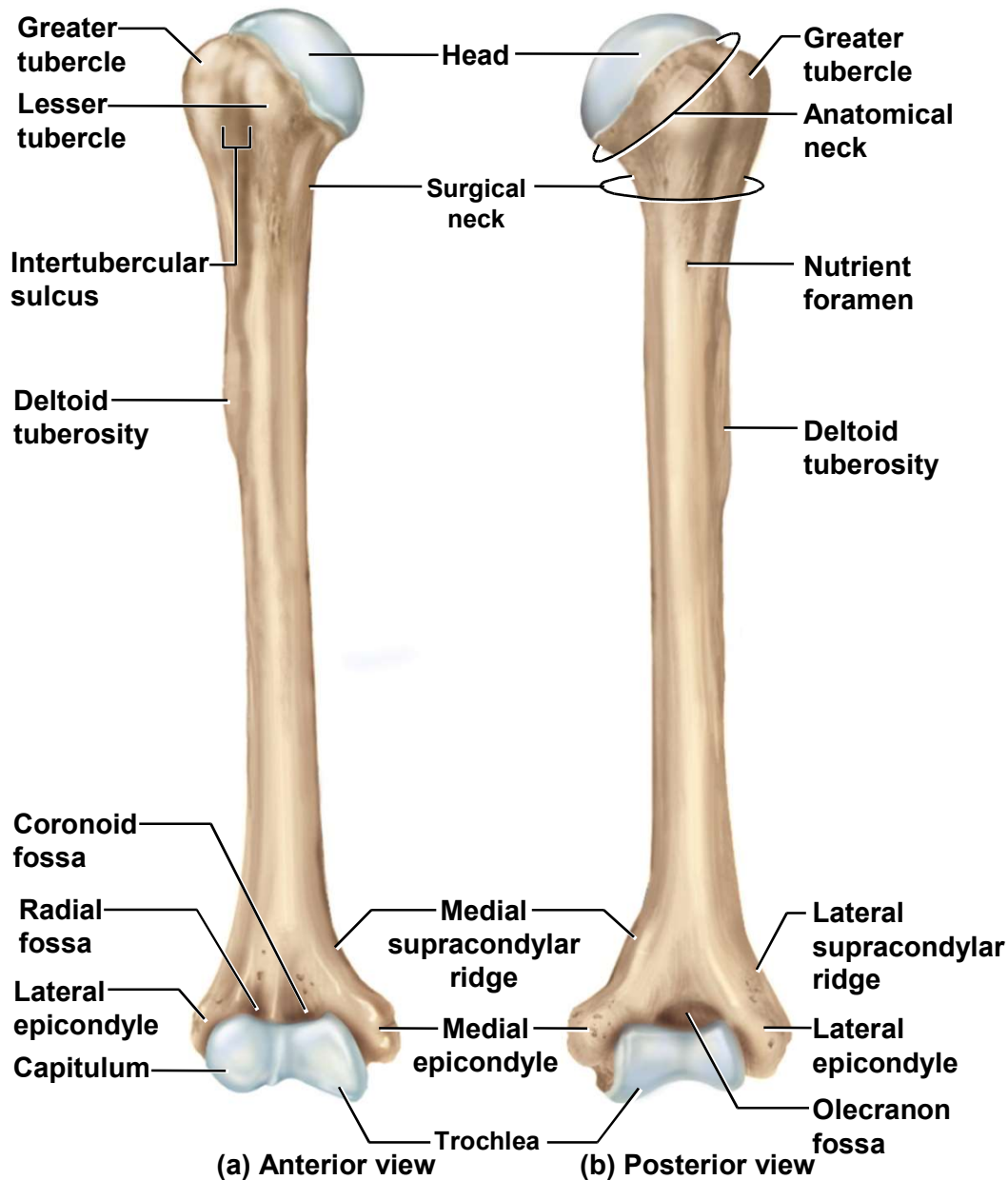
(b) Posterior view



Upper Limb

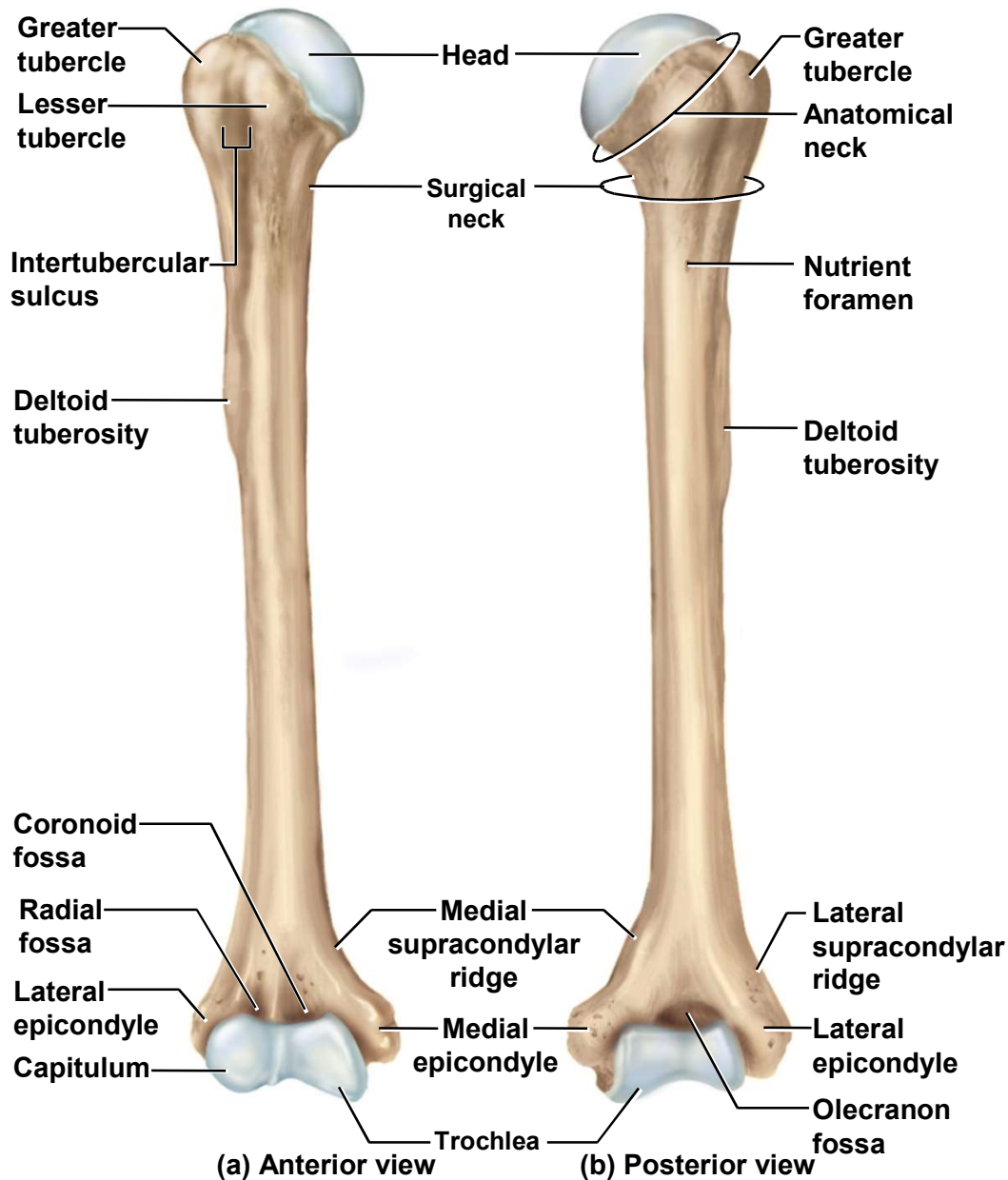
- upper limb is divided into four regions containing a total of 30 bones per limb
 - brachium (arm proper) – extends from shoulder to elbow // contains only one bone - humerus
 - antebrachium (forearm) – extends from elbow to wrist // contains two bones - radius and ulna
 - carpus (wrist) // contains 8 small bones arranged in 2 rows
 - manus (hand) // 19 bones in 2 groups
 - 5 metacarpals in palm // 14 phalanges in fingers

Humerus



- proximal end
 - hemispherical **head** that articulates with the **glenoid cavity** of scapula
 - **anatomical neck**
 - **greater and lesser tubercles** and deltoid tuberosity
 - **intertubercular sulcus** holds biceps tendon
 - **surgical neck**

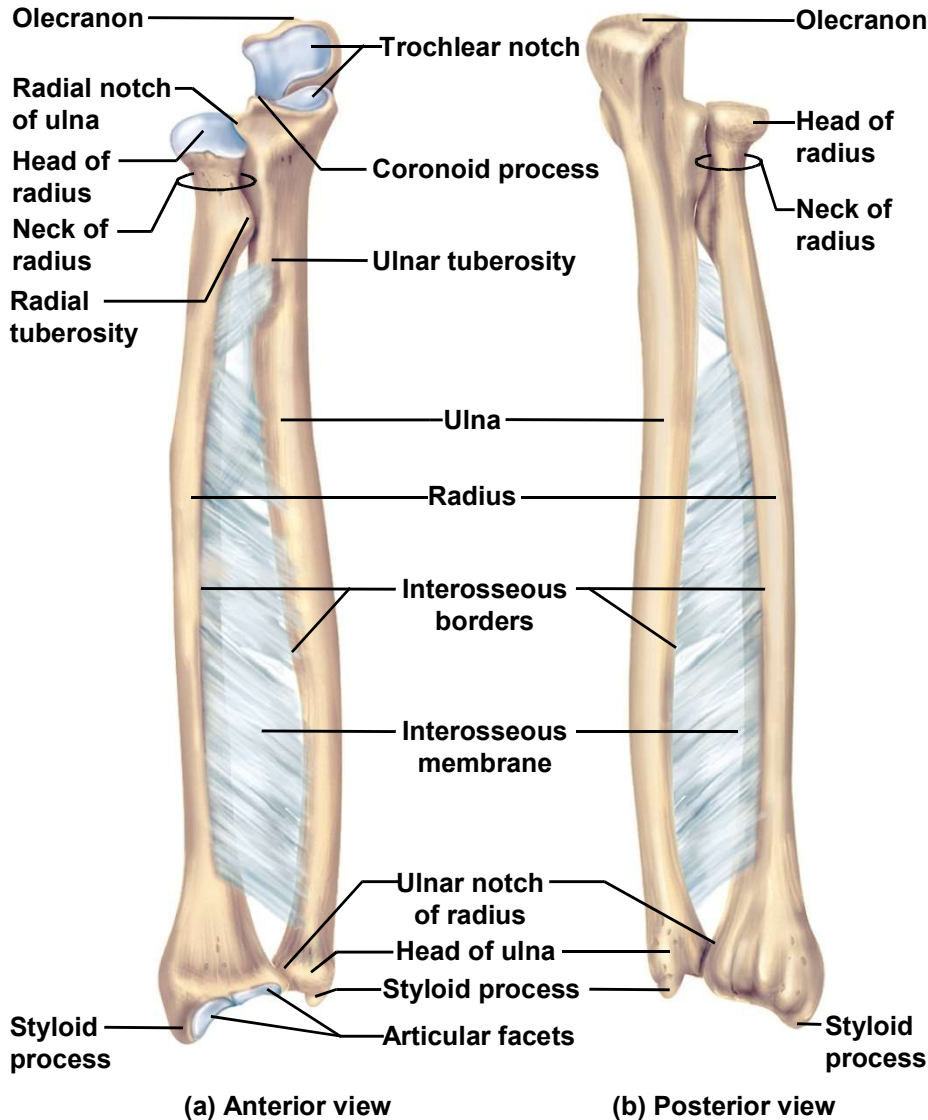
Humerus



- distal end
 - rounded capitulum articulates with head of radius
 - trochlea articulates with ulna
 - lateral and medial epicondyles
 - lateral and medial supracondylar ridges
 - olecranon fossa holds olecranon process of ulna
 - coronoid fossa //
 - radial fossa

Radius

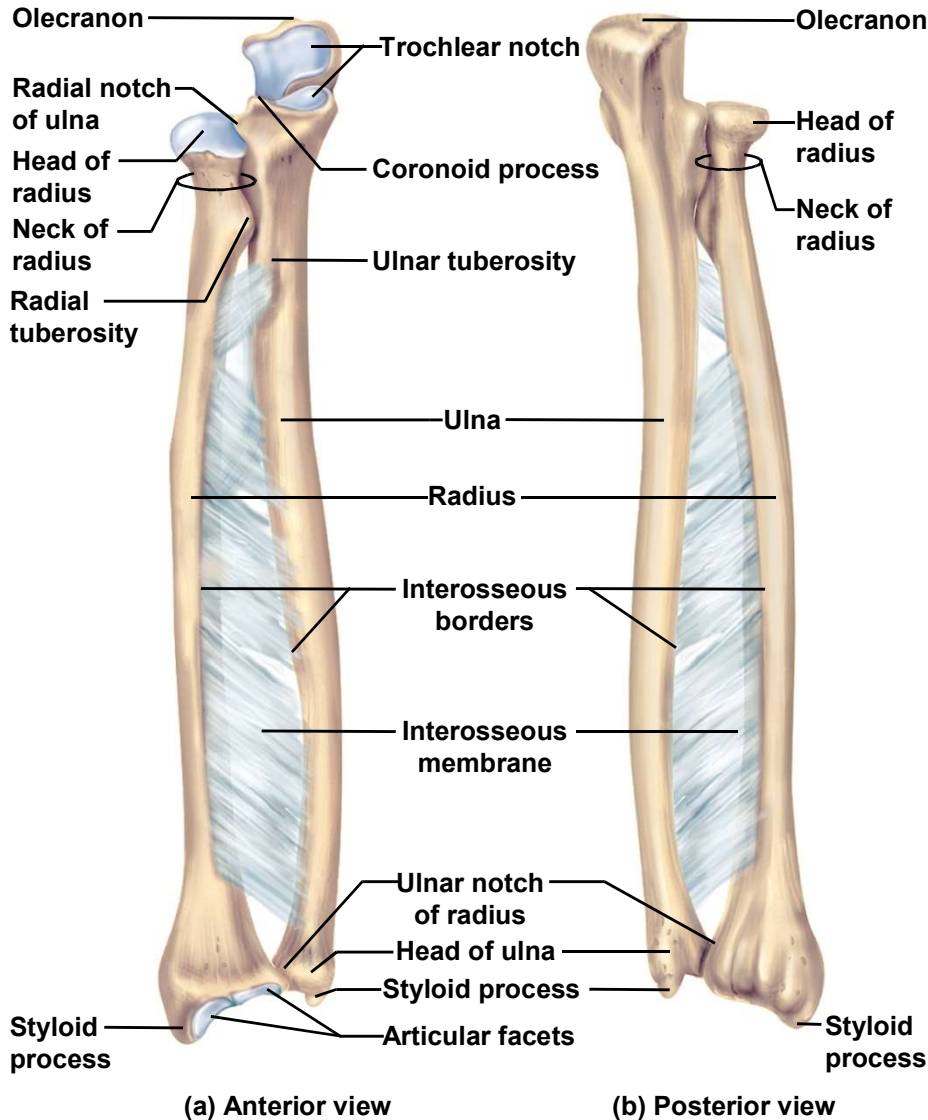
Copyright © The McGraw-Hill Companies, Inc. Permission required for reproduction or display.



- **head** – disc-shape, allows for rotation around the longitudinal axis of the bone during pronation and supination of hand
 - superior surface articulates with **capitulum** on humerus
 - side of disc spins on **radial notch** on ulna
- **Neck**
- **radial tuberosity** for biceps muscle
- **styloid process** can be palpated near thumb
- **ulnar notch**

Ulna and Interosseous Membrane

Copyright © The McGraw-Hill Companies, Inc. Permission required for reproduction or display.



- **Ulna**

- **trochlear notch** articulates with trochlea of humerus
- **olecranon** – bony point at back of elbow
- **coronoid process**
- **radial notch** holds head of radius
- **styloid process**

- **interosseous membrane**

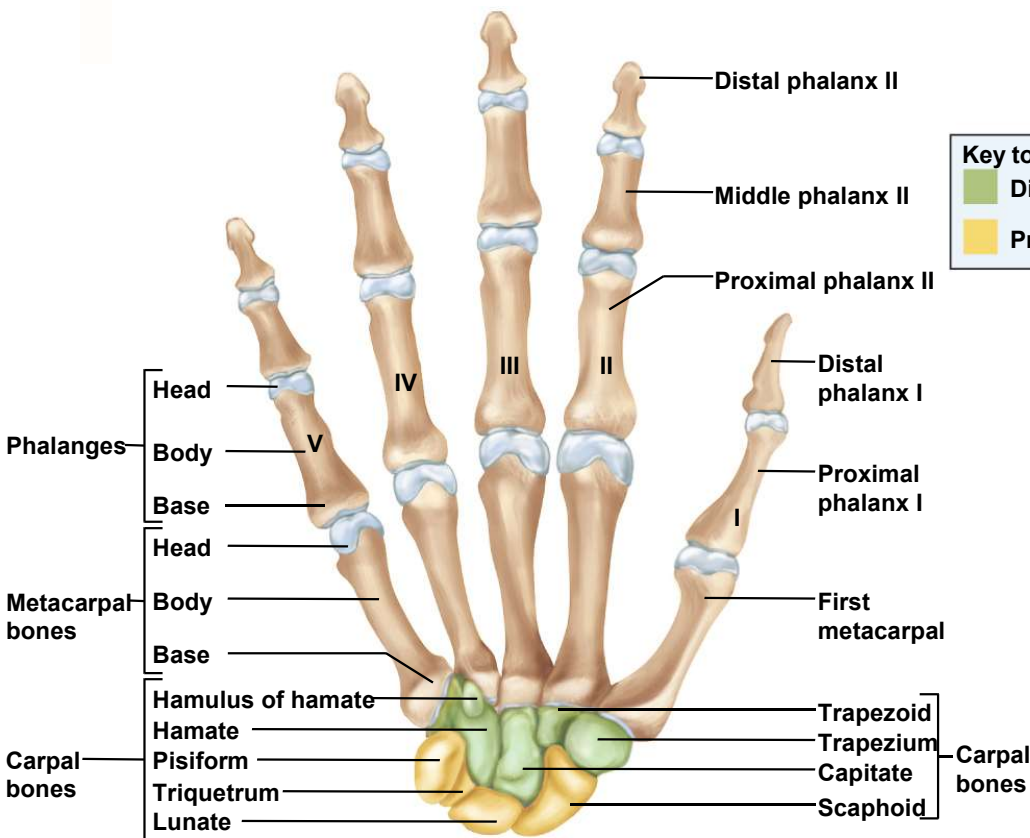
- ligament **attaches radius to ulna** along interosseous margin of each bone
- enables the two elbow joints to share the load

Carpal Bones

- 8 bones form wrist
 - allow movements of flexion, extension, abduction and adduction

2 rows (4 bones each)

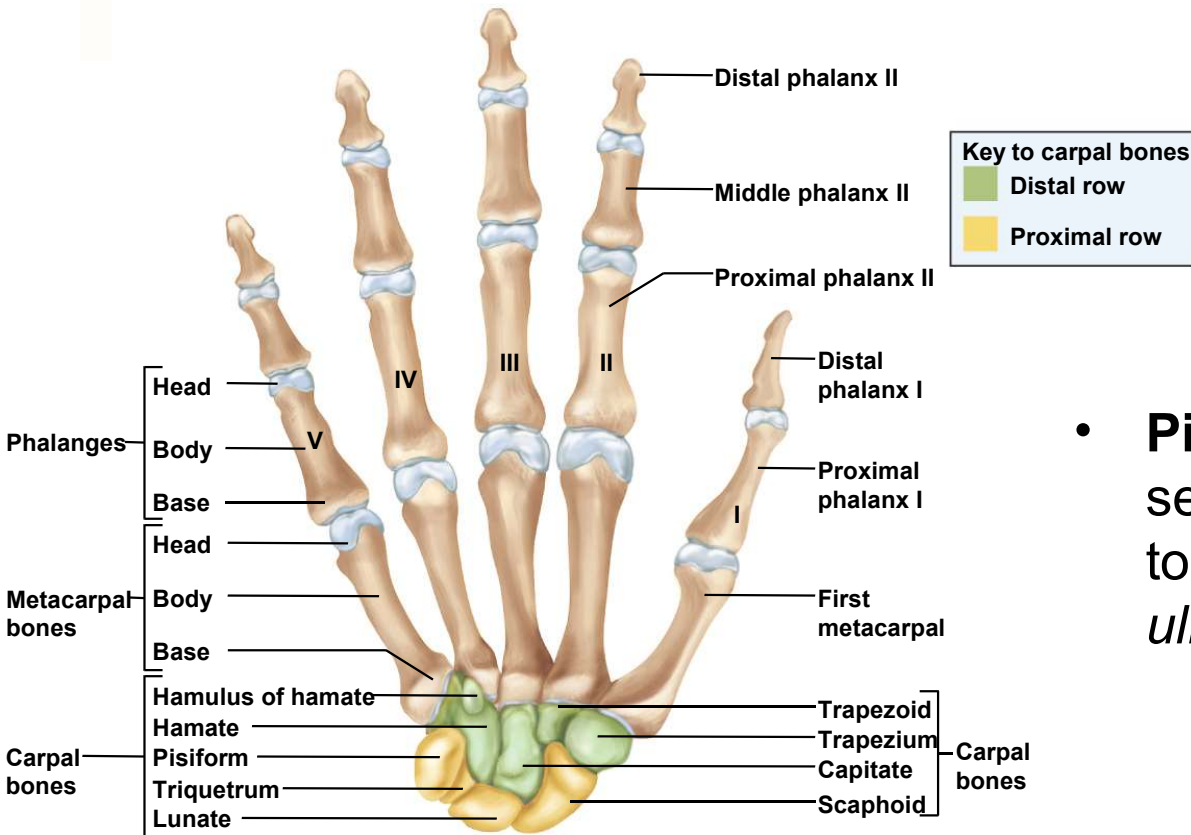
- proximal row // scaphoid, lunate, triquetrum, and pisiform
- distal row /// trapezium, trapezoid, capitate, and hamate



(a) Anterior view

Sesamoid Bone

Copyright © The McGraw-Hill Companies, Inc. Permission required for reproduction or display.

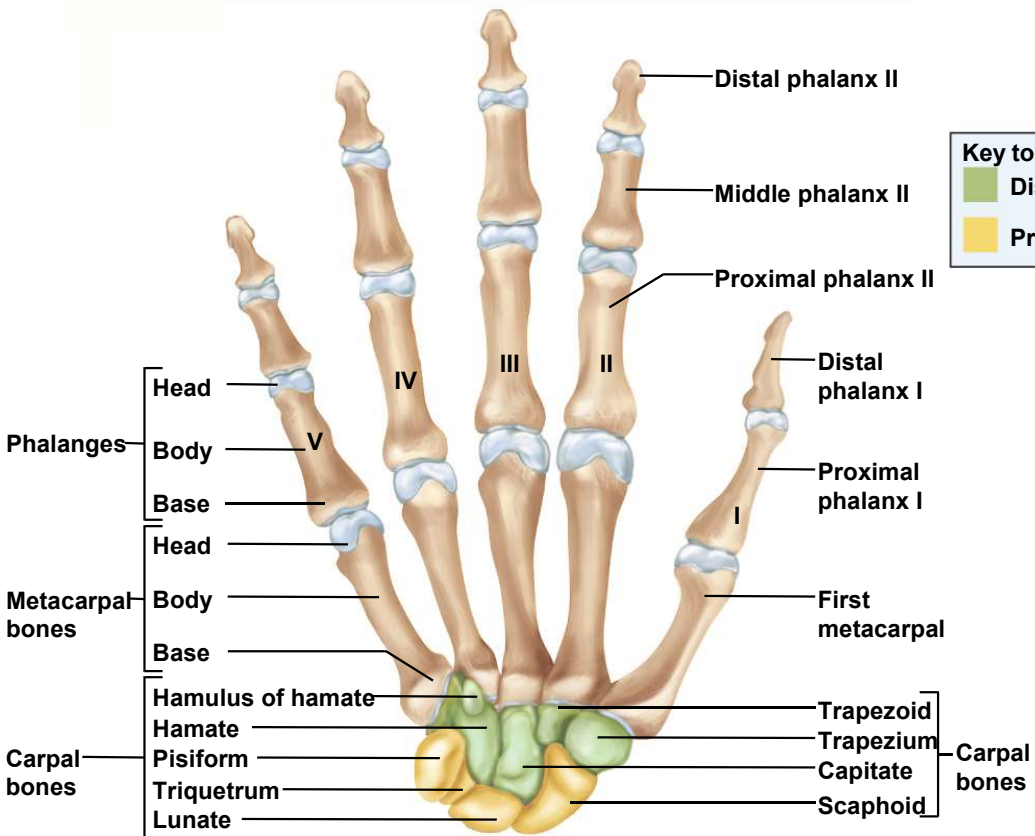


- **Pisiform** // pisiform is a sesamoid developed by age 9 to 12 in tendon of *flexor carpi ulnaris* muscle

(a) Anterior view

Metacarpals and Phalanges

Copyright © The McGraw-Hill Companies, Inc. Permission required for reproduction or display.



(a) Anterior view

- **metacarpals** - bones of the palm

- **metacarpal I** proximal to base of thumb
- **metacarpal V** proximal to base of little finger
- proximal **base**, **body**, and distal **head**

- **phalanges** - bones of the fingers

- thumb or **pollex** has **two phalanges**
 - proximal and distal phalanx
- fingers have **three phalanges**
 - proximal, middle and distal phalanx